Int J Clin Exp Pathol 2014;7(6):3375-3379
www.ijcep.com /ISSN:1936-2625/IJCEP0000435

Case Report

Pseudomembranous trigonitis in a male with Klinefelter syndrome: a case report and evidence of a hormonal etiology

Derrick WQ Lian[1], Fay X Li[2], Caroline CP Ong[2], CH Kuick[1], Kenneth TE Chang[1]

Departments of [1]Pathology and Laboratory Medicine, [2]Paediatric Surgery, KK Women's and Children's Hospital, Singapore

Received April 6, 2014; Accepted May 26, 2014; Epub May 15, 2014; Published June 1, 2014

Abstract: Klinefelter syndrome is a clinical syndrome with a distinct 47, XXY karyotype. Patients are characterized by a tall eunuchoid stature, small testes, hypergonotrophic hypogonadism, gynecomastia, learning difficulties and infertility. These patients have also been found to have raised estrogen levels. We report a 16 year old boy with Klinefelter syndrome presenting to our institution with gross hematuria. Cystoscopy and biopsy revealed the diagnosis of pseudomembranous trigonitis. Immunohistochemical stains showed an increase in estrogen and progesterone receptors in the trigone area but not in the rest of the bladder. In view of the patient's mildly raised estrogen levels and the histological findings, we postulate that estrogen is the driver of the development of pseudomembranous trigonitis. This is the first reported case of pseudomembranous trigonitis seen in association with Klinefelter syndrome, and also the first case of pseudomembranous trigonitis occurring within the male adolescent age group.

Keywords: Klinefelter syndrome, pseudomembranous trigonitis, pediatric

Introduction

Klinefelter syndrome is the most common chromosomal aberration in males and the most common cause of male hypogonadism [1]. The genotype of Klinefelter syndrome is the result of meiotic nondisjunction, resulting in a 47, XXY karyotype. Patients have a tall eunuchoid stature, small testes, hypergonotrophic hypogonadism, gynecomastia, learning difficulties and infertility. In addition, Klinefelter syndrome is associated with raised estrogen levels, and correspondingly, an increased risk of breast cancer, mediastinal germ cell cancer, endocrine complications and osteoporosis [1, 2].

Case report

A 16 year old boy with Klinefelter syndrome, presented to the surgical outpatient clinic with the complaint of recurrent intermittent gross hematuria over the past 1 year. The gross hematuria affected mainly the terminal urine stream and occasionally, fresh blood clots would also be passed. This was associated with a sense of incomplete voiding. These episodes were initially treated with a course of oral antibiotics by a primary care physician with no resolution of symptoms.

Initial investigations consisting of a plain radiograph and an ultrasound scan of the urinary system were unrevealing of a diagnosis. Urinalysis did not demonstrate any casts or crystals, and urine phase contrast could not be carried out due to inadequate red blood cell counts in the sample of urine provided. Urine culture was negative for bacterial growth. The full blood count and coagulation profile were also normal. His serum estradiol level was marginally high at 165 pmol/L (upper limit of normal estradiol for males 161 pmol/L).

During rigid cystoscopy, the bladder mucosa appeared inflamed with prominent superficial vessels. Mucosa over the trigone area had a raised, whitish-grey appearance, suspicious for pseudomembranous trigonitis (**Figure 1**). Biopsies from the trigone and the dome of the bladder were taken for histological confirmation.

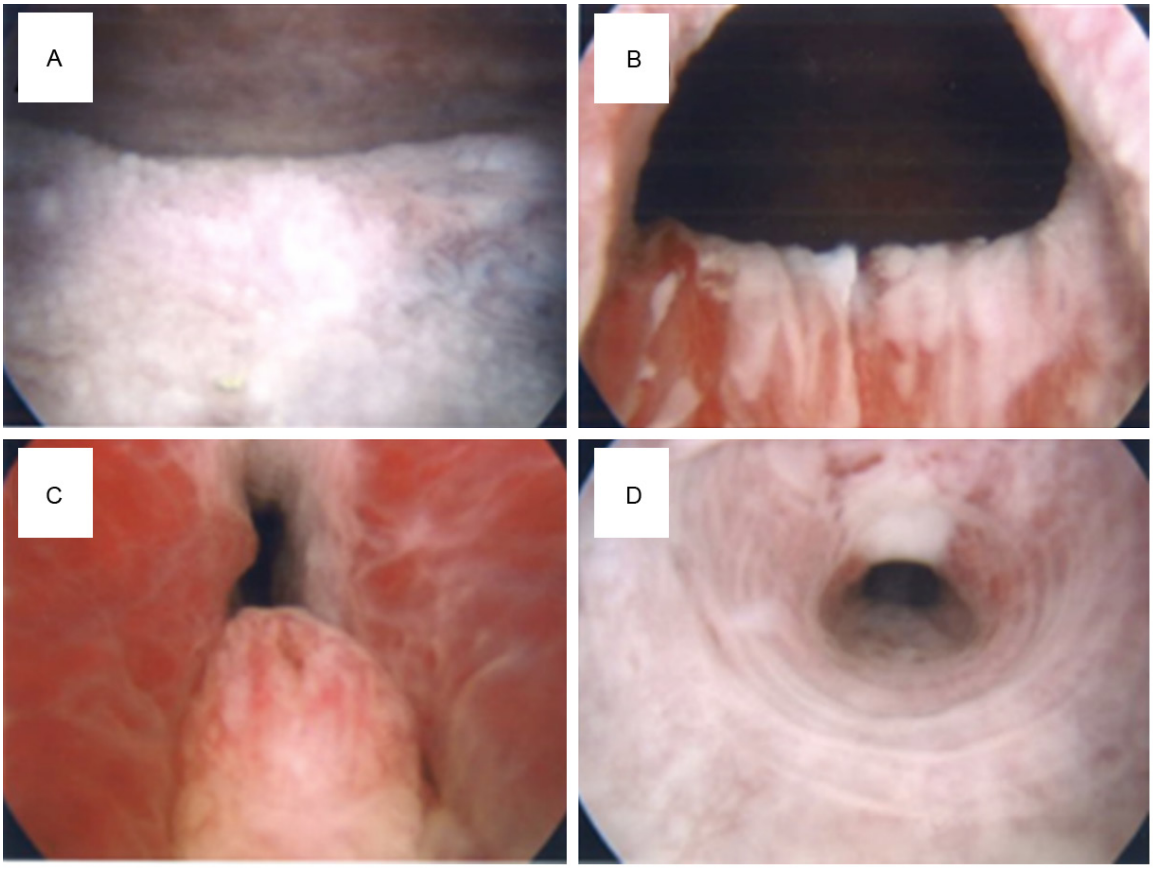

Figure 1. Cystoscopic images of the bladder. The trigone area showed the characteristic gross appearance of pseudomembranous trigonitis, with a raised, whitish grey appearance (A). The bladder neck (B) and verumontanum (C) were inflamed. The urethra (D) was unremarkable.

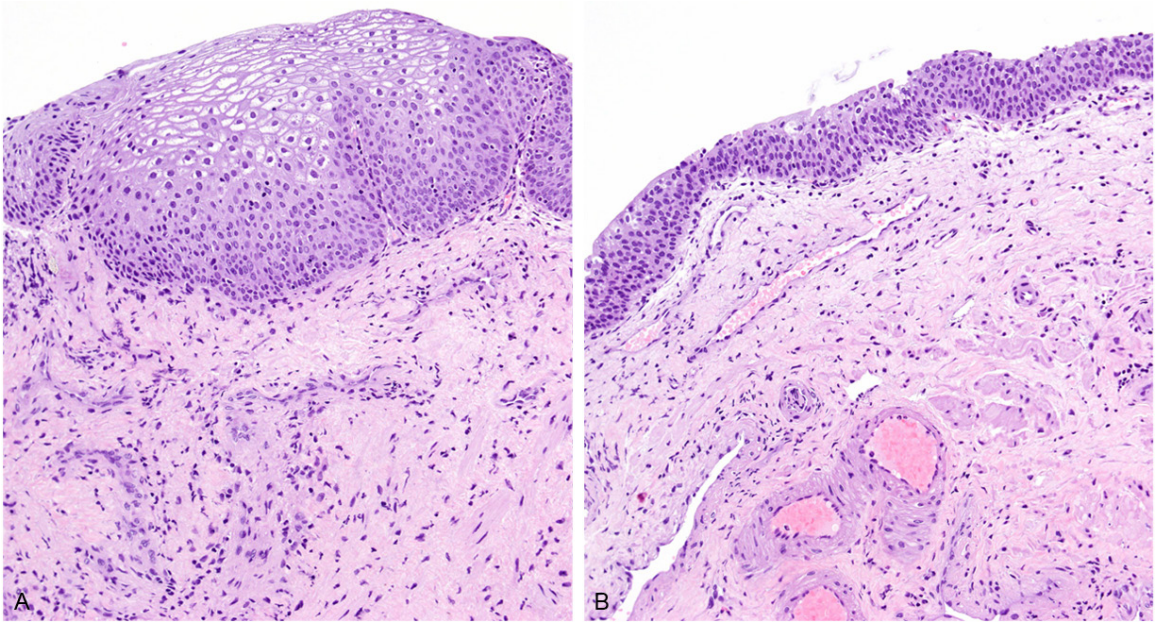

Figure 2. Histological examination of the trigone area. There was focal non-keratinizing squamous metaplasia (A). Elsewhere in the trigone, unremarkable urothelium is seen (B).

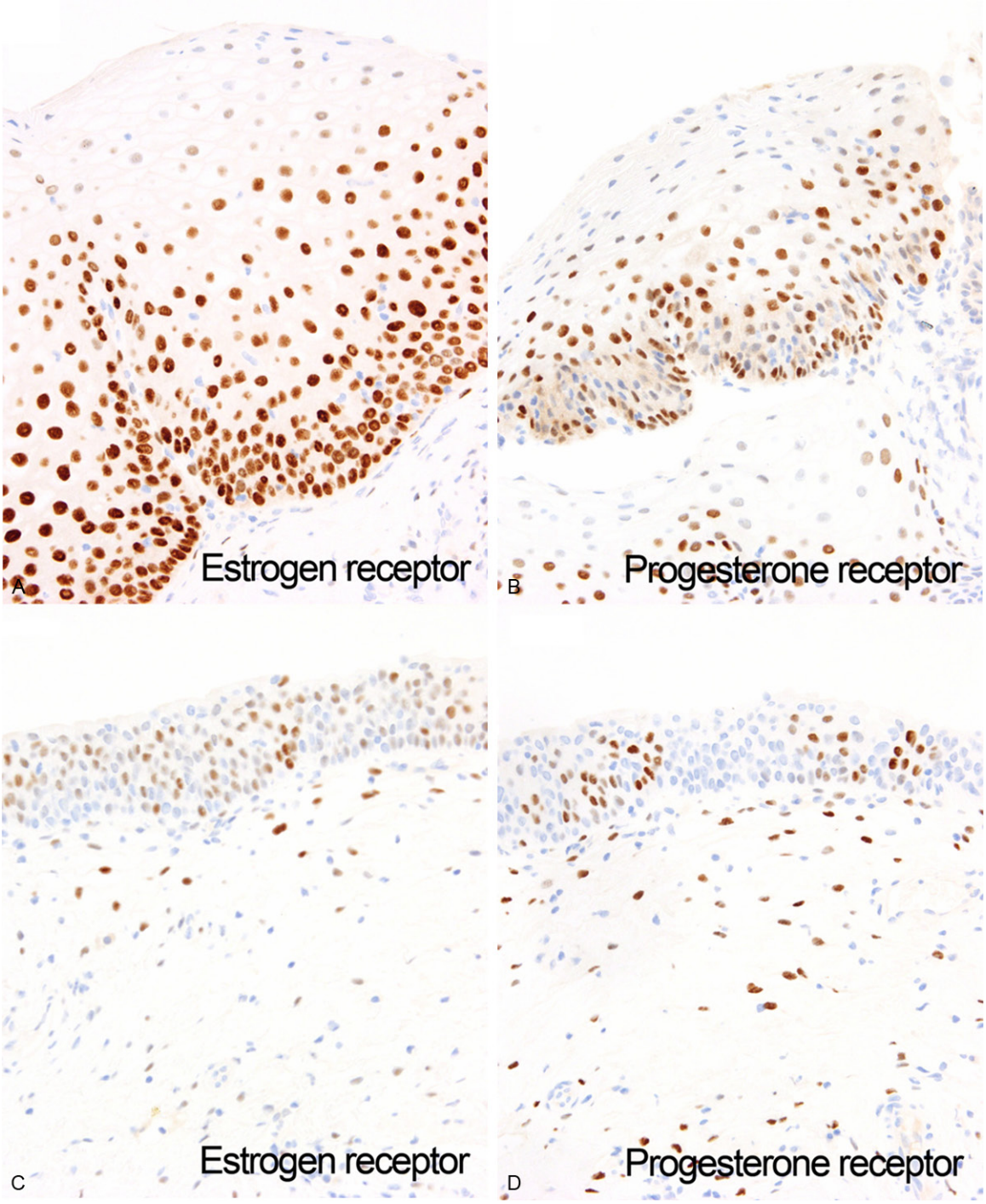

Figure 3. Immunohistochemical study of the trigone area. The region of squamous metaplasis within the trigone was positive for estrogen receptors (A) and progesterone receptors (B). The urothelium in the trigone adjacent to the area of squamous metaplasia also showed patchy positivity for estrogen receptors (C) and progesterone receptors (D).

Histological examination revealed non-keratinizing squamous metaplasia isolated to the trigone region (**Figure 2**). The squamous cells were vacuolated and contained glycogen, giving an appearance similar to that of the vaginal epithelium. The rest of the bladder biopsies were unremarkable. Immunohistochemical studies showed expression of estrogen and progesterone receptors in the epithelial cells of the trigone area, with increased density of expres-

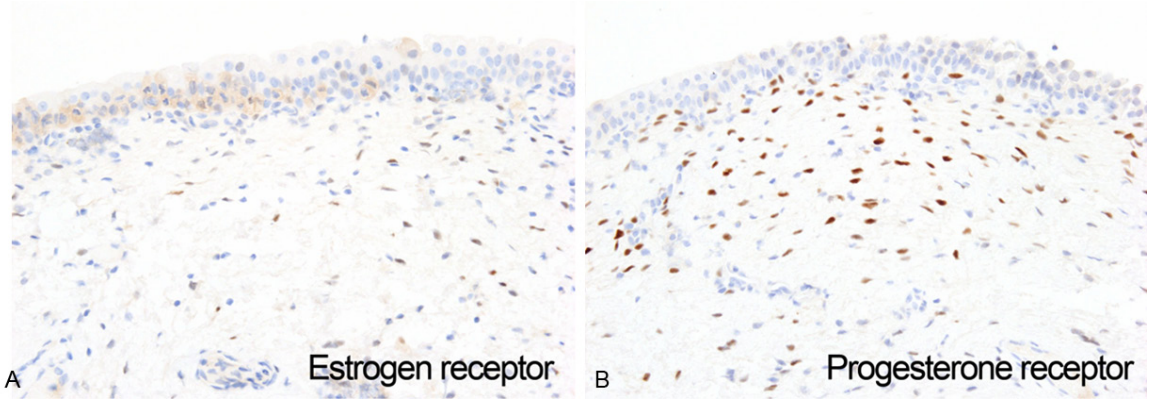

Figure 4. Immunohistochemical study of urothelium away from the trigone area. In contrast, both estrogen receptors (A) and progesterone receptors (B) are negative in the urothelium away from the trigone area. Some stromal cells show positive staining.

sion at the site of non-keratinizing squamous metaplasia (**Figure 3**). In contrast, neither estrogen receptors nor progesterone receptors were expressed in the transitional epithelium of the other bladder sites of the same patient (**Figure 4**).

Discussion

This is the first known case report of an association between Klinefelter syndrome and pseudomembranous trigonitis.

The term pseudomembranous trigonitis is a misnomer as the condition does not have a pseudomembrane histologically, and is a metaplastic rather than inflammatory entity. It is seen almost exclusively in women [3], who present with urgency and frequency of micturition, termed as the 'urethral syndrome'. The urinalysis is normal with a sterile urine culture. On cystoscopy, an abnormal, white to greyish, heaped up mucosa with a serpiginous and hyperemic margin is seen, confined to the trigone region of the bladder. The rest of the bladder is normal. On histology, the epithelium at the trigone area shows a non-keratinizing squamous metaplasia, thicker than normal transitional epithelium [3]. Studies have shown the expression of estrogen receptors in the trigonal transitional epithelium of female bladders, and not at other bladder sites, supporting a hormonal etiology for the development of pseudomembranous trigonitis [4, 5].

The findings of raised estrogen levels in conjunction with increased expression of estrogen receptors in the trigone area of the biopsy, suggest that estrogen is the etiological driver for the development of pseudomembranous cystitis in our patient. One of the rare male patients reported to have pseudomembranous cystitis in the literature had a similar hormonal etiology; he was receiving estrogen for carcinoma of the prostate [3].

With raised estrogen levels, it is entirely plausible for patients with Klinefelter syndrome to be at risk for female-predominated diseases such as pseudomembranous trigonitis. In support of this is the association of Klinefelter syndrome with estrogen-driven cancers such as breast cancer.

Pseudomembranous trigonitis is exceedingly rare in men. To date, only 6 men with pseudomembranous trigonitis have been reported in the literature [3, 6]. Although the presence of estrogen receptors in the trigone area of female bladders has been well documented [4], this is the first report demonstrating a similar immunohistochemical hormonal profile in the male bladder. This suggests an identical embryological development of the trigone region in both genders.

Bacterial cystitis, especially recurrent infections, has been cited to be associated with the development of pseudomembranous trigonitis [6]. However, our patient did not have any documentation of urinary tract infections prior to cystoscopy, and no histological features of chronic inflammation such as cystitis cystica, cystitis glandularis or a chronic inflammatory

infiltrate within the lamina propria was seen. Thus, in our patient, it is likely that urinary tract infection played any major role in the development of pseudomembranous trigonitis.

Cytological examination of the urine in pseudomembranous cystitis is likely to yield squamous cells. This case report raises the possibility of using clean-catch urine cytology to make a presumptive diagnosis of pseudomembranous trigonitis in a patient with Klinefelter syndrome, with known raised serum estrogen levels and presenting with gross hematuria and/or lower urinary tract symptoms. In this select group of patients with otherwise normal radiological and biochemical investigations, and who are at low risk of urologic malignancies, the use of clean-catch urine cytology may potentially avoid the need for an invasive procedure such as cystoscopy.

Disclosure of conflict of interest

None.

Address correspondence to: Dr. Derrick WQ Lian, Department of Pathology and Laboratory Medicine, KK Women's and Children's Hospital, Basement 1 Children's Tower, 100 Bukit Timah Road, Singapore 229899. Tel: (65) 6394 8748; Fax: (65) 6394 1372; E-mail: Derrick.Lian.WQ@kkh.com.sg

References

[1] Wosnitzer MS, Paduch DA. Endocrinological issues and hormonal manipulation in children and men with Klinefelter syndrome. Am J Med Genet C Semin Med Genet 2013; 163C: 16-26.

[2] Groth KA, Skakkebæk A, Høst C, Gravholt CH, Bojesen A. Clinical review: Klinefelter syndrome--a clinical update. J Clin Endocrinol Metab 2013; 98: 20-30.

[3] Henry L, Fox M. Histological findings in pseudomembranous trigonitis. J Clin Pathol 1971; 24: 605-8.

[4] Stephenson TJ, Henry L, Harris SC, Giri DD, Fox M, Underwood JC. Pseudomembranous trigonitis of the bladder: hormonal aetiology. J Clin Pathol 1989; 42: 922-6.

[5] Pacchioni D, Revelli A, Casetta G, Cassoni P, Piana P, Tizzani A, Bussolati G, Massobrio M. Immunohistochemical detection of estrogen and progesterone receptors in the normal urinary bladder and in pseudomembranous trigonitis. J Endocrinol Invest 1992; 15: 719-25.

[6] Ozbey I, Aksoy Y, Polat O, Biçgi O, Demirel A. Squamous metaplasia of the bladder: findings in 14 patients and review of the literature. Int Urol Nephrol 1999; 31: 457-61.