

## Case Report

# Plasmablastic lymphoma of the duodenal and jejunum

Michiaki Koike<sup>1</sup>, Azuchi Masuda<sup>1</sup>, Kunimoto Ichikawa<sup>1</sup>, Ayako Shigemitsu<sup>1</sup>, Norio Komatsu<sup>2</sup>

<sup>1</sup>Department of Hematology, Juntendo University Shizuoka Hospital, 1129 Nagaoka Izunokunishi city, Shizuoka, Japan; <sup>2</sup>Department of Hematology, Juntendo University, 1129 Nagaoka Izunokunishi city, Shizuoka, Japan

Received May 6, 2014; Accepted June 25, 2014; Epub June 15, 2014; Published July 1, 2014

**Abstract:** Plasmablastic lymphoma (PBL) is a rare B-cell neoplasm with an aggressive clinical behavior that predominantly occurs in the oral cavity of human immunodeficiency virus (HIV)-positive patients. HIV-negative PBL has not been extensively reported. A 65-year-old female presented with anemia, who was HIV-negative. Gastrointestinal fiberoscope (GIF), and colon fiberoscope (CF) were performed. However, we could not detect the bleeding sites. We detected the tumor by capsule endoscopy, and obtained the tumor cells from the duodenal and jejunal sites. The neoplastic cells were diffusely positive for CD56, epithelial membrane (EMA), CD4,  $\lambda$ , and EBV-encoded RNA1 (EBER1) and partially positive for CD138 and CD79a. This patient was diagnosed as PBL. The small intestine is a rare extra-oral site of involvement in PBL patients, and only four cases in HIV-negative patients have been reported.

**Keywords:** Plasmablastic lymphoma, small intestine, human immunodeficiency virus-negative, Epstein-Barr virus

## Introduction

Plasmablastic lymphoma (PBL) is an aggressive B-cell neoplasm, which has been characterized by the World Health Organization as a new entity. It was originally described in the oral cavity in the clinical setting of human immunodeficiency virus (HIV) infection, but occurs in other, extra-oral sites in immunocompromised patients who are HIV-negative [1-3]. However, PBL of the small intestine is extremely rare [4, 5]. Here, we present a rare case involving the small intestine in an HIV-negative individual, and review the literature.

## Case report

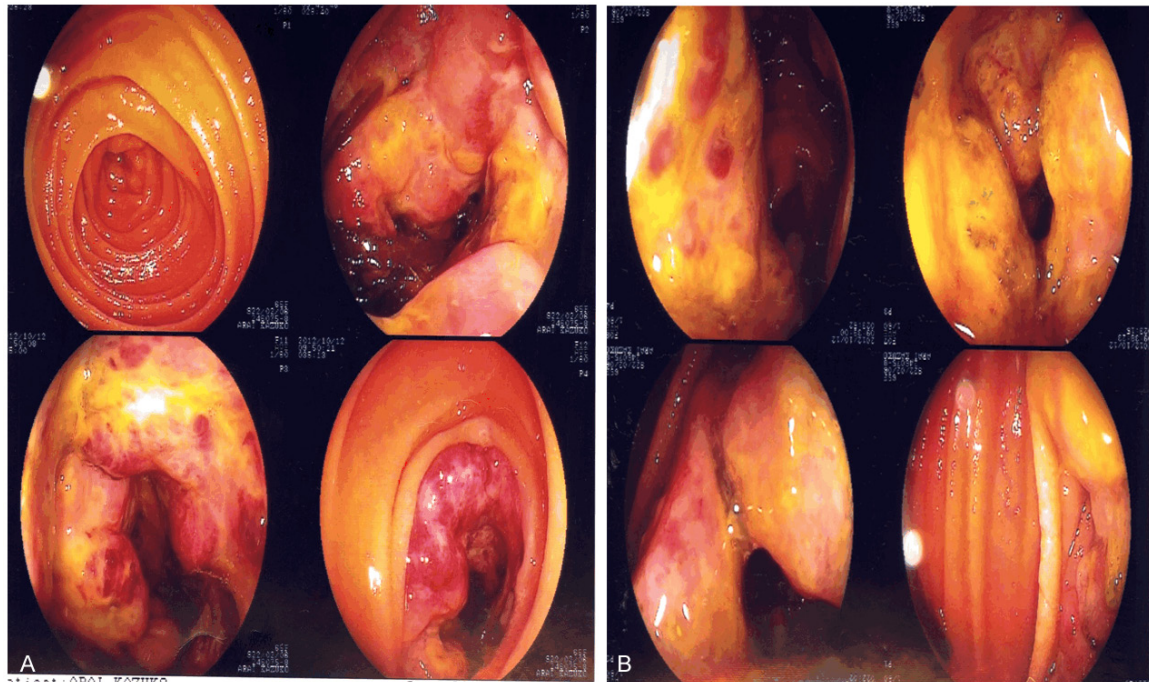
A 65-year-old female presented with anemia. GIF and CF were performed. However, we could not identify abnormal sites. So, we performed capsule endoscopy, and detected abnormal sites in the duodenal and jejunum. We could also detect the tumor in the duodenum and jejunum by enteroscopy (**Figure 1A, 1B**). Abnormal sites were detected in the right upper arm and right subclavical as well as the duodenum and jejunum by pet computed tomography (CT) (**Figure 2**). Blood examination showed:

hemoglobin; 97 g/L; white blood cell count;  $20.0 \times 10^9/L$ ; stab, 9%; segment, 77%; eosinophils, 1%; monocytes, 9%; lymphocytes, 4%; GOT, 92 IU/L; GPT, 26 IU/L; LDH, 1,749 IU/L; IL-2R, 1,964 IU/L. Serological testing was negative for HIV. She had a medical history of diabetes mellitus. The duodenal tumor was resected. Histologically, the whole intestinal wall was diffusely infiltrated by blastic medium~large round cells (**Figure 3A**). On immunohistochemistry, the neoplastic cells were diffusely positive for EMA (**Figure 3B**), EBER1 (**Figure 3C**), CD56 (**Figure 3D**), and  $\lambda$  (**Figure 3E**), and partially positive for CD79a (**Figure 3F**) and CD138 (**Figure 3G**). CD20 (**Figure 3H**) and (data not shown) were negative.

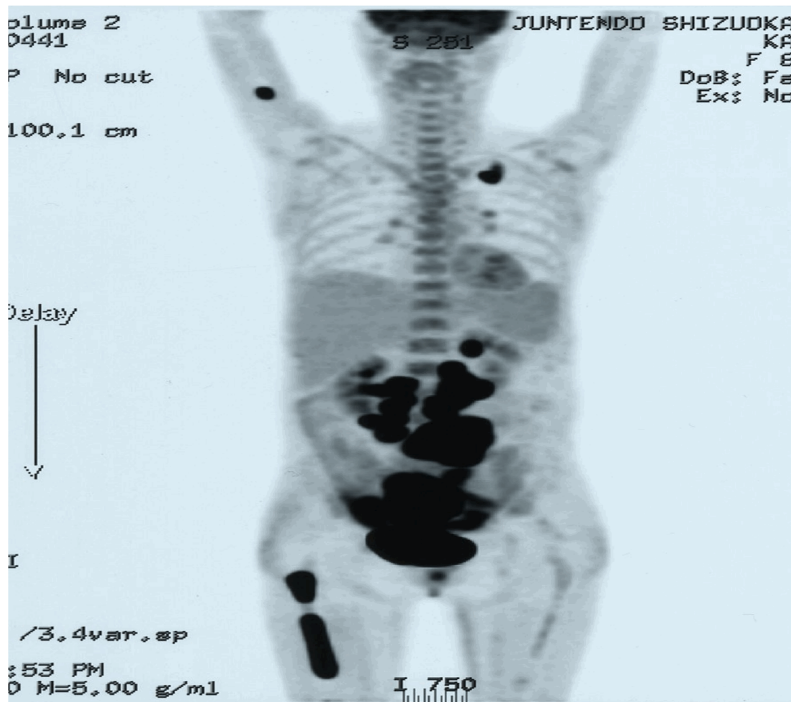On the basis of these morphologic and immunohistochemical characteristics, a pathological diagnosis of PBL was made. After the diagnosis, the patient's condition worsened and she died of multiple organ failure without receiving therapy.

## Discussion

PBL was first described as a specific clinico-pathologic entity by Delecluse et al. [6], being



**Figure 1.** A: The tumor in the duodenal by enteroscopy. B: The tumor in the jejunal by enteroscopy.



**Figure 2.** Abnormal sights were detected at right the upper arm and light sub-clavical and the duodenal and jejuna by pet computed tomography (CT).

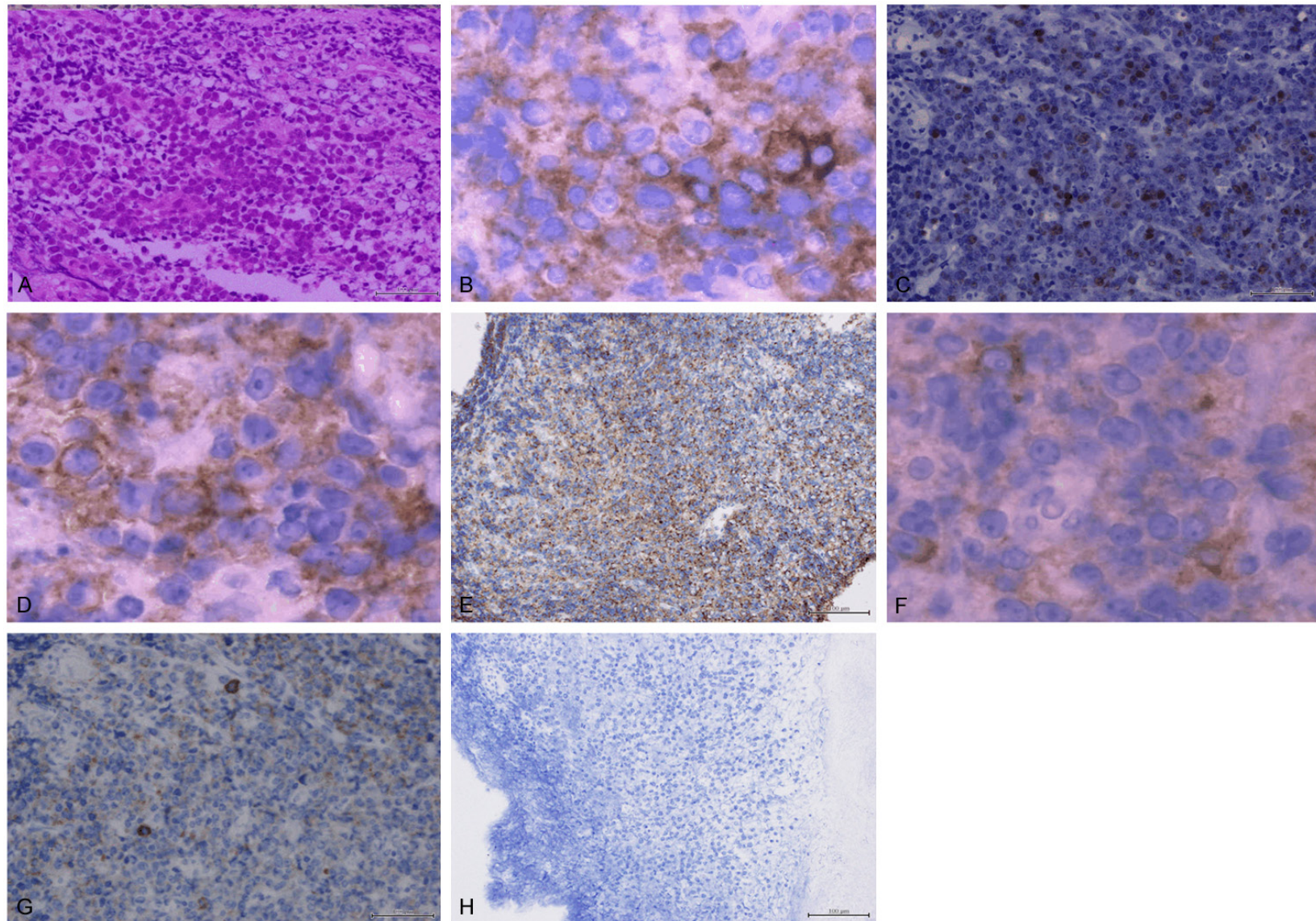
an aggressive B-cell lymphoma occurring in the oral cavity arising with HIV infection. However,

in recent years, several cases of PBL have been reported in patients without HIV infection, and several more reports have described the occurrence of PBL in extra-oral sites, including the skin, subcutaneous tissue, stomach, anal mucosa or perianal area, lung, lymph nodes, and other regions. The small intestine is a rare extra-oral site of involvement in PBL patients, and only four cases in HIV-negative patients have been reported [1, 4, 5] (Table 1).

As PBL is often associated with immunodeficiency, such as HIV infection, EBV plays an important role in the tumorigenesis of HIV-associated PBL. HIV infection creates a favorable environment for chronic EBV infection, with a subsequent latency that predisposes EBV-



# PBL of small intestine



**Figure 3.** Immunophenotype of a duodenal biopsy from a 65-year-old female with PBL. A: Hematoxylin-eosine staining  $\times 400$ . B: Epithelial membrane antigen (EMA) staining highlighted a subset of atypical lymphoid cells ( $\times 600$ ). C: In situ hybridization study (ISH) probing with Epstein-Barr virus encoded RNA-1 (EBER1) demonstrated a significant increase of EBV infected lymphoid cells (ISH,  $\times 400$ ). D: CD56 staining highlighted an atypical lymphoid cells. E: Immunohistochemical stains (IHC) with lambda chains and kappa light chains revealed lambda light chains restriction in plasmablastic lymphoma cells (IHC,  $\times 200$ ). F: CD79a staining was partially positive ( $\times 600$ ). G: Plasma cell marker CD138 was weakly positive ( $\times 400$ ). H: CD20 staining was negative ( $\times 200$ ).

**Table 1.** Clinical findings of PBL of the small intestine

Case	sex/Age (years)	initial location	CD4	CD20	CD79a	CD56	CD138	ENA	EBER-1	HHV-8	κ	λ	treatment	OS (months)	Outcome	Reference
1	F/75	cecum	-	-	-	-	+	NA	-	NA	+	-	unknown	unknown	unknown	[1]
2	M/55	small intestine	NA	-	+	-	+	NA	-	NA	+	-	CHOP	1.5	dead	[4]
3	M60	jejunal	NA	-	+	-	-	+	-	NA	-	+	CHOP	24	alive	[5]
4	F/65	duodenal jejunal <sup>1</sup>	-	-	+	+	+	+	+	-	-	+	none	3.0	dead	present

<sup>1</sup>Abbreviations: CHOP, cyclophosphamide, doxorubicine, vincristine, and prednisone; F, female; M, male; NA, not available; OS, overall survival.

transformed B-cells to become malignant [7]. Indeed, in 107 cases of HIV-associated PBL, 79 cases (74%) were positive for EBV [8]. However, EBV-negative cases have been reported, and a recent investigation in Korea revealed that EBV infection was detected in only 17% of HIV-negative PBL cases [7]. In our case, EBV was detected by immunohistochemistry.

Cases of HIV-negative PBL have been mostly described after solid organ transplantation, in association with steroid therapy for autoimmune disease and some other types of immunosuppression [9, 10]. The main differential diagnoses of PBL include diffuse large B-cell lymphoma (DLBCL), plasmacytoma/myeloma, poorly differentiated carcinoma, and malignant melanoma. PBL expresses immunoreactivity for plasma cell markers (CD38, CD138) and is weakly positive or negative for CD45, CD20, and CD79a with positive rates of 50-85% [10]. The expression of CD56 in DLBCL is rare, and has been associated with a germinal center-like phenotype [11, 12]. However, the cellular origin of PBL almost invariably shows a post-germinal center-like phenotype, making the significance of this finding unclear. In a previous study, 67% of PBL cases in HIV-positive patients showed the expression of CD56; however, only 6% of PBL cases in HIV-negative patients showed the expression of CD56 [13, 14]. The present patient had CD56-positive markers. There are no clear explanations for the differences in CD56 expressions in HIV-positive and -negative patients with PBL. Poorly differentiated carcinoma can be differentiated from PBL based on immunoreactivity for cytokeratins and EMA, but this case was EMA-positive. Also, some HIV-negative cases were reportedly EMA-positive. The general prognosis of PBL patients is very poor with a rapidly progressive clinical course, and half of the original 16 patients in one report died within one year [6]. HIV-positive and -negative patients with PBL exhibit different clinicopathological characteristics, including a

more favorable response to chemotherapy and longer survival in HIV-positive patients. HIV-negative patients had a median overall survival of 9 months vs. 14 months in HIV-positive patients [13]. Furthermore, extra-oral PBL is more commonly disseminated (57% of patients are at stage IV at diagnosis). Meanwhile, the loss of CD20 associated with plasmacytic differentiation and very high ki-67 index (> 90%) indicated a poor prognosis [2]. Liu reported [2] that all patients were treated with CHOP or hyper-CVAD. Responses were observed in 8 cases (7 complete, 1 partial). Four patients underwent consolidation with autologous hematopoietic stem cell transplantation (HSCT) in their first complete remission (CR1). At a median follow-up of 23.9 months, 7 patients were alive and 5 were disease-free. Aggressive induction chemotherapy and consolidation with autologous HSCT in CR1 might be considered for patients with HIV-negative PBL. In our case, the primary PBL of the small intestine had infiltrated multiple organs accordingly, clinical stage IV was assigned.

We described a rare case of extra-oral PBL involving the small intestine in an HIV-negative patient. PBL does not express the more common lymphoid markers, and it is easy to mistake it for a poorly differentiated carcinoma. The timing of the diagnosis of this case was very late, and so we could not start therapy.

Therefore, recognition of this entity by pathologists and clinicians is important to establish the correct diagnosis and treatment of patients affected at small intestinal site.

#### Disclosure of conflict of interest

None.

**Address correspondence to:** Dr. Michiaki Koike, Department of Haematology, Juntendo University



Shizoka Hospital, 1129 Nagaoka Izunokunishi city, Shizuoka, Japan. Tel: 81-55-948-3111; Fax: 81-55-948-5088; E-mail: yu-koike@lily.ocn.ne.jp

## References

- [1] Hatanaka K, Nakamura N, Kishimoto K, Sugino K, Uekusa T. Plasmablastic lymphoma of the cecum: report of a case with cytologic findings. *Diagn Cytopathol* 2011; 39: 297-300.
- [2] Liu JJ, Zhang L, Ayala E, Field T, Ochoa-Bayona JL, Perez L, Bello CM, Chervénick PA, Bruno S, Cultrera JL, Baz RC, Kharfan-Dibaje MA, Raychaudhuri J, Sotomayor EM, Sokol L. Human immunodeficiency virus (HIV)-negative Plasmablastic lymphoma: a single institutional experience and literature review. *Lek Res* 2011; 35: 1571-1577.
- [3] Tavora F, Gonzalez-cuyar LF, Sun CC, Burke A, Zhao XF. Extra-oral plasmablastic lymphoma: Report of a case and review of literature. *Hum Pathol* 2006; 37: 1233-1236.
- [4] Wang HW, Yang W, Sun JZ, Lu JY, Li M, Sun L. Plasmablastic lymphoma of the small intestine: Case report and literature review. *World J Gastroenterol* 2012; 18: 6677-6681.
- [5] Cha JM, Lee JI, Joo KR, Jung SW, Shin HP, Lee JJ, Kim GY. A case report with plasmablastic lymphoma of the jejunum. *J Kreaan Med Sci* 2010; 25: 496-500.
- [6] Delecluse HJ, Anagnostopoulos I, Dallenbach F, Hummel M, Marafioti T, Schneider U, Huhn D, Schmidt-Westhausen A, Reichart PA, Gross U, Stein H. Plasmablastic lymphoma of the oral cavity: A new entity asociated with the human immunodeficiency virus infectin. *Blood* 1997; 89: 1413-1420.
- [7] Kim JE, Kim YA, Kim WY, et al. Human immune-deficiency virus-negative plasmablastic lymphoma in Korea. *Leuk Lymphoma* 2009; 50: 582-587.
- [8] Castillo J, pantanowitz L, Dzube BJ. HIV-associated pasmablastic lymphoma: Lessons learned from 112 published cases. *Am J Hematol* 2008; 83: 804-809.
- [9] Teruya-Feldstein J, Chiao E, Filippa DA, Lin O, Comenzo R, Coleman M, Portlock C, Noy A. CD20-ngative large-cell lymphoma with plasmablastic features: A clinically heterogenous spectrum in both HIV-positive and -negative patients. *Ann Oncol* 2004; 15: 1673-1679.
- [10] Stein H, Harris NL, Campo E. Plasmablastic Lymphoma. In: Swerdlow SH, Campo E, Harris NL, et al, editors. *WHO classification of tumors. Pathology and genetics of tumours of hemato-poietic and lymphoid tissues*. 4th edition. Lyon: IARC Press; 2008. pp. 256-257.
- [11] Isobe Y, Sugimoto K, Takeuchi K, Ando J, Masuda A, Mori T, Oshimi K. Neural cell Ashesion molecule (CD56)-positive B-cell Ymphoma. *Eur J Haematol* 2007; 79: 166-169.
- [12] Weinberger J, Gorczyca W, Kinney MC. CD56-psitive large B-cell lymphoma. *Eur J Haematol* 2007; 79: 166-169.
- [13] Castillo JJ, Winer ES, Stachurski D, Perez K, Jabbour M, Colvin G, Butera JN. Clinical and pathological differences between human immuno-deficiency virus-positive and human immune-deficiency virus-negative patients with plasmablastic lymphoma. *Leuk lymphoma* 2010; 51: 2047-2053.
- [14] Vega F, Chang CC, Medeiros LJ, Udden MM, Cho-Vega JH, Lau CC, Finch CJ, Vilchez RA, McGregor D, Jorgensen JL. Plasmablastic Lymphomas and and plasmablastic plasma cell myelomas have nearly identical immunophenotypic profiles. *Mod Pathol* 2005; 18: 806-815.