

## Case Report

# Inflammatory myofibroblastic tumor of the larynx: report of a case and review of the literature

Qian Yan, Xue-Ling Hu

Department of Emergency, Affiliated Hospital of Hangzhou Normal University, Hangzhou, 310015, PR China

Received June 2, 2015; Accepted September 14, 2015; Epub October 1, 2015; Published October 15, 2015

**Abstract:** Inflammatory myofibroblastic tumor (IMT) is a rare neoplasm, most commonly seen in children and adolescents. It can occur in nearly every part of the body. Inflammatory myofibroblastic tumor (IMT) is a rare neoplasm mostly seen in the lungs, but also in extrapulmonary sites. But it may rarely be seen in the vical cord. We report a case of a 73-year-old men presented with hoarseness and cough. Laryngoscopy reveals a large non-ulcerated, red subepithelial mass arising from the right vical cord. Magnetic resonance imaging (MRI) scan revealed a mass in the right vical cord, and magnetic resonance imaging (MRI) enhanced scan showed the mass of the right vical cord inhomogeneous enhancement. The patient underwent right cordectomy with KTP laser, and further assessment of the tissue demonstrated a pathologic diagnosis of IMT.

**Keywords:** Inflammatory myofibroblastic tumor, larynx, cordectomy, laser

### Introduction

Inflammatory myofibroblastic tumor (IMT) is a rare neoplasm of mesenchymal origin, most commonly seen in the lungs of children and adolescents and it occurs in nearly every part of the body. Inflammatory myofibroblastic tumor could also be seen in the genitourinary system, mostly in the bladder, and its occurrence in the kidney [1, 2]. But it may rarely be seen in the vical cord. Herein, we report a case of a 73-year-old men presented with horsess and cough.

### Case report

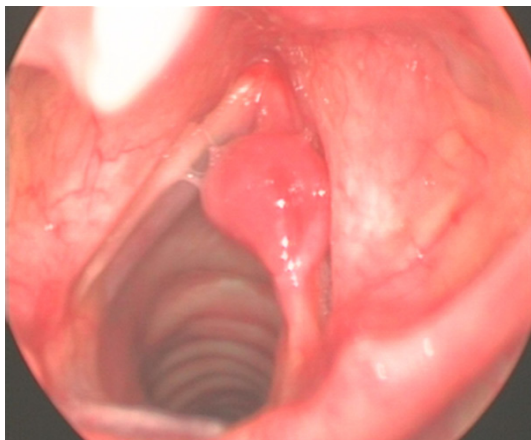
A 73-year-old man was admitted to our hospital with complaints of a hoarse voice of 2-months duration with chronic cough. He was a non-smoker. Laryngoscopic examination revealed a large non-ulcerated, red subepithelial mass arising from the right vical cord (**Figure 1**). The epiglottis and the epiglottic vallecula were normal, and also the left vocal cord was normal. Magnetic resonance imaging (MRI) was then performed subsequently showed an non-homogeneous soft tissue mass arising from the right vocal cord (**Figure 2**), and magnetic resonance imaging (MRI) enhanced scan showed the mass

of the right vical cord inhomogeneous enhancement (**Figure 3**). There was no evidence of enlarged cervical lymph node. Left cordectomy with KTP laser was done under general anesthesia, the post-operative recovery was uneventful, and the patient was discharged home the next day after operation.

Histologic examination of the specimen showed proliferation of spindle cells with elongated cytoplasmic processes in a loose edematous and myxoid background (**Figure 4**). Nucleoli revealed occasional atypia and some contained prominent nucleoli. Diffuse lymphoplasmacytic inflammation with occasional eosinophis and neutrophils infiltration was found. Immunohistochemical staining demonstrated the spindle cells diffusely positive for vimentin, and focally positive for both actin and anaplastic lymphoma kinase (ALK). Staining for epithelial membrane antigen, cytokeratin 7, CD34, Bcl2, and desmin was negative. A final diagnosis of IMT was made.

The patient was doing well during the follow up period with no evidence of disease recurrence for 1 year after the surgery.

## Inflammatory myofibroblastic tumor of the larynx

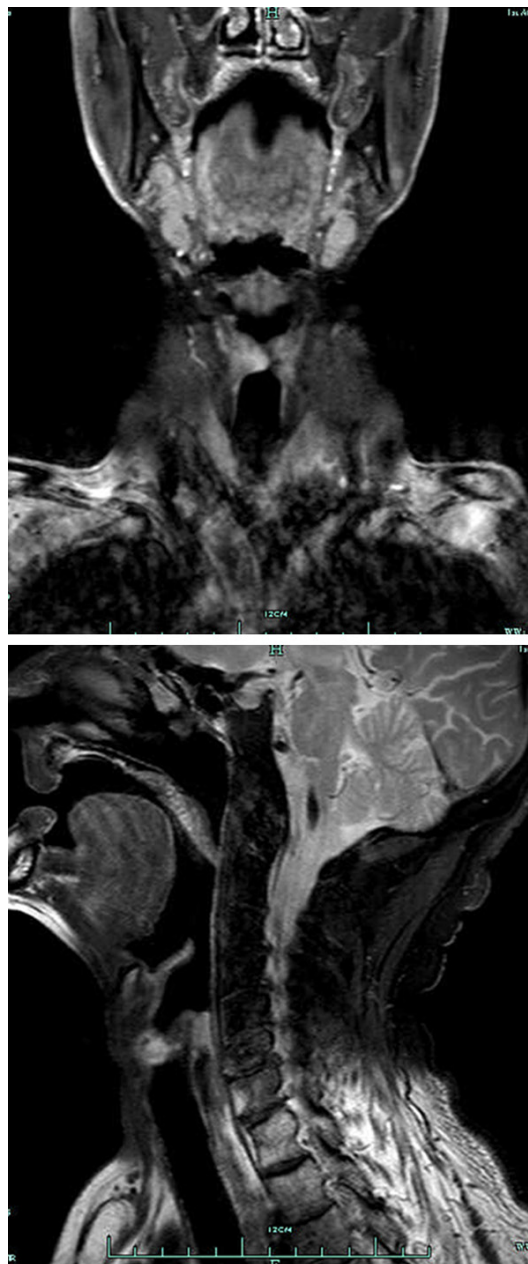


**Figure 1.** Laryngoscopy image showing mass of the right vical cord.

### Discussion

Inflammatory myofibroblastic tumor, or inflammatory pseudotumor (as named before), histologically, IMTs are defined by the World Health Organization as lesions composed of a myofibroblastic spindle cell population accompanied by an inflammatory infiltrate of plasma cells, lymphocytes, and eosinophils. IMTs can arise in various anatomic locations but occur primarily in the lung, orbit, retroperitoneum, or abdominopelvic region [3]. Vical cord IMT is a rare pathologic diagnosis because of its rare occurrence.

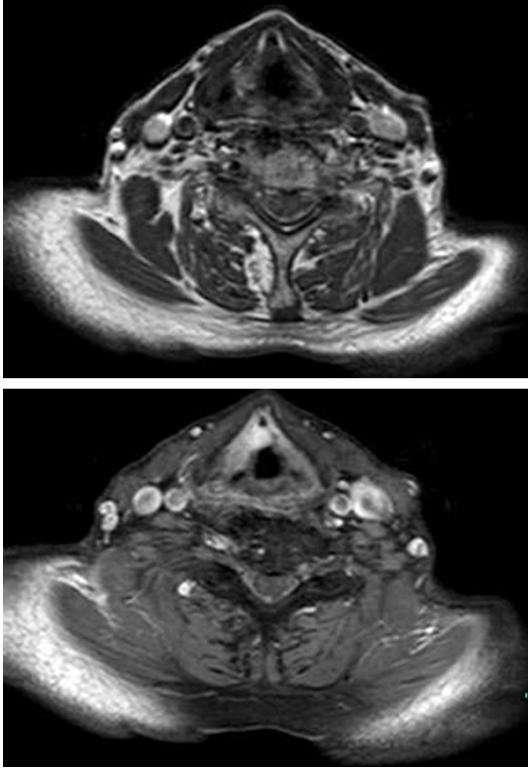
The etiopathogenesis of IMT remains unresolved. These lesions were traditionally considered a benign reactive process, possibly as an exaggerated immune response to Epstein-Barr virus, human herpes virus-8, trauma, surgery or a foreign body [4, 5]. At least a fraction of IMTs appear to be neoplastic in nature, based on reports of recurrence, regional metastases, extensive local invasion leading to death in one case, and malignant transformation. This concept has been further supported by evidence of aberrations in the anaplastic lymphoma tyrosine kinase (ALK) receptor locus on chromosome 2p23, reported in up to 50% of IMTs [6, 7]. Anaplastic lymphoma kinase (ALK), which is used in diagnosis of anaplastic large cell lymphoma, is expressed in IMT cells caused by chromosomal translocation of the ALK gene (chromosome 2p23) with a partner gene (nucleophosmin or others), which is useful in confirming the diagnosis.



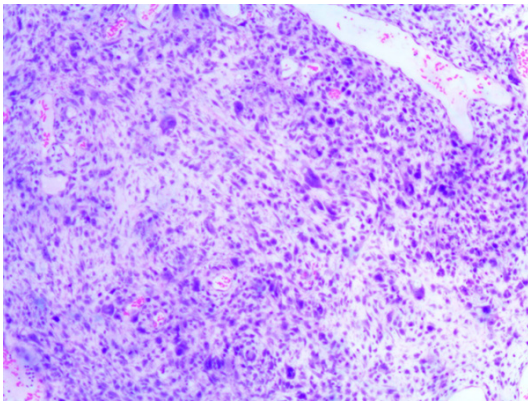
**Figure 2.** Magnetic resonance imaging (MRI) scan showed an non-homogeneous soft tissue mass arising from the right vocal cord.

Despite recent improvements in imaging technology, IMT has no characteristic findings on CT or MR imaging, in our case, magnetic resonance imaging (MRI) enhanced scan showed the mass of the right vical cord inhomogeneous enhancement. Preoperative diagnosis of IMT remains a dilemma, and final diagnosis is based on histopathologic evaluation of the involved tissue. In the present case, a right cor-

## Inflammatory myofibroblastic tumor of the larynx



**Figure 3.** Magnetic resonance imaging (MRI) enhanced scan showed the mass of the right vocal cord inhomogeneous enhancement.



**Figure 4.** Photomicrograph of the tumor specimen showing spindle cells with infiltration of lymphocytes, plasma cells, and foamy histiocytes.

dectomy with KTP laser was carried out and histopathological diagnosis suggested IMT and expression of vimentin, smooth muscle actin, and ALK confirmed IMT as the final diagnosis. The principal therapy in patients with IMT is surgical resection, and in some situations, corticosteroids and nonsteroidal anti-inflammatory

drugs may be useful [8-11]. As nearly all the reported cases of IMT had long disease free survival, approximately 25% of patients with extrapulmonary IMT have recurrence, and distant metastasis (rate: <5%) has been reported. In our case, right cordectomy with KTP laser was done, and after one year of follow-up, there was no evidence of symptoms or recurrent disease.

In conclusion, although IMT is a rare tumor involving the vocal cord, complete surgical resection with KTP laser is a useful procedure.

### Disclosure of conflict of interest

None.

**Address correspondence to:** Dr. Xue-Ling Hu, Department of Emergency, Affiliated Hospital of Hangzhou Normal University, Hangzhou 310015, PR China. Tel: +86-571-88303569; Fax: +86-571-8830-3569; E-mail: wangent24@163.com

### References

- [1] Palaskar S, Koshti S, Maralingannavar M, Bartake A. Inflammatory myofibroblastic tumor. *Contemp Clin Dent* 2011; 2: 274-277.
- [2] Goldblum JR, Folpe AL, Weiss SW. 6th edition. *Inflammatory myofibroblastic tumor*. Enzinger and Weiss's soft tissue tumors. Philadelphia, PA: Saunders; 2013. pp. 304-310.
- [3] Sanjivini VJ, John DR, Angerika YK, William DW, Chen L, Lizette VD. An Unusual Case of Systemic Inflammatory Myofibroblastic Tumor with Successful Treatment with ALK-Inhibitor. *Case Rep Pathol* 2014; 2014: 470340.
- [4] Parul S, Aditi AB, Lakshmi R, Venkadasalapaty N, Raghu R. Inflammatory Myofibroblastic Tumor: A Rapidly Growing Soft Tissue Mass in the Posterior Mandible. *Head Neck Pathol* 2013; 7: 393-397.
- [5] Eley KA, Watt-Smith SR. Intraoral presentation of inflammatory myofibroblastic tumor (pseudotumor) at the site of dental extraction: report of a case and review of the literature. *J Oral Maxillofac Surg* 2010; 68: 2016-2020.
- [6] Tothova Z, Wagner AJ. Anaplastic lymphoma kinase-directed therapy in inflammatory myofibroblastic tumors. *Curr Opin Oncol* 2012; 24: 409-413.
- [7] Lizette VD. An Unusual Case of Systemic Inflammatory Myofibroblastic Tumor with Successful Treatment with ALK-Inhibitor. *Case Rep Pathol* 2014; 2014: 470340.

## Inflammatory myofibroblastic tumor of the larynx

- [8] Eley KA, Watt-Smith SR. Intraoral presentation of inflammatory myofibroblastic tumor (pseudotumor) at the site of dental extraction: report of a case and review of the literature. *J Oral Maxillofac Surg* 2010; 68: 2016-2020.
- [9] Ylenia P, Daniele D, Marco A, Emanuele R, Miriam P, Federico V. Primary inflammatory myofibroblastic tumor of the trachea. *Respirology Case Reports* 2014; 2: 147-149.
- [10] Kieu MQ, Thottam PJ, DaCosta V, Gonzalez-Krellwitz L, Poulik JM, Madgy DN. Treatment of Inflammatory Myofibroblastic Tumor of the Subglottis With KTP Laser: A Case Report. *J Voice* 2014; 28: 841.e1-4.
- [11] Tothova Z, Wagner AJ. Anaplastic lymphoma kinase-directed therapy in inflammatory myofibroblastic tumors. *Curr Opin Oncol* 2012; 24: 409-413.