

Original Article

Expression of somatostatin receptors (SSTR1-SSTR5) in meningiomas and its clinicopathological significance

Camila Batista de Oliveira Silva^{1,2}, Bárbara Roberta Ongaratti^{1,2}, Geraldine Trott^{1,2}, Taiana Haag^{1,2}, Nelson Pires Ferreira², Carolina Garcia Soares Leães^{1,2}, Julia Fernanda Semmelmann Pereira-Lima^{1,2}, Miriam da Costa Oliveira^{1,2}

¹Department of Laboratory of Pathology, ²Neuroendocrinology Center, Hospital Complex Santa Casa de Porto Alegre, University of Health Sciences of Porto Alegre, Rio Grande do Sul, Brazil

Received August 6, 2015; Accepted September 25, 2015; Epub October 1, 2015; Published October 15, 2015

Abstract: Meningiomas are benign brain tumors that are usually to recur. Studies have shown *in vitro* and *in vivo* that meningiomas, regardless of histology and classification, express somatostatin receptors (SSTRs). We investigated the immunohistochemical expression of five SSTR subtypes (SSTR1-SSTR5) in tumor tissue sections from 60 patients with diagnosis of meningioma who underwent surgical resection and relating it to patient age and sex, tumor histology, location, regrowth/recurrence and follow-up. Mean (SD) patients age was 53.18 (12.6) years and 44 were women (73.3%). According to the WHO histological grading criteria, 47 (78.3%) meningiomas were grade I, 11 (18.3%) were grade II, and 2 (3.3%) were grade III. All five SSTRs were expressed in our sample, at frequencies ranging from 61.6 to 100%, with a predominance of SSTR2. SSTR5 was more frequently expressed in tumors benign than in tumors malignant ($P < 0.013$). Recurrence-free survival rate at 2 years was 75.2%. There were no significant differences in SSTR expression regarding age, sex, tumor location and regrowth/recurrence. SSTR expression was detected at a significant frequency in this series. SSTR5 showed higher expression in tumors benign supporting the use of these SSTRs in diagnostic of meningiomas and their influence in process of tumorigenesis in meningiomas recurrence.

Keywords: Immunohistochemistry, brain tumor, meningioma, somatostatin, receptors of somatostatin, recurrence

Introduction

Meningiomas are slow-growing, usually benign brain tumors that are likely to recur [1]. According to a study conducted from 2007 to 2011 by the Central Brain Tumor Registry of the United States (CBTRUS), approximately 7.61 per 100,000 population develop this type of tumor, accounting for 36.1% of all intracranial tumors. The prevalence rate for meningiomas is 50.4 per 100,000, with a marked increase in incidence rates after age 65, being more common in women (ratio of 2:1) [2].

Tumor growth is closely related to hormonal factors [3]. It is known that meningiomas express estrogen and progesterone receptors [4], androgens [5], and non-steroid hormones, including somatostatin [6]. Somatostatin performs its physiological functions by binding to specific receptors (SSTR1-SSTR5), which have

been described in most central nervous system and neuroendocrine tumors [7-10].

Standard treatment (surgical resection and radiotherapy) is recommended for patients with meningiomas, which, in most cases, is effective in inhibiting tumor growth. However, treatment options for tumor recurrence after surgery or tumors refractory to radiotherapy are limited, posing a challenge for existing therapeutic approaches [11].

This study aimed to increase knowledge of protein expression by investigating the immunohistochemical expression of five somatostatin receptor (SSTR) subtypes in meningiomas and relating it to patient age and sex, tumor histology, location, regrowth/recurrence and follow-up. Therefore, the frequent overexpression of receptors may explain the high tracer uptake often observed in meningioma during soma-

Somatostatin receptors in meningioma

Table 1. Distribution of histological subtypes according to the 2007 World Health Organization (WHO) classification

Histological subtype	n (%)
Meningothelial	25 (41.5)
Fibrous (fibroblastic)	2 (3.3)
Transitional (mixed)	9 (15.0)
Psammomatous	6 (10.0)
Angiomatous	1 (1.7)
Microcystic	2 (3.3)
Secretory	2 (3.3)
Atypical	11 (18.3)
Rhabdoid	1 (1.7)
Anaplastic (malignant)	1 (1.7)

tostatin receptor scintigraphy. Furthermore, immunohistochemical methods could prove useful in identifying those cases of recurrent disease that may possibly respond to therapy with SSTRs-selective agonists.

Materials and methods

The study sample included tumor tissue specimens obtained from 60 patients with an anatomicopathologic diagnosis of meningioma who underwent surgical resection performed by the same surgeon (NPF) at Hospital São José, Complexo Hospitalar Santa Casa de Porto Alegre, Southern Brazil, between July 2013 and August 2014. Tumors were classified according to the World Health Organization (WHO) criteria for histological subtypes and tumor grading (grade I-III). Patient's medical records were reviewed for data collection, and 38 patients were followed-up. The study was approved by the Research Ethics Committee of Hospital Santa Casa de Misericórdia de Porto Alegre, Brazil (protocol No. 611.402), and conducted in accordance with the provisions of the Declaration of Helsinki. Written informed consent was obtained from all individual participants included in the study, and the privacy and data confidentiality of patients were preserved.

Immunohistochemistry

For immunohistochemical analysis, tumor tissue sections were fixed in 10% buffered formalin and embedded in paraffin. The blocks were sectioned at 4 μ m, deparaffinized, and rehydrated. The labeled streptavidin-biotin method

(LSAB kit + Peroxidase; Dako, Carpinteria, CA, USA) was used for SSTR detection, employing the following primary antibodies: SSTR1: polyclonal anti-SSTR1 (1:300 dilution; Chemicon, USA, Catalog No. AB9283); SSTR2: polyclonal anti-SSTR2 (1:100 dilution; Abcam, USA, Catalog No. AB140933); SSTR3: polyclonal anti-SSTR3 (1:400 dilution; Chemicon, USA, Catalog No. AB9285); SSTR4: polyclonal anti-SSTR4 (1:400 dilution; Chemicon, USA, Catalog No. AB9487); and SSTR5: polyclonal anti-SSTR5 (1:100 dilution; Chemicon, USA, Catalog No. AB9287). Normal human pituitary tissue was used as a positive control. As a negative control, the primary antibodies were replaced with saline. Immunohistochemical staining patterns were assessed as described previously [8]. Briefly, the presence or absence of staining and the depth of color were noted. The depth of color was recorded as pale, medium, or dark according to how easily it was seen. The tumors were then categorized as weak, moderate, or strong stainers according to the following criteria: (a) strong (+++), dark staining at the plasma membrane that is easily visible with a low-power objective; (b) moderate (++) , medium staining that is visible with a low-power objective; (c) weak (+), pale staining that is not easily seen under a low-power objective; and (d) negative (-), tumors that show none of the above. Specimens were analyzed by two independent observers, using light microscopy.

Statistical analysis

Data are expressed as mean (SD) for continuous variables, and as relative frequency and percentage for categorical variables. Associations between SSTRs were analyzed using the chi-square test or Fisher's exact test as appropriate. The Kaplan-Meier method was used to estimate the rate of survival free of recurrence. The level of significance was set at 5%. Data analysis was carried out using the Statistical Package for the Social Sciences (SPSS, version 19.0; IBM Corp., USA).

Results

Of 60 patients, 44 were women (73.3%), with a female-to-male ratio of approximately 3:1. Mean (SD) patient age was 53.18 (12.6) years. According to the WHO grading scheme, 47 (78.3%) meningiomas were grade I, 11 (18.3%) were grade II, and 2 (3.3%) were grade III. The

Somatostatin receptors in meningioma

Table 2. Immunohistochemical expression of SSTR in our series of meningiomas

IH	SSTR1	SSTR2	SSTR3	SSTR4	SSTR5
+	37 (61.6%)	60 (100%)	48 (80.6%)	41 (68.3%)	47 (78.3%)
++	19 (51%)	10 (16%)	5 (10%)	11 (27%)	7 (15%)
+++	7 (19%)	6 (10%)	3 (6%)	17 (41%)	13 (28%)
Total	11 (30%)	44 (73%)	40 (83%)	13 (31%)	27 (57%)

Table 3. Immunohistochemical expression of somatostatin receptor (SSTR) subtypes in meningiomas classified according to the World Health Organization (WHO) histological grading criteria

Grade	SSTR1	SSTR2	SSTR3	SSTR4	SSTR5
I	27 (57%)	47 (100%)	37 (78%)	31 (66%)	41 (87%)
II	9 (82%)	11(100%)	10 (91%)	9 (82%)	5 (45%)
III	1 (50%)	2 (100%)	1 (50%)	1 (50%)	1 (50%)
P	0.266	0.308	0.908	0.107	0.013*

*statistical difference.

most prevalent histological subtypes were meningothelial (25, 41.5%), transitional (9, 15%), psammomatous (6, 10%), and atypical (11, 18.3%) (Table 1). Regarding meningioma location, 82.1% were located in region supratentorial and 17.9% located in region infratentorial, with no statistically significant difference in SSTR expression.

Table 2 shows the expression immunohistochemical in meningiomas analyzed. SSTR2 immunohistochemical expression was detected in 100% of cases, followed by SSTR3 in 80.6%, SSTR5 in 78.3%, SSTR4 in 68.3%, and SSTR1 in 61.6%. SSTR2 overexpression was detected in 100% of grade II and in 87.2% of grade III meningiomas. Table 3 shows the expression of all five SSTR subtypes according to tumor grade. SSTR5 expression was observed in 41/47 (87.3%) grade I and in 5/11 (45.5%) grade II meningiomas ($P < 0.013$). There were no statistically significant differences between the other SSTR subtypes regarding tumor grade, age, sex, or location.

Statistically significant associations between SSTR subtypes were observed, with strong immunopositivity for SSTR2 and SSTR5 (38.3%, $P < 0.007$) and SSTR2 and SSTR3 (68.3%, $P < 0.014$). Both associations were more commonly found in grade I meningiomas (Figure 1).

Surgical resection was performed in all 60 patients, but medical record data on the type of

resection were available only for 45 patients. Of these, 30 (66.7%) underwent complete resection and 15 (33.3%) underwent partial resection. Among the 30 patients that underwent complete resection, 22, 7, and 1 were grade I, II and III, respectively. For the patients that underwent partial resection, 13 were grade I and 2 were grade II.

Medical record data on clinical follow-up were available only for 38 patients. The median follow-up was 18 months (range 6-84 months). According to Kaplan-Meier analysis, the rate of survival free of recurrence at 2 years was 75.2% (Figure 2). Among these 38 patients, 5 (13%) died due to postoperative complications,

26 (78%) had stable disease without tumor recurrence or regrowth and 7 (21%) showed meningioma recurrence or regrowth (6 and 1 who had previously undergone partial and total resection, respectively). The patient with recurrence had grade III and patients with regrowth tumor, 5 had grade I, and 1 grade II. Of these, 4 are being followed-up, 1 received radiotherapy and 1 had 3 resections. There was no statistical difference between the five SSTRs and type of surgical resection and tumor regrowth/recurrence (Table 4).

Discussion

The present study analyzed a representative series of meningiomas that is consistent with data reported in the literature regarding peak incidence age and female prevalence, as supratentorial location, and higher incidence of grade I tumors [2, 12-14]. The median follow-up of 33 patients was 18 months (interquartile range, 9.5-28 months), which is in agreement with previous studies of 26 patients [15] and 10-years follow-up [16]. Tumor recurrence/regrowth was observed in 18.4% (7/38) of cases, supporting the results of earlier studies that have shown recurrence rates ranging from 6 to 39% [16, 17].

Regarding recurrence-free survival, a survival rate of 75.2% was observed at 2 years in the present study, which is consistent with reports of survival rates ranging from 67.8 to 97% at

Somatostatin receptors in meningioma

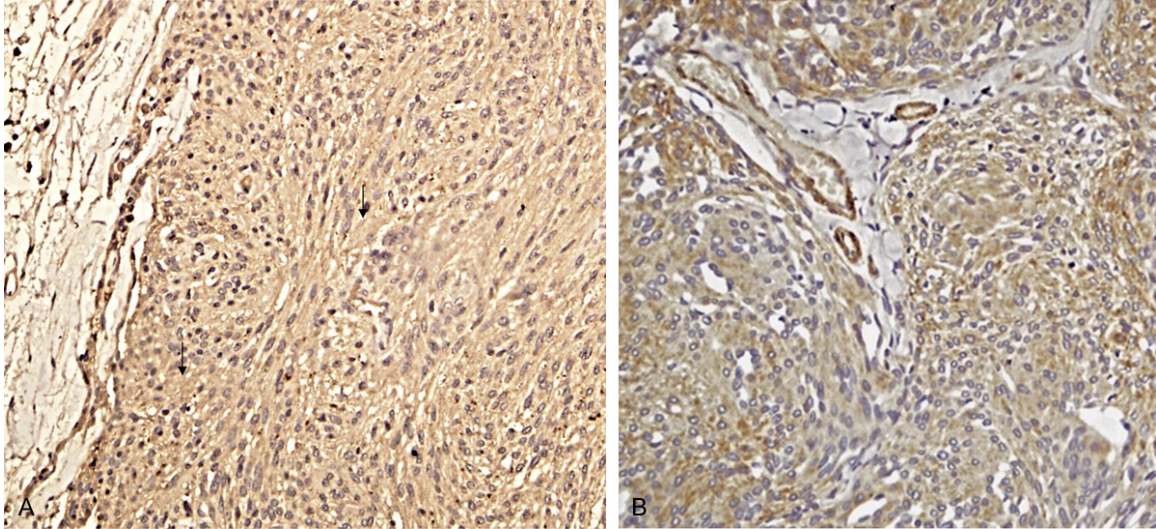


Figure 1. A. SSTR2: expression cytoplasmatic (+++) and endothelial (arrows) in meningioma (400×). B. SSTR5 expression cytoplasmatic (++) in meningioma (400×).

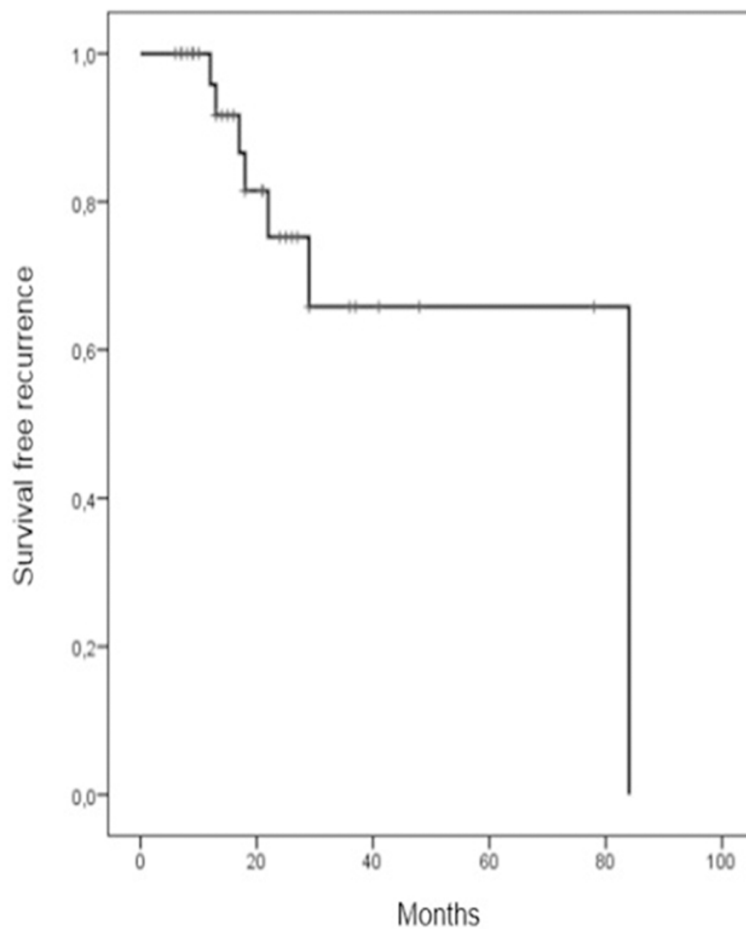


Figure 2. Kaplan-Meier curve showing the rate of survival free of recurrence in meningiomas analyzed.

2-10 years [17-19]. In this series of meningiomas, there were no statistically significant differences in SSTR expression regarding patient age and sex or tumor location and recurrence, which is in agreement with previous studies [20, 21].

A statistically significant association was found for completely resected meningiomas without tumor recurrence. Recurrence was reported in only one patient with grade III tumor, supporting previous findings that more aggressive meningiomas are associated with an increased risk of recurrence [22-25]. High expression of SSTR2 (100%) and SSTR3 (87%) was demonstrated in partially resected meningiomas with tumor regrowth. There are no data in the literature on immunohistochemical expression of SSTRs recurrent meningiomas, thereby hindering a proper comparison of the results.

Somatostatin receptors in meningioma

Table 4. Immunohistochemical expression of somatostatin receptor (SSTR) subtypes in meningiomas according to surgical resection and recurrence/regrowth

Patients	Type of resection	Recurrence/Regrowth	Expression of subtypes
1	Complete	Recurrence	All subtype
2	Partial	Regrowth	SSTR2/SSTR3/SSTR4
3	Partial	Regrowth	SSTR2/SSTR3/SSTR4/SSTR1
4	Partial	Regrowth	SSTR2/SSTR3/SSTR4
5	Partial	Regrowth	SSTR2/SSTR3/SSTR5/SSTR1
6	Partial	Regrowth	SSTR2/SSTR3/SSTR5
7	Partial	Regrowth	SSTR2/SSTR5/SSTR1

Meningiomas express SSTRs on their surface, with a predominance of the SSTR2 subtype. However, its *in vitro* mechanism of action remains unclear [9]. In our series of meningiomas, positivity was observed for all five SSTR subtypes, with strong positivity for SSTR2 in 100% of cases, which is consistent with the results obtained by Wang et al [26], suggesting that SSTRs may serve as a basis for future therapeutic applications. SSTR1 and SSTR2 expression was also detected in endothelial cells, a finding consistent with the results of Taniyama et al [27], who demonstrated the expression of SSTRs not only in parenchymal cells but also in lymphocytes, fibroblasts, and endothelial cells.

In our series, SSTR2 expression was detected in grade I, II, and III meningiomas, with no correlation between tumor grade, which is in agreement with the findings of Arena et al [9]. However, studies have demonstrated SSTR2 expression in grade II and III meningiomas [26, 28, 29]. Unlike the results obtained by Durand et al [24], who detected higher SSTR2 expression in meningothelial meningiomas, suggesting the possibility of a different tumorigenesis process in this histological subtype, we found no statistical difference between the expression of SSTRs and histological subtypes. In the present analysis, SSTR2 expression was not considered predictive of malignancy, as previously reported for neuroblastomas [29].

SSTR5 expression was observed in 41/47 (87.3%) grade I meningiomas and in 5/11 (45.5%) grade II meningiomas ($P < 0.013$). A study conducted by Schulz et al [8], using an immunohistochemical method, demonstrated low expression (11%) of this receptor in meningiomas, without correlation with tumor grade.

In a quantitative real-time polymerase chain reaction (RT-PCR) analysis of meningiomas, 67% of grade I tumors were positive for SSTR5 [30]. SSTR5 is associated with better treatment response in less aggressive liver tumors [31], suggesting that the positive expression of this receptor is a potent biomarker predictive of therapeutic response.

SST receptor subtypes, co-expressed in the same cells, can also form heteromeric complexes within

SST receptors, or heterodimerize with members of different GPCR family, as dopamine. High expression of receptors of dopamine was observed in meningiomas [32]. Clinical trials of chimeric molecules that bind SSTR2 as well as DR2 will provide information about association between different G protein-coupled receptors, suggesting the use of combination therapy. We found an association between SSTR2/SSTR5 with strong immunopositivity in 23 cases (38.3%, $P < 0.007$). These associations are expressed in growth hormone-secreting pituitary adenomas [33] and gastroenteropancreatic neuroendocrine tumors [34]. The SSTR2/SSTR5 expression has been described in endothelial cells during proliferative processes, and antiproliferative effects were observed after the use of specific analogs, suggesting an association with endothelial cell angiogenesis [35]. In gastroenteropancreatic neuroendocrine tumors, SSTR2 and SSTR5 negative expression was associated with decreased recurrence-free survival, resulting in poor prognosis [36]. In the present series, 20 (86%) of meningiomas with high SSTR2/SSTR5 expression were grade I, and in meningiomas with tumor regrowth, the positive expression rates of SSTR2/SSTR5 were 66.6%, suggesting that these receptors might be associated with improved prognosis.

An association was also found between subtypes SSTR2 and SSTR3, with strong immunopositivity in 40 cases of tumors benign (68.3%, $P < 0.014$). This expression pattern has been reported in other tumors, such as succinate dehydrogenase (an enzyme associated with malignant behavior) -deficient pheochromocytomas and paragangliomas [37]. In cells culture, the heterodimerization of SSTR2 and SSTR3 shown activation only SSTR2 suggest-

ing that heterodimerization results in a receptor with a pharmacological profile resembling that of SSTR2, however appears to be more resistant to agonist-induced desensitization [38]. SST2 was commonest expresses in neuroendocrine neoplasm and co-expressed with SSTR3 and SSTR5 in 32% and 24% of the specimens [39]. There are no reports in the literature of the association of these SSTR subtypes (SSTR5/SSTR2 and SSTR2/SSTR3) in meningiomas, thereby hindering comparisons.

No statistically significant association was found between all other variables and subtypes SSTR1 and SSTR4. The positive expression rate of SSTR1 in our series (61.6%) supports the results of Xiao et al [40], who demonstrated higher immunohistochemical expression of this receptor in meningiomas (65.4%) than in normal brain tissue (28.6%). As for SSTR4, the immunohistochemical expression rate of this receptor was 68.3%, above the rate of 33% reported by Arena et al [9].

In conclusion, the immunohistochemical expression of SSTRs was detected at a significant frequency in the present series of meningiomas, supporting the use of these receptors for imaging confirmation and possibly in long-acting somatostatin analog therapy. Prospective randomized trials, with a longer follow-up and a larger number of patients, are required to confirm the action of these receptors in tumorigenesis of meningiomas.

Disclosure of conflict of interest

None.

Address correspondence to: Dr. Camila Batista de Oliveira Silva, Department of Laboratory of Pathology, University of Health Sciences of Porto Alegre, Rio Grande do Sul, Sarmento Leite, 245-90050-170, Porto Alegre, RS, Brazil. Tel: + 55 51 8313.2778; E-mail: mila_batistaa@hotmail.com

References

- [1] Santana PA Jr, Marie SKN, Aguiar PHP. Biologia molecular dos meningiomas: um caminho promissor para a sua abordagem. *Meningiomas Diagnóstico e tratamento clínico e cirúrgico: aspectos gerais*. In: Aguiar PHP, Ramina R, Veiga JCE, Tella O Jr, editors. Rio de Janeiro: Revinter; 2006; pp. 11-14.
- [2] Dolecek TA, Propp JM, Stroup NE, Kruchko C. CBTRUS statistical report: primary brain and central nervous system tumors diagnosed in the United States in 2005-2009. *Neuro Oncol* 2013; 15: 646-647.
- [3] Wahab M, Al-Azzawi F. Meningioma and hormonal influences. *Climacteric* 2003; 6: 285-292.
- [4] Leães CG, Meurer RT, Coutinho LB, Ferreira NP, Pereira-Lima JF, da Costa Oliveira M. Immunohistochemical expression of aromatase and estrogen, androgen and progesterone receptors in normal and neoplastic human meningeal cells. *Neuropathology* 2010; 30: 44-49.
- [5] Carroll RS, Zhang J, Dashner K, Black PM. Progesterone and glucocorticoid receptor activation in meningiomas. *Neurosurgery* 1995; 37: 92-97.
- [6] Reubi JC, Maurer R, Klijn JG, Stefanko SZ, Foekens JA, Blaauw G, Blankenstein MA, Lamberts SW. High incidence of somatostatin receptors in human meningiomas: biochemical characterization. *J Clin Endocrinol Metab* 1986; 63: 433-438.
- [7] Reubi JC, Schaer JC, Waser B, Mengod G. Expression and localization of somatostatin receptor SSTR1, SSTR2, and SSTR3 messenger RNAs in primary human tumors using in situ hybridization. *Cancer Res* 1994; 54: 3455-3459.
- [8] Schulz S, Pauli SU, Schulz S, Händel M, Dietzmann K, Firsching R, Höllt V. Immunohistochemical determination of five somatostatin receptors in meningioma reveals frequent overexpression of somatostatin receptor subtype sst2A. *Clin Cancer Res* 2000; 6: 1865-1874.
- [9] Arena S, Barbieri F, Thellung S, Pirani P, Corsaro A, Villa V, Dadati P, Dorcaratto A, Lapertosa G, Ravetti JL, Spaziante R, Schettini G, Florio T. Expression of somatostatin receptor mRNA in human meningiomas and their implication in in vitro antiproliferative activity. *J Neurooncol* 2004; 66: 155-166.
- [10] Durán-Prado M, Malagón MM, Gracia-Navarro F, Castaño JP. Dimerization of G protein-coupled receptors: new avenues for somatostatin receptor signalling, control and functioning. *Mol Cell Endocrinol* 2008; 286: 63-68.
- [11] Ragel B, Jensen RL. New approaches for the treatment of refractory meningiomas. *Cancer Control* 2003; 10: 148-158.
- [12] Pittella JEH, Rosemberg S, Hahn MD, Chimelli L, Grinberg LT, Andrade MPG, Heisen H, Neder L. Sistema Nervoso. In: Brasileiro Filho G, Pittella JEH, editors. *Patologia*. Rio de Janeiro: Guanabara Koogan; 2011. pp. 1008-1009.
- [13] Rubin G, Herscovici Z, Laviv Y, Jackson S, Rapaport ZH. Outcome of untreated meningiomas. *Isr Med Assoc J* 2011; 13: 157-160.
- [14] Hilbig A, Barbosa-Coutinho LM. Meningiomas and hormonal receptors. *Immunohistochemi-*

Somatostatin receptors in meningioma

- cal study in typical and non-typical tumors. *Arq Neuropsiquiatr* 1998; 56: 193-199.
- [15] Serna E, Morales JM, Mata M, Gonzalez-Darder J, San Miguel T, Gil-Benso R, Lopez-Gines C, Cerda-Nicolas M, Monleon D. Gene expression profiles of metabolic aggressiveness and tumor recurrence in benign meningioma. *PLoS One* 2013; 8: e67291.
- [16] Nakasu S, Fukami T, Jito J, Nozaki K. Recurrence and regrowth of benign meningiomas. *Brain Tumor Pathol* 2009; 26: 69-72.
- [17] Kim MS, Kim KH, Lee EH, Lee YM, Lee SH, Kim HD, Kim YZ. Results of immunohistochemical staining for cell cycle regulators predict the recurrence of atypical meningiomas. *J Neurosurg* 2014; 121: 1189-1200.
- [18] Sun SQ, Kim AH, Cai C, Murphy RK, DeWees T, Sylvester P, Dacey RG, Grubb RL, Rich KM, Zipfel GJ, Dowling JL, Leuthardt EC, Leonard JR, Evans J, Simpson JR, Robinson CG, Perrin RJ, Huang J, Chicoine MR. Management of atypical cranial meningiomas, part 1: predictors of recurrence and the role of adjuvant radiation after gross total resection. *Neurosurgery* 2014; 75: 347-354.
- [19] Hasan S, Young M, Albert T, Shah AH, Okoye C, Bregy A, Lo SS, Ishkanian F, Komotar RJ. The role of adjuvant radiotherapy following gross total resection of atypical meningiomas. *World Neurosurg* 2014; S1878-8750: 1408-1409.
- [20] Ildan F, Erman T, Göçer AI, Tuna M, Bağdatoğlu H, Çetinalp E, Burgut R. Predicting the probability of meningioma recurrence in the preoperative and early postoperative period: a multivariate analysis in the midterm follow-up. *Skull Base* 2007; 17: 157-171.
- [21] Adegbite AB, Khan MI, Paine KW, Tan LK. The recurrence of intracranial meningiomas after surgical treatment. *J Neurosurg* 1983; 58: 51-66.
- [22] Simpson D. The recurrence of intracranial meningiomas after surgical treatment. *J Neurol Neurosurg Psychiatry* 1957; 20: 22-39.
- [23] Marosi C, Hassler M, Roessler K, Reni M, Sant M, Mazza E, Vecht C. Meningioma. *Crit Rev Oncol Hematol* 2008; 67: 153-171.
- [24] Durand A, Champier J, Jouvet A, Labrousse F, Honnorat J, Guyotat J, Fèvre-Montange M. Expression of c-Myc, neurofibromatosis Type 2, somatostatin receptor 2 and erb-B2 in human meningiomas: relation to grades or histotypes. *Clin Neuropathol* 2008; 27: 334-345.
- [25] Mawrin C, Perry A. Pathological classification and molecular genetics of meningiomas. *J Neurooncol* 2010; 99: 379-391.
- [26] Wang S, Yang W, Deng J, Zhang J, Ma F, Wang J. Correlation between 99m Tc-HYNIC-octreotide SPECT/CT somatostatin receptor scintigraphy and pathological grading of meningioma. *J Neurooncol* 2013; 113: 519-526.
- [27] Taniyama Y, Suzuki T, Mikami Y, Moriya T, Satomi S, Sasano H. Systemic distribution of somatostatin receptor subtypes in human: an immunohistochemical study. *Endocr J* 2005; 52: 605-611.
- [28] Barresi V. Angiogenesis in meningiomas. *Brain Tumor Pathol* 2011; 28: 99-106.
- [29] Raggi CC, Maggi M, Renzi D, Calabrò A, Bagnoni ML, Scaruffi P, Tonini GP, Pazzagli M, De Bernardi B, Bernini G, Serio M, Orlando C. Quantitative determination of sst2 gene expression in neuroblastoma tumor predicts patient outcome. *J Clin Endocrinol Metab* 2000; 85: 3866-3873.
- [30] Dutour A, Kumar U, Panetta R, Ouafik L, Fina F, Sasi R, Patel YC. Expression of somatostatin receptor subtypes in human brain tumors. *Int J Cancer* 1998; 76: 620-627.
- [31] Cives M, Kunz PL, Morse B, Coppola D, Schell MJ, Campos T, Nguyen PT, Nandoskar P, Khandelwal V, Strosberg JR. Phase II clinical trial of pasireotide long-acting repeatable in patients with metastatic neuroendocrine tumors. *Endocr Relat Cancer* 2015; 22: 1-9.
- [32] Trott G, Pereira-Lima JFS, Leães CGS, Ferreira NP, Barbosa-Coutinho LM, Oliveira MC. Abundant immunohistochemical expression of dopamine D2 receptor and p53 protein in meningiomas: follow-up, relation to gender, age, tumor grade, and recurrence. *Braz J Med Biol Res* 2015; 48: 415-9.
- [33] Zatelli MC, Piccin D, Tagliati F, Bottoni A, Ambrosio MR, Margutti A, Scanarini M, Bondanelli M, Culler MD, degliUberti EC. Dopamine receptor subtype 2 and somatostatin receptor subtype 5 expression influences somatostatin analogs effects on human somatotroph pituitary adenomas in vitro. *J Mol Endocrinol* 2005; 35: 333-341.
- [34] Delaunoy T, Rubin J, Neczyporenko F, Erlichman C, Hobday TJ. Somatostatin analogues in the treatment of gastroenteropancreatic neuroendocrine tumors. *Mayo Clin Proc* 2005; 80: 502-506.
- [35] Adams RL, Adams IP, Lindow SW, Zhong W, Atkin SL. Somatostatin receptors 2 and 5 are preferentially expressed in proliferating endothelium. *Br J Cancer* 2005; 92: 1493-1498.
- [36] Zhao WY, Zhuang C, Xu J, Wang M, Zhang ZZ, Tu L, Wang CJ, Ling TL, Cao H, Zhang ZG. Somatostatin receptors in gastrointestinal stromal tumors: new prognostic biomarker and potential therapeutic strategy. *Am J Transl Res* 2014; 6: 831-840.
- [37] Elston MS, Meyer-Rochow GY, Conaglen HM, Clarkson A, Clifton-Bligh RJ, Conaglen JV, Gill AJ. Increased SSTR2A and SSTR3 expression in succinate dehydrogenase-deficient pheochromocytomas and paragangliomas. *Hum Pathol* 2015; 46: 390-396.

Somatostatin receptors in meningioma

- [38] Pfeiffer M, Koch T, Schroder H, Klutzny M, Kirscht S, Kreienkamp HJ, Holtt V, Schulz S. Homo- and heterodimerization of somatostatin receptorsubtypes. Inactivation of sst3 receptor function by heterodimerization withsst2A. *J Biol Chem* 2000; 276: 14027-14036.
- [39] Diakatou E, Alexandraki KI, Tsolaski AV, Kontogeorgos G, Chatzellis E, Leonti A, Kaltsas GA. Somatostatin and dopamine receptor expression in neuroendocrine neoplasm: correlation of immunohistochemical findings with somatostatin receptor scintigraphy visual scores. *Clin Endocrinol* 2015; 1-9.
- [40] Xiao Q, Gu XW, Tian XC, Wang CM. Expression of GHR and SSTR1 and their clinical significance in meningioma. *Chin J Clin Exp Pathol* 2012; 8: 15.