

Original Article

Clinical characterization for proliferation and metastasis in advanced hepatocellular carcinoma patients

Cuirong Wei^{1*}, Qijin Pan^{2*}, Ka Wu³, Rong Li^{4,5}

Departments of ¹Pathology, ²Oncology, Guigang City People's Hospital, The Eighth Affiliated Hospital of Guangxi Medical University, Guigang 537100, Guangxi, PR China; ³Department of Pharmacy, The Second People's Hospital of Nanning City, Nanning 530031, Guangxi, PR China; ⁴Guilin Medical University, Guilin 541004, Guangxi, PR China; ⁵Department of Biology, Hong Kong Baptist University, Hong Kong, China. *Equal contributors.

Received August 14, 2015; Accepted September 23, 2015; Epub October 1, 2015; Published October 15, 2015

Abstract: Here we reported that association between drug resistance and carcinomatosis in advanced liver cancer cases. All subjects (n=4) were periodically received chemotherapeutic agents when clinical manifestation being defined serologically. Hepatic specimen was harvested via biopsy and further prepared as paraffin-slice before conducting immunohistochemistry. As a consequence, more detectable biomarkers, such as AST, AFP, GGT2, were high expressed in plasma when compared to clinical standards. DNA topoisomerase II (TOPO II), Ki-67 were immunoreactively labeled in cytoplasm/membrane and nucleolus of liver cancer cells, while hepatocellular tumor protein p53 was negative or non-detected. Additionally, we found that hepatobiliary cancer showed epithelial differentiation with pronounced CK19 immunoreactivity when metastasizing. Our clinicopathologic findings demonstrate that correlation between carcinomatous proliferation/metastasis and drug resistance protein expression. Furthermore, these evidences indicate that TOPO II may be a biomarker for advanced hepatocellular carcinoma patient receiving chemotherapeutics.

Keywords: Hepatocellular carcinoma, proliferation, metastasis, biomarker

Introduction

Hepatocellular carcinoma, simply abbreviated to HCC, is the most lethal primary malignancy, in which its onset is strongly related to uncontrolled cell proliferation and unregulated metastasis [1]. In clinical regimen, chemotherapy targets to kill cells that divide rapidly. However, common side-effects, such as myelosuppression, mucositis and alopecia, occur when healthy cells are also damaged [2, 3]. In addition, therapeutic schedule for advanced cancer patient will be hard to prescribe because of debilitated vital sign and drug resistance [4, 5]. Hence, screening one or more biomarkers that reflect drug-resistant characteristic is feasible strategy in clinical practice. Therefore, the purpose of this report highlights that clinical evidences show the potential correlation between advanced hepatocellular carcinoma development and a representative biomarker associated with drug tolerance.

Patients and methods

All the liver cancer patients were hospitalized and given clinical treatment. The suffers were conducted routine diagnoses, such as hematologic and biochemistry assays. This study was followed with the ethical guidelines of the Declaration of Helsinki.

Liver specimen was harvested through biopsy prior to being prepared as paraffin-embedded block. 5 μ m slice was subjected to immunohistochemistry staining. As a process, the section was incubated with primary antibodies (1:100; Fuzhou Maixin Biotech. Co., Ltd.) at 4°C overnight and then exposed to secondary antibodies (Fuzhou Maixin Biotech. Co., Ltd.) for 1 h at room temperature. Subsequently, antigen-antibody complex was yielded coloration with 3,3'-diaminobenzidine and further stained with haematoxylin in nuclei.

Cell proliferation in advanced liver cancer tissue

Table 1. Archiving of advanced hepatocellular carcinoma patients

Cases	Age/Sex	Hepalocyle	CK19	Gly-3	P53	TOPO II	Ki-67/Area
1	71 (Male)	-	+	-	-	+	30%
2	51 (Male)	+	-	-	-	++	30%
3	65 (Male)	-	-	+	-	++	40%
4	59 (Female)	-	-	-	-	+	10%

Note: "-" refers to as negative result; "+" refers to as positive result; "++" refers to as high positive result.

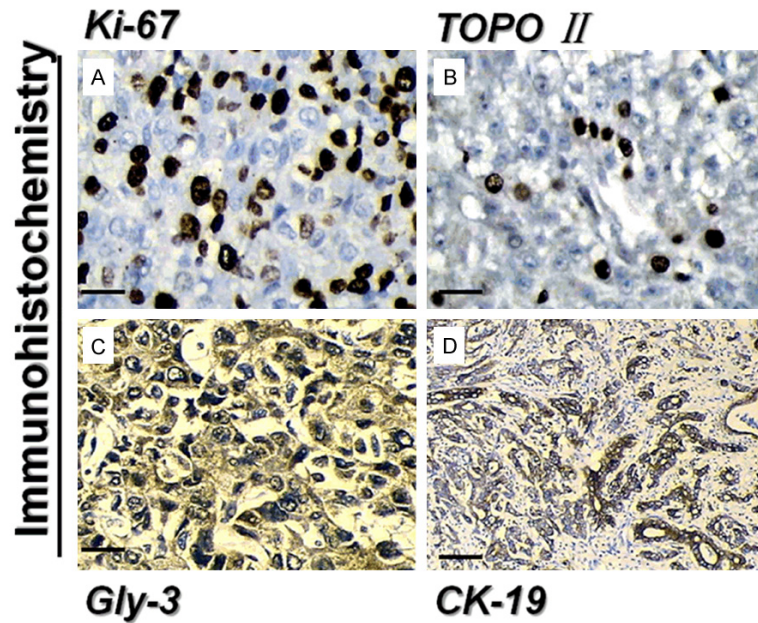


Figure 1. Microscopic images showed representative immunophenotypes during advanced hepatocellular carcinoma development (Immunohistochemical staining; scale bar: A-C=20 mm; D=50 mm). As a result, widespread of Ki-67 proliferated cells (brown) were expressed in the hepatic nuclei, while the visible immunoreactivity of TOPO II drug resistance indicator (brown) indicated the association with cancer differentiation. Further, glypican-3 (Gly-3) is a pre-metastasis marker for hepatocellular carcinoma when developing. Hepatobiliary strong CK19 positive expression functioned as a predictor of post-treatment recurrence related to increased invasiveness.

Results

Assessing in-patient characteristics

In present report, 4 advanced patients with HCC were screened, with the serological results of increased aspartate aminotransferase (AST), hepatitis B surface antigen (HBsAg), α -fetoprotein (AFP) and γ -glutamyl transferase (GGT2). And demographic properties displayed the mean age 61.5 from 2 male and 2 female suffers.

Clinicopathologic examination for immunophenotypes

In order to screen the characterization and distribution of immunophenotypes in HCC, hepatic

slices were subjected to immunohistochemistry stains. As shown in representative clinical pathological data, bile duct nodules within the liver, an avenue for metastasis, contained significant CK19-, Ki-67 positive cells and in turn non-detected P53-positive cells. In addition, immunoassay findings suggested that positive staining for TOPO II and strongly staining for ki-67 were labeled in nuclei of hepatocellular carcinoma, while Gly-3-immunoreactive protein was located in membrane and cytoplasm (Table 1; Figure 1).

Discussion

Previous evidences show that proliferation-dependent oncogenesis relates to drug resistance, eventually resulting in metastasis [6]. P53, also known as tumor suppressor p53, exerts the anti-cancer function via molecular mechanisms of initiating apoptosis, arresting cell growth, and modulating interlaced signal pathways [7]. Once p53 mutation occurs, the condition will lead to cancer stem cell differentiation in different tissues [8].

Hence, a potential clinical strategy for managing apoptosis-associated with p53 pathway may help prevent from anti-cancer medication resistance.

In the present report, immunohistochemical analysis suggested that advanced HCC sections contained high-proportional proliferation cells (ki-67 positive cells) and negative for p53-immunoreactivity, matched for up-regulated TOPO II expression in nucleolus. Together, our clinical observations revealed that TOPO II, a critical drug-resistance gene/protein, might be a potential biomarker to optimize medication prescription for advanced HCC patients.

As targeted in clinical significance, the clinicopathological findings can provide available ref-

Cell proliferation in advanced liver cancer tissue

erence for therapists prior to delivery of optimal treatment against HCC.

Acknowledgements

This report was funded from Science and Technology Research Projects of Guangxi Universities (No. KY2014048 and KY2015-LX283), as well as National Nature Science Foundation of China (No. 81560134).

Disclosure of conflict of interest

None.

Address correspondence to: Dr. Rong Li, Faculty of Basic Medicine, Guilin Medical University, 109 Huan Cheng North 2nd Road, Guilin 541004, China. Tel: + 86 773 5895882; Fax: + 86 773 5895132; E-mail: liron1278@163.com; 14485796@life.hkbu.edu.hk

References

- [1] Berzigotti A, Reig M, Abraldes JG, Bosch J, Bruix J. Portal hypertension and the outcome of surgery for hepatocellular carcinoma in compensated cirrhosis: a systematic review and meta-analysis. *Hepatology* 2015; 61: 526-536.
- [2] Shaaban S, Negm A, Ibrahim EE, Elrazak AA. Chemotherapeutic agents for the treatment of hepatocellular carcinoma: efficacy and mode of action. *Oncol Rev* 2014; 8: 246-246.
- [3] Ueda H, Fukuchi H, Tanaka C. Toxicity and efficacy of hepatic arterial infusion chemotherapy for advanced hepatocellular carcinoma (Review). *Oncol Lett* 2012; 3: 259-263.
- [4] Wang XQ, Ongkeko WM, Chen L, Yang ZF, Lu P, Chen KK, Lopez JP, Poon RT, Fan ST. Octamer 4 (Oct4) mediates chemotherapeutic drug resistance in liver cancer cells through a potential Oct4-AKT-ATP-binding cassette G2 pathway. *Hepatology* 2010; 52: 528-539.
- [5] Hong L, Han Y, Zhang H, Zhao Q, Wu K, Fan D. Drug resistance-related miRNAs in hepatocellular cancer. *Expert Rev Gastroenterol Hepatol* 2014; 8: 283-288.
- [6] Gupta SC, Kim JH, Prasad S, Aggarwal BB. Regulation of survival, proliferation, invasion, angiogenesis, and metastasis of tumor cells through modulation of inflammatory pathways by nutraceuticals. *Cancer Metastasis Rev* 2010; 29: 405-434.
- [7] Ryan KM, Phillips AC, Vousden KH. Regulation and function of the p53 tumor suppressor protein. *Curr Opin Cell Biol* 2001; 13: 332-337.
- [8] Aloni-Grinstein R, Shetzer Y, Kaufman T, Rotter V. p53: the barrier to cancer stem cell formation. *FEBS Lett* 2014; 588: 2580-2589.