

Case Report

Role of multidisciplinary approach in a case of Langerhans cell histiocytosis with initial periodontal manifestations

Angelo Cisternino¹, Farah Asa'ad^{2,3}, Nicola Fusco⁴, Stefano Ferrero^{2,4}, Giulio Rasperini^{2,3}

¹Private Dental Practice, Brescia, Italy; ²Department of Biomedical, Surgical and Dental Sciences, University of Milan, Italy; ³Division of Periodontology, Fondazione IRCCS Ca' Granda-Ospedale Maggiore Policlinico, Milan, Italy; ⁴Division of Pathology, Fondazione IRCCS Ca' Granda-Ospedale Maggiore Policlinico, Milan, Italy

Received August 29, 2015; Accepted September 28, 2015; Epub October 1, 2015; Published October 15, 2015

Abstract: Introduction: Langerhans cell histiocytosis (LCH) is a rare inflammatory myeloid neoplasia of unknown etiology occurring in both children and adults. This condition is characterized by an abnormal proliferation of Langerhans cells that may virtually affect all sites in the human body. Oral manifestations of LCH could be the first clinical sign of disease and its periodontal localization could be easily mistaken for other more common entities, such as chronic periodontitis, aggressive periodontitis, and necrotizing ulcerative periodontitis. Case presentation: A 32-years old female visited a private dental practice with a chief complaint of sensitivity in the mandibular left first molar. Clinical and radiographic examination revealed deep periodontal pocket, recession, furcation involvement, mobility, severe alveolar bone destruction and a diagnosis of aggressive periodontitis was rendered. Multiple tooth extractions were carried out due to progressive periodontal destruction with impaired healing and development of ulcerative lesions. Multidisciplinary investigation demonstrated that the periodontal involvement was a manifestation of an underlying systemic disease. A biopsy of a bone lesion was therefore performed, revealing the presence of multifocal single system LCH. Conclusion: The identification of periodontal LCH is not trivial given that it may clinically resemble other periodontal disease entities. The dentist can be the first health care personnel to unravel the presence of an underlying systemic LCH.

Keywords: Langerhans cell histiocytosis, systemic disease, bone lesions, periodontal disease

Introduction

Langerhans cell histiocytosis (LCH) is the most common histiocytic disorder, which is characterized by an abnormal proliferation of CD1a-positive histiocytes, *i.e.* Langerhans cells [1]. This exceedingly rare inflammatory myeloid neoplasia may affect virtually all organ systems of the human body, with no predilection of gender [1, 2]. Despite affecting any age group, from newborns to elders, the incidence of LCH is higher in children compared to adults, with a median age of presentation of 30 months [3]. In particular, young Caucasian individuals are reported to be the highest-risk population [4]. Although the etiology of LCH remains enigmatic, possible causative factors have been proposed, including disturbance in immunoregulation, genetic factors, thyroid diseases and

smoking [5-8]. The biology underpinning LCH is still a subject of debate; however, recent advances in the genomic characterization of this rare condition revealed the presence of an activating hotspot V600E somatic mutation in the proto-oncogene B-Raf (*BRAF*) in up to 57% of cases [9]. Moreover, activation of extracellular-signal-regulated kinases (ERKs) appeared to be universal in LCH in recent molecular studies [10].

The clinical course of LCH is highly variable and unpredictable, existing along a spectrum of disease that may involve a single site (unifocal), multiple sites (multifocal) in a single organ system or multiple organ systems (multisystem) which could affect a limited number of organs or either be disseminated and life threatening [2, 11]. Bone is the most commonly involved tis-

Periodontal Langerhans cell histiocytosis

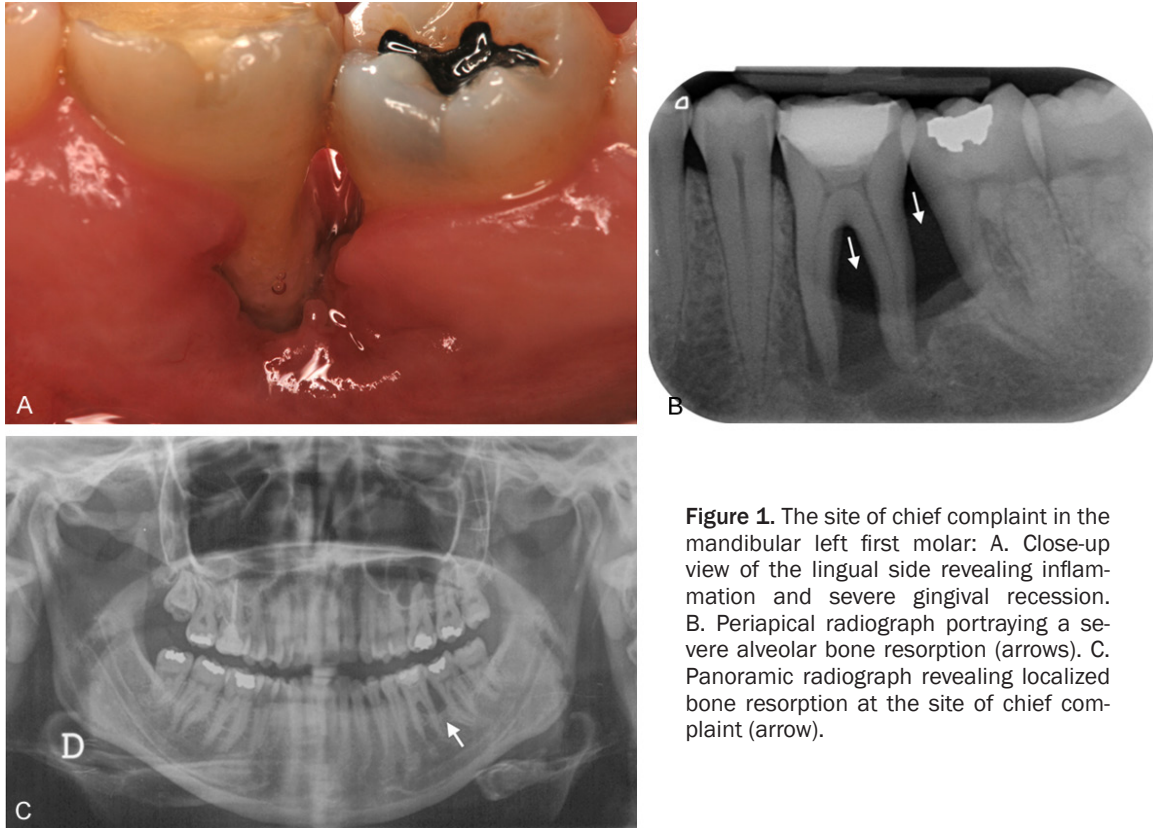


Figure 1. The site of chief complaint in the mandibular left first molar: A. Close-up view of the lingual side revealing inflammation and severe gingival recession. B. Periapical radiograph portraying a severe alveolar bone resorption (arrows). C. Panoramic radiograph revealing localized bone resorption at the site of chief complaint (arrow).

sue [12] with the skull being the most frequent site (55%), followed by vertebrae (30%) and jaws (26%) [13].

Oral manifestations could be the first sign of LCH, being reported in up to 20% of cases as the initial clinical event [14]. This condition may precede evidence of systemic disease, giving rise to nonspecific symptoms and generally prompts patients to seek dental treatment [6]. In this scenario, the role of the dentist is critical, particularly for cases in which the oral cavity is the only involved area [15]. Alveolar and basal bone lesions are common findings in oral LCH, with increased frequency in the molar region of the jaw [7]. Severe and progressive destruction of the alveolar bone gives rise to the characteristic radiographic appearance of floating teeth [6]. When periodontal tissues are involved, the gingival margin is typically erythematous and hyperplastic with evident ulceration of interdental papillae [16]. Bleeding, recession, ulceration, necrosis, and tooth hypermobility are common although nonspecific findings, since they may mimic other diseases of the periodontal region including chronic periodontitis, aggressive periodontitis, and necro-

tizing ulcerative periodontitis [15]. As a result, tooth exfoliation is a common finding. If teeth are extracted due to loosening and excessive mobility, delayed healing of the extraction sites occurs and could be suggestive for the presence of LCH [16].

Once biopsy is performed, diagnosis of LCH is straightforward, since the presence of an abnormal proliferation of CD1a-positive, S100-positive histiocytes with an inflammatory background, including variable numbers of lymphocytes (enriched for regulatory T cells), macrophages and eosinophils is pathognomonic [7, 16]. However, a multidisciplinary approach is essential to disclose any systemic involvement, since a correct patient's management is based on the integration of clinical, histological, radiographic, laboratory and molecular data [16].

The present case epitomizes the clinical situation of a single system LCH mimicking aggressive periodontitis in a patient with no other clinical signs. Although this is a single observation, we highlight the importance of a multidisciplinary approach in such rare conditions for a fruitful patient management.

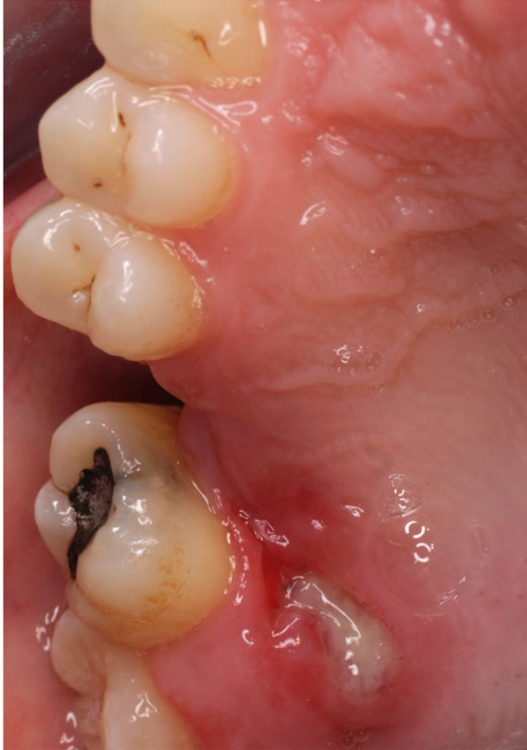

Figure 2. Close-up view of the soft tissue ulceration in the area palatal to the extracted maxillary right first molar.

Case report

A 32-year old Caucasian female visited a private dental practice in Brescia, Italy for a chief complaint of sensitivity in the mandibular left first molar. Medical history disclosed chronic hormone replacement therapy (HRT) due to gonadal dysgenesis. Intra-oral examination revealed edema and inflammation at the site of chief complaint, in the presence of severe gingival recession on the lingual side (10 mm), deep periodontal pocket (maximum depths: 10 mm buccally, 9 mm in lingually) grade 3 furcation involvement and grade 2 tooth mobility (**Figure 1A**). Gingival and plaque indexes were both 2. Intra-oral periapical and panoramic radiographs demonstrated a well-defined non-corticated radiolucent solitary lesion involving the mandibular left first and second molars. No signs of root resorption were evident (**Figure 1B** and **1C**). Based on these findings, a diagnosis of periodontal lesion suggestive for aggressive periodontitis was rendered.

Scaling and root planing were performed in multiple appointments. Oral hygiene instruc-

tions were given and chlorhexidine mouthwash (0.2%) was recommended for daily use (3 times/day for 10 days). Two months later, although soft tissue edema remarkably reduced, the mandibular left first molar was extracted due to symptomatic mobility and persistent root sensitivity. One month after extraction, soft tissues at the edentulous site were severely inflamed with delayed healing. Amoxicillin and clavulanic acid (875+125 mg, every 12 hours for 10 days), metronidazole (250 mg, every 8 hours for 10 days) and chlorhexidine mouthwash were therefore prescribed. Endosseous implant placement was planned and consultation for bone grafting procedures was scheduled with the oral maxillofacial surgeon, since the site of extraction lacked sufficient bone support. Based on the surgeon's assessment, the patient was not a candidate for bone grafting procedures due to impaired healing of soft tissues. At this point, the patient failed to show up for successive follow-up appointments for undisclosed reasons.

One year later, the patient attended the clinic complaining of symptoms in the mandibular right first molar. Intra-oral examination revealed severe gingival inflammation, excessive mobility and advanced alveolar bone destruction which was confirmed by radiographic analyses. Manual debridement was therefore performed and the same regimens of antibiotics and mouthwash were prescribed. After one month, the tooth was pulled out, given that the overall clinical conditions failed to show any improvement. Ulceration, fistulization and delayed soft tissue healing were noticeable few months after the extraction. Scaling was therefore performed and, a month later, the area of the mandibular right first molar was re-opened, scraped-out, debrided, and sutured. Periodontal assessment revealed increasing pocket depth on the distal site of the maxillary right first molar; manual debridement and oral hygiene instructions were provided within the next few months; however, multiple extractions were executed due to severe periodontal destruction. One year later, an ulcerative lesion was present in the area palatal to the right maxillary first molar (**Figure 2**). Panoramic radiograph revealed severe alveolar bone destruction with "floating teeth" appearance and an osteolytic bone lesion at the left angle of the mandible (**Figure 3**). With the deterioration of the overall clinical

Periodontal Langerhans cell histiocytosis

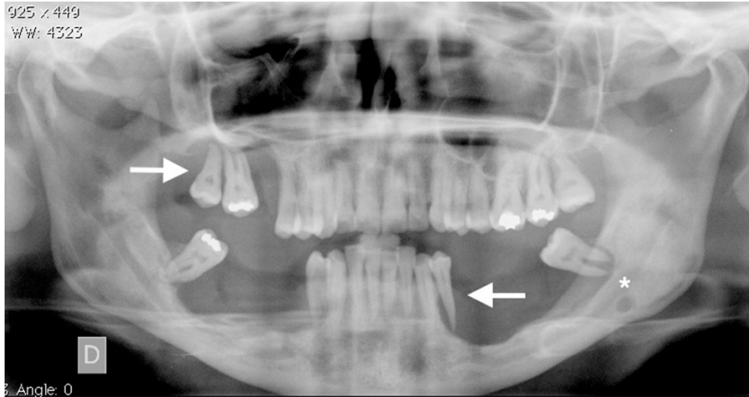


Figure 3. Panoramic radiograph showing the aggressive nature of the LCH. Severe bone destruction and the characteristic floating teeth appearance are evident (arrows), while a radiolucent lesion can be seen at the left angle of the mandible (star). This analysis was performed three years after the initial examination.

status and suspecting the presence of an underlying malignant condition, the patient was referred for deep analyses.

No abnormalities were observed in the laboratory and biochemical tests, while skull and sinus radiography displayed an oval radiolucency of 5 mm in size at the left angle of the mandible. Surprisingly, radiograph of the lower leg revealed multiple osteolytic bone lesions of the left tibia (**Figure 4A**). To define the nature of these lesions, bone-marrow aspiration and biopsy were performed. Histopathologic examination revealed a dense nodular proliferation of CD1a- and S100-positive Langerhans cells within bone in the background of a lymphocytic and granulocytic population consistent with LCH (**Figure 4B-D**). An additional biopsy was subsequently performed in order to determine the nature of the intra-oral lesion, showing mature disease-free compact bone.

The patient started radiotherapy and therefore possible improvement of the oral and periodontal condition is yet to be confirmed. At this point of time, bidirectional Sanger sequencing analysis and pyrosequencing of DNA extracted from bone tissue of the tibia detected the presence of the *BRAF* V600E hotspot somatic mutation, confirming the clonal origin of the neoplastic cells.

Discussion

LCH is an exceedingly rare dendritic cell disorder with variable clinical courses that is cur-

rently depicted as an inflammatory myeloid neoplasia [10]. LCH occurs less commonly in adults compared to the children, with an incidence of 1-2 adult individuals per million with an age range between 29 and 38 years [3, 17]. Manifestations in the oral cavity can be the first and even the only sign of LCH, often resulting in periodontal involvement [6, 15, 18].

In the present case, the patient was affected by multifocal single system LCH based on clinical, radiographic, histologic, ancillary and molecular find-

ings [11]. Periodontal manifestations were similar to those that can be observed in severe periodontal diseases, namely the presence of deep periodontal pockets, recession, furcation involvement, gingival bleeding and mobility [15]. This similarity, together with the rarity of this condition, resulted in an initial incorrect diagnosis. In fact, dentists and periodontists might lack familiarity with the exceptionally rare oral manifestations of LCH. Impaired soft tissue healing after extraction can be suggestive of LCH; however, multidisciplinary approaches are warranted. Furthermore, the lack of patient compliance in attending the scheduled appointments over a long period of time resulted in a deficient case monitoring that could have provided meaning for a biopsy much earlier.

Correct diagnosis at early stages is crucial in preventing progressive destruction, inevitable tooth loss and reduces the chances of negative sequelae. For this patient, histopathological findings of bone marrow biopsy from the tibia showed an atypical proliferation of CD1a-positive Langerhans cells which made the diagnosis of LCH trivial. However, the bioptic specimen from the mandibular bone underlying the area of extracted right third molar was inconclusive. This can be explained by the fact that a bone biopsy may be not representative of the entire lesion, particularly in cases of intraoral localization of LCH. When LCH is in question, a sufficient gingival biopsy should also be obtained, regardless tooth extraction [19]. At the molecular level, bone lesion of the left tibia harbored the recurrent V600E *BRAF* missense

Periodontal Langerhans cell histiocytosis

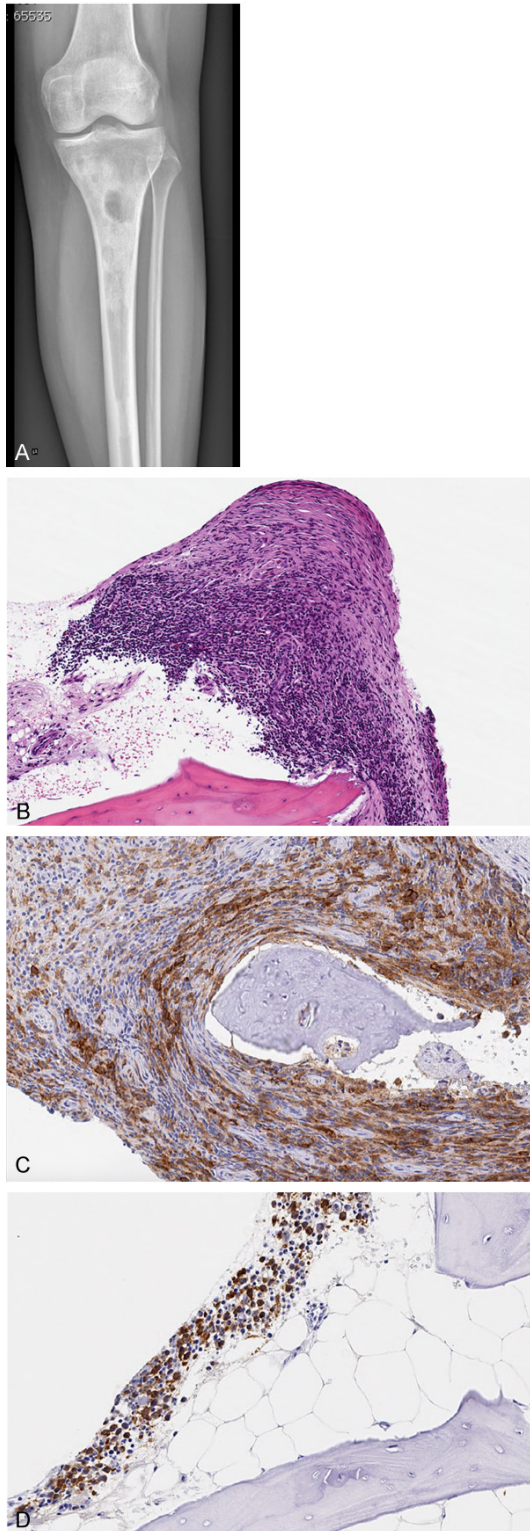


Figure 4. Left tibial localizations of multifocal systemic LCH in a patient with periodontal manifestation of disease. X-ray analysis (A) identified the presence of multiple radiolucent oval lesions of various size, with regular and sharp borders. The histologic examination confirmed the pathologic nature of these le-

sions, revealing the presence of abnormal nodular proliferation of histiocytes within the bone marrow with an inflammatory background (B) (hematoxylin and eosin, original magnification 10×). This histiocytic population displayed CD1a-positive (C) and S100-positive phenotype (D) at the immunohistochemical analysis (original magnification 20×).

mutation, providing strong circumstantial evidence that the association of LCH and *BRAF* somatic mutations is more than purely coincidental.

Improvement in controlling the oral manifestations of LCH can be successfully achieved with conventional and surgical periodontal treatments, as reported by Klein and colleagues [20]. This could result in a substantial improvement of the clinical condition of patients with oral LCH and suggest the opportunity of stabilizing the periodontal conditions using standard procedures. In another case report [21], a 27-year old male with recurrent LCH and severe periodontal manifestations underwent comprehensive periodontal therapy and prosthetic rehabilitation. In this case, the periodontal condition remained stable for two years. Such findings indicate that a regular follow-up is crucial in controlling the periodontal manifestations of LCH. Nonetheless, only local treatment of the various manifestations of LCH may be not sufficient, as the presence of a related systemic condition must not be excluded. For this, a wide spectrum of systemic therapies are available, including chemotherapy, radiotherapy and corticosteroids [22].

The elective treatment of solitary bone lesions in the jaws is widely reported to be the surgical curettage. However, if the site is inaccessible to surgery then radiotherapy or chemotherapy are recommended [23]. Our patient has recently started radiotherapy and appointments have been scheduled for regular treatment and follow-up at the dental clinic. Therefore, an overall improvement of the condition cannot yet be determined.

In the present case, LCH passed unrecognized over the course of few years. Unfortunately, periodontal disease progressed rapidly, leading to the loss of most of the dentition. Delayed healing of soft tissues post-extraction was persistent. A close monitoring of the oral manifestations of disease could have allowed an early

diagnosis of LCH, preventing the rapid deterioration of the clinical conditions and possibly resulting in a better end point.

In everyday clinical practice, dentists and periodontists should be aware that rare systemic diseases such as LCH might lead to manifestations in the oral cavity as the first clinical sign. Patients would benefit of a correct multidisciplinary approach in the identification and clinical management of this rare entity.

Acknowledgements

The authors would like to thank Professor Anna Lavezzi for the technical support in the lab analysis. This study was partially supported by the University of Milan-Italy.

Disclosure of conflict of interest

None.

Address correspondence to: Dr. Farah Asa'ad, University of Milan, Dental Clinic, Via della Commenda, 10, I-20122 Milan, Italy. Tel: +39 342 1122 160; E-mail: farahasaad83@gmail.com

References

[1] Stocksclaeder M, Sucker C. Adult Langerhans cell histiocytosis. *Eur J Haematol* 2006; 76: 363-368.

[2] Chiong C, Jayachandra S, D. Eslick G, Al-Khawaja D, Casikar V. A Rare Case of Langerhans Cell Histiocytosis of the Skull in an Adult: a Systematic Review. *Rare Tumors* 2013; 5: e38.

[3] Vassallo R, Ryu JH, Schroeder DR, Decker PA. Clinical outcomes of pulmonary Langerhans'-cell histiocytosis in adults. *N Engl J Med* 2002; 346: 484-90.

[4] Friedman PJ, Liebow AA, Sokoloff J. Eosinophilic granuloma of lung. Clinical aspects of primary histiocytosis in the adult. *Medicine (Baltimore)* 1981; 60: 385-396.

[5] Lombardi T, Hauser C, Budtz-Joff J. Eosinophilic granuloma of lung. Clinical aspects of primordial pathological conditions. *J Oral Pathol Med* 1993; 22: 193-202.

[6] Hanapiah F, Yaacob H, Ghani KS, Hussin AS. Histiocytosis X: evidence for a genetic etiology. *J Nihon Univ Sch Dent* 1993; 35: 171-174.

[7] Merglová V, Hrušák D, Boudová L, Mukenšnabl P, Valentová E, Hostička L. Langerhans cell histiocytosis in childhood - review, symptoms in the oral cavity, differential diagnosis and report of two cases. *J Craniomaxillofac Surg* 2014; 42: 93-100.

[8] Vassallo R, Ryu JH, Colby TV, Hartman T, Limper AH. Pulmonary Langerhans a genetic etiolo-

gy. *J Nihon Univ Sch Dent* 2000; 342: 1969-78.

[9] Badalian-Very G, Vergilio JA, Degar BA, MacConaill LE, Brandner B, Calicchio ML, Kuo FC, Ligon AH, Stevenson KE, Kehoe SM, Garraway LA, Hahn WC, Meyerson M, Fleming MD, Rollins BJ. Recurrent BRAF mutations in Langerhans cell histiocytosis. *Blood* 2010; 116: 1919-1923.

[10] Berres ML, Merad M, Allen CE. Progress in understanding the pathogenesis of Langerhans cell histiocytosis: back to Histiocytosis X? *Br J Haematol* 2015; 169: 3-13.

[11] Favara BE, Feller AC, Pauli M, Jaffe ES, Weiss LM, Arico M, Bucsky P, Egeler RM, Elinder G, Gardner H, Gresik M, Henter JI, Imashuku S, Janka-Schaub G, Jaffe R, Ladisch S, Nezelof C, Pritchard J. Contemporary classification of histiocytic disorders. The WHO Committee On Histiocytic/Reticulum Cell Proliferations. Reclassification Working Group of the Histiocyte Society. *Med Pediatr Oncol* 1997; 29: 157-166.

[12] Milián MA, Bagán JV, Jiménez Y, Pérez A, Scully C, Antoniades D. Langerhans' cell histiocytosis restricted to the oral mucosa. *Oral Surg Oral Med Oral Pathol Oral Radiol Endod* 2001; 91: 76-79.

[13] Cantu MA, Lupo PJ, Bilgi M, Hicks MJ, Allen CE, McClain KL. Optimal therapy for adults with Langerhans cell histiocytosis bone lesions. *PLoS One* 2012; 7: e43257.

[14] Griffen AC. Periodontal problems in children and adolescents. In: Pinkham JR, Casamassimo PS, McTigue DJ, Fields HW, Novak AJ, editors. *Pediatric dentistry infancy through adolescence*. 4th edition. St. Louis: Elsevier Saunders; 2005. pp. 414-422.

[15] Madrigal-Martínez-Pereda C, Guerrero-Rodríguez V, Guisado-Moya B, Meniz-García C. Langerhans cell histiocytosis: literature review and descriptive analysis of oral manifestations. *Med Oral Patol Oral Cir Bucal* 2009; 14: E222-8.

[16] Fichter J, Doberauer C, Seegenschmiedt H. Langerhans Cell Histiocytosis in Adults: An Interdisciplinary Challenge. *Dtsch Arztebl* 2007; 104: A2347-53.

[17] Baumgartner I, von Hochstetter A, Baumert B, Luetolf U, Follath F. Langerhans'-cell histiocytosis in adults. *Med Pediatr Oncol* 1997; 28: 9-14.

[18] Tetradis S, Carranza FA, Fazio RC, Takei HH. Radiographic Aids in the Diagnosis of Periodontal Disease. In: Newman MG, Takei HH, Klokkevold PR, Carranza FA, editors. *Carranza's clinical periodontology*. St. Louis: WB Saunders; 2006. pp. 561-578.

[19] Henry RJ, Sweeney EA. Langerhans' cell histiocytosis: case reports and literature review. *Pediatr Dent* 1996; 18: 11-6.

Periodontal Langerhans cell histiocytosis

- [20] Klein F, Krigar D, Petzoldt D, Eickholz P. Periodontal manifestation of Langerhans' cell histiocytosis in a young man: case report with a 24-month follow-up. *Quintessence Int* 2006; 37: 175-182.
- [21] Rapp GE, Motta AC. Periodontal disease associated with Langerhans' cell histiocytosis: case report. *Braz Dent J* 2000; 11: 59-66.
- [22] Henter JJ, Tondini C, Pritchard J. Histiocyte disorders. *Crit Rev Oncol Hematol* 2004; 50: 157-174.
- [23] Hernández-Juyol M, Boj-Quesada JR, Gallego Melcon S. Oral manifestations of Langerhans cell histiocytosis. Case study of a two-year-old boy. *Med Oral* 2003; 8: 19-25.