

Case Report

Peroxidase-positive Auer bodies in plasma cells in multiple myeloma: a case report

Lin Zhu, Li An, Xiao-Yan Zhang, Xue-Rui Ren, Jing-Wen Song

Department of Hematology, People's Hospital of Xinjiang Uygur Autonomous Region, Urumqi 830001, China

Received June 30, 2015; Accepted October 10, 2015; Epub November 1, 2015; Published November 15, 2015

Abstract: Reports of clinical cases with Auer bodies in the plasma cells in multiple myeloma (MM) are rare; however, most of those reported contain peroxidase (POX)-negative Auer bodies rather than the POX-positive Auer bodies observed in myeloid progenitors, indicating differences in their chemical properties. Furthermore, the cases with POX-positive Auer bodies similar to those observed in myeloid cells are extremely rare in non-myeloid cells. Here, we report the clinical features, laboratory investigations, diagnosis and treatment of a case of MM with POX-positive Auer bodies in plasma cells and review related the literature to advance the prognostic evaluation, diagnosis and treatment of similar cases.

Keywords: Multiple myeloma, auer body, plasma cell, peroxidase

Introduction

Auer bodies were discovered in 1906 by the American physician John Auer during his investigations of myeloid leukemia [1, 2]. These structures are mainly present in myeloid progenitors and serve as a diagnostic morphological feature for acute myeloid leukemia (AML). Auer bodies are rarely reported in non-myeloid cells, although several cases have revealed their existence in multiple myeloma (MM). In contrast to the peroxidase (POX)-positive Auer bodies observed in myeloid progenitors, the Auer bodies in MM are often POX-negative, indicating the distinct chemical properties of these cells. Moreover, POX-positive Auer bodies similar to those observed in non-myeloid cells are exceedingly rare in myeloid cells. No studies focusing on this type of Auer body have been reported to date; thus, the etiologies and implications remain unclear. Here, we report the clinical features, bone marrow cell morphology, enzymatic histochemical staining, chromosomal changes, diagnosis and treatment of a patient with MM exhibiting plasma cells containing Auer bodies.

Case presentation

A 65-year-old man visited the outpatient department of our hospital with the chief complaint of "recurrent lower back pain for 4

months and fever for more than 20 days". In April 2014, he presented bilateral lower back distending pain, without fever, frequent micturition, urodynia, hematuria or proteinuria. He then visited his local hospital, where routine urine tests indicated positive proteinuria and elevated creatinine levels. Subsequently, the patient was diagnosed with "nephrotic syndrome" and administered oral Bailing capsules for symptom relief; however, his lower back pain recurred at intervals. In August 2014, the patient presented with coughing, expectoration of white phlegm (approximately 150 mL/d) and fever (reaching 40°C), which were not associated with abdominal pain, diarrhea, bone pain, arthralgia, or other symptoms. He returned to the local hospital, where he was diagnosed with "upper respiratory tract infection (URTI)" and treated with cephalosporins, which lowered his body temperature. In addition, the patient presented with elevated blood IgG that and was referred to the Department of Hematology of our hospital. His medical history was unremarkable with no infectious diseases (e.g., tuberculosis, hepatitis), chronic diseases (e.g., diabetes mellitus, hypertension, coronary heart disease), trauma, surgery, or blood transfusion. Physical examination on admission showed normal vital signs but moderate anemia. Neither yellowish skin/mucosae nor skin rashes, petechiae, and ecchymoses were observed.

A case report of peroxidase-positive Auer bodies

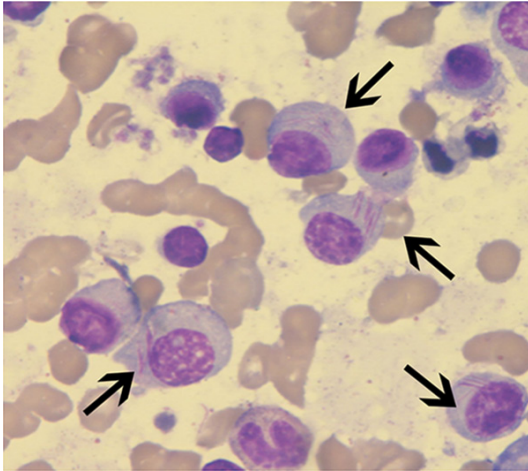


Figure 1. Bone marrow smear. Plasma cells containing Auer bodies. Wright-Giemsa staining (magnification, $\times 1,000$).

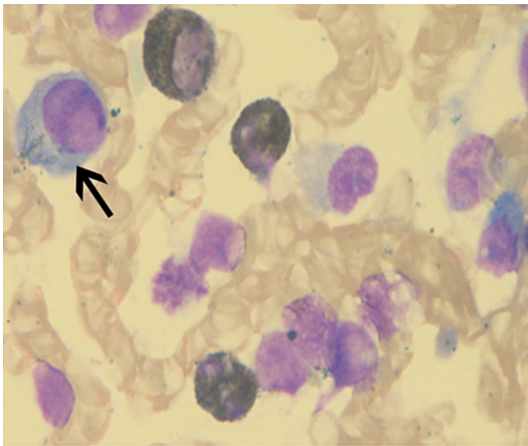


Figure 2. Bone marrow smear. Auer bodies in plasma cells. Positive POX-staining (magnification, $\times 1,000$).

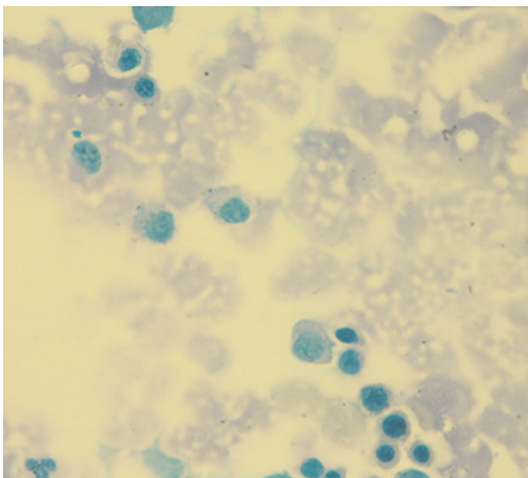


Figure 3. Bone marrow smear. Negative acid phosphatase staining (magnification, $\times 1,000$).

Palpation did not indicate swelling of the systemic superficial lymph nodes or sternal tenderness. Motions of the major joints were normal and pitting edema of the lower limbs was not observed. Examinations of the lungs, heart and abdomen were unremarkable.

Laboratory investigations and imaging examinations

Routine tests

Blood: White blood cell (WBC) count $3.36 \times 10^9/L$, lymphocytes 51.5%, hemoglobin (Hb) 86 g/L, platelet (PLT) count $153 \times 10^9/L$; Blood biochemistry: Albumin 31.79 g/L, creatinine 105.59 $\mu\text{mol/L}$, modified serum calcium 2.37 mmol/L; Humoral immunity: IgG 49.8 g/L, IgA 0.28 g/L, IgM 0.30 g/L, κ light chains 60.7 g/L, λ light chains 1.02 g/L, β_2 -microglobulin 6.70 mg/L; Blood and urine immunofixation electrophoresis: positive IgG κ light chain. Quantification of 24-hour urine κ light chains: 14.85 g; Epstein-Barr virus (EBV): Positive anti-EBV capsid antigen (CA) IgG antibody, anti-EBV nuclear antigen (NA)-1 IgG antibody and high-affinity anti-EBV IgG antibody; Nested virus: Positive cytomegalovirus IgG antibody, herpes simplex virus 1/2 IgG antibody and rubella virus IgG antibody.

Bone marrow and peripheral blood smears (Wright-Giemsa staining)

Bone marrow nucleated cells were markedly active, with a myeloid: erythroid (M:E) ratio of 0.45:1. In smears, proliferating plasma cells were predominantly observed, accounting for 60.5% of the total cells, including 15% of plasma cells containing Auer bodies. Most plasma cells with Auer bodies had nuclei located at one side of the cell and rough chromatin. Rod/fine needle-like Auer bodies were seen in the cytoplasm, most of which were located near to the nuclei with some appearing as purple/red bundles. For binuclear plasma cells, 1-6 Auer bodies frequently appeared between the two nuclei (**Figure 1**). Myeloid hypoplasia was observed in 9% and erythroid hyperplasia in 20% of bone marrow cells. Mature erythrocytes were observed in a typical rouleau-like arrangement. Lymphocytes accounted for 10% of the total cells. The 93 megakaryocytes found on the smears were dominated by granular megakaryocytes. Platelets were distributed in clusters. Plasma cells accounted for 2% of the total cells in peripheral blood smears.

A case report of peroxidase-positive Auer bodies

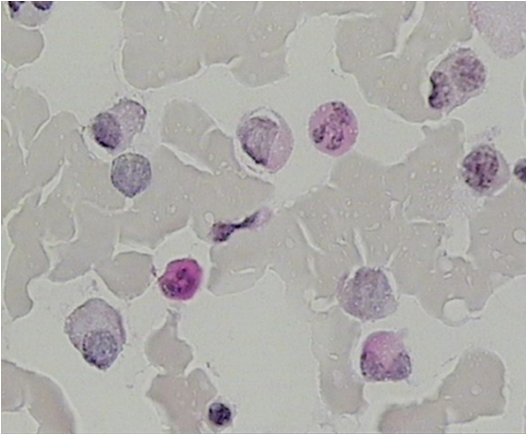


Figure 4. Bone marrow smear. Negative periodic acid-Schiff staining (magnification, $\times 1,000$).

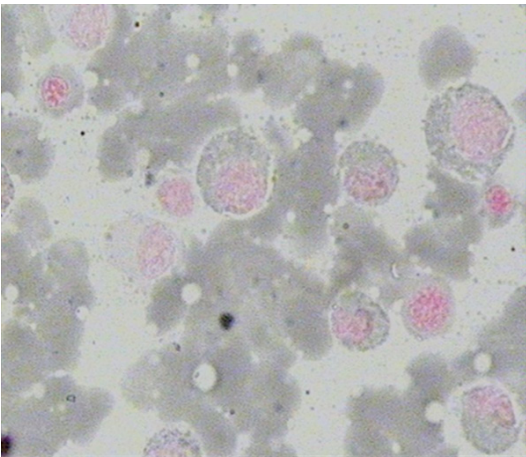


Figure 5. Bone marrow smear. Negative Sudan black B staining (magnification, $\times 1,000$).

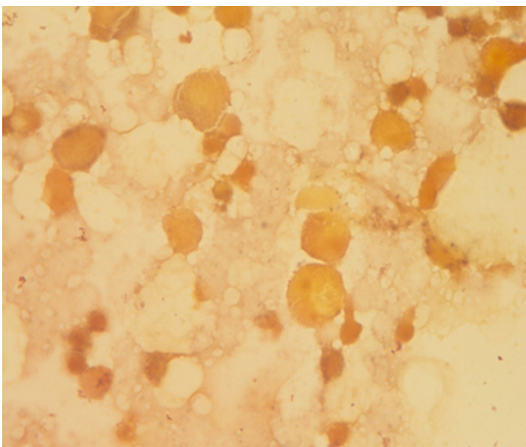


Figure 6. Bone marrow smear. Negative α -naphthyl acetate esterase staining (magnification, $\times 1,000$).

Enzymatic histochemical staining of bone marrow cells

The POX-staining of Auer bodies was positive (see **Figure 2**), whereas staining with Sudan black B (SBB), periodic acid-Schiff (PAS), α -naphthyl acetate esterase (α -NAE) and acid phosphatase (ACP) was negative (**Figures 3-6**).

Bone marrow biopsy and immunohistochemical staining

The ratio of hematopoietic tissue to adipose tissue was 0.5:1. The M:E ratio was 1:2. Plasmacytoid cells were diffusely distributed between trabeculae. Immunohistochemical staining results were as follows: CD138 (+), CD38 (+), CD20 (+), CD3 (-), κ light chain (+), λ light chain (-), MPO (+, focally distributed), and Mum-1 (+, diffusely distributed).

Bone marrow flow cytometric immunophenotyping

Abnormal plasma cell clones accounted for 46% of the total and expressed CD38, CD138, CD56 and κ light chain.

Karyotyping and fluorescence in situ hybridization (FISH) analysis

The karyotype was 46, XY, N [20]. FISH analysis revealed the positive rate of IgH gene rearrangement was 21%, with negative 1q21 amplification, RB1 deletion, D13S319 deletion and p53 deletion. Further analysis revealed the positive rate of t (11; 14) was 27%, whereas t (4; 14), t (14; 16) and t (14; 20) were negative.

Chest computed tomography (CT) imaging

Patchy and streaky shadows were observed on the inferior lobes of both lungs, indicating inflammation. Abdominal color Doppler ultrasonography showed a solid space-occupying lesion on the right lobe of the liver, possibly due to hemangioma. The gallbladder wall was rough but the spleen was not enlarged. No space-occupying lesions were observed on the pancreas or kidneys.

Positron emission tomography-computed tomography (PET-CT)

Diffusely increased 2-[18F] fluoro-2-deoxy-D-glucose uptake was observed in the bones of all

A case report of peroxidase-positive Auer bodies

four limbs, sternum, vertebrae, pelvis and bilateral clavicles, scapulae and ribs. CT imaging showed shadows indicative of increased bone density in the aforementioned bones, osteolytic bone destruction in right iliac bone and hypermetabolism in the spleen, consistent with MM.

Diagnosis and treatment

According to Chinese Guidelines on the Management and Diagnosis of Multiple Myeloma (2013 revision) [3], the patient met all three diagnostic criteria of symptomatic myeloma and was therefore diagnosed with MM (IgG κ light chain type) and classified as Stage IIIA according to the Durie-Salmon staging system and Stage III according to the International Staging System (ISS). Based on the positive IgH gene rearrangement identified in FISH analysis and the positive rate of t(11; 14) at 27%, the patient was classified as standard risk according to the Mayo Stratification of Myeloma and Risk-adapted Therapy (mSMART) model classification systems [4]. After two courses of VTD chemotherapy (velcade 1.3 mg/m² on day (d) 1, 4, 8, 11; thalidomide 100 mg/qnpo; dexamethasone 20 mg po on d 1-2, 4-5, 8-9, 11-12), the patient's lower back pain was relieved. Re-examination indicated that Hb was not markedly raised; IgG was 40.8 g/L, κ light chain 56.7 g/L and β 2-microglobulin 8.0073 mg/L. Blood immunofixation electrophoresis still indicated positive IgG κ light chain and quantification of 24-hour urine κ light chain was 13.4 g. The patient responded poorly to treatment and did not obtain partial remission (PR) according to The European Group for Blood and Marrow Transplantation (EBMT) criteria and the International Myeloma Working Group (IMWG) criteria [4]. Therefore, pegylated liposomal doxorubicin was added to the original chemotherapy regimen (to form PATD chemotherapy). After two courses of treatment, re-examination of bone marrow smears indicated plasma cells accounted for 28%, including approximately 5% of plasma cells containing Auer body. Hb was 115 g/L, IgG was 22.3 g/L and κ light chain was 20.6 g/L. Blood immunofixation electrophoresis showed positive IgG κ light chain, while quantification of 24-hour urine κ light chain was 0.18 g, meeting the criteria for PR. As a result, the patient was discharged and has been followed up subsequently.

Discussion

Most Auer bodies appearing in myeloid leukemia show positive POX-staining [5]. However, the mechanism by which Auer bodies are generated remains to be fully elucidated. The most commonly held explanation is that under pathological conditions, azurophilic granules fuse into a rod-like or other-shaped purple/red mass known as an Auer body. Non-myeloid cells rarely have Auer bodies. The existence of Auer body in myeloma cells was first reported bySteinmannin 1940 [6]. In the last decade, rare observations of Auer bodies in non-myeloid cells have been described, with most reported in MM. A previous study [7] indicated the presence of Auer bodies in lymphocytic malignant tumors including MM, B-cell acute lymphoblastic leukemia, and chronic lymphocytic leukemia/small lymphocytic lymphoma. These malignancies exhibit negative POX-staining and the Auer bodies are distinct from those observed in AML, which have diagnostic and differential values, indicating different in their chemical properties. The Auer bodies in some patients have been confirmed to be immunoglobulin deposits by electron microscopy and immunohistochemistry [8], although in other patients, Auer bodies show positive β -glucuronidase, α -NAE and ACP staining that indicates a lysosomal origin, with the aggregation of cytoplasmic azurophilic granules. Li et al. [9] reported two cases with partial negative and partial weakly positive SBB staining, indicating that the Auer bodies in plasma cells contain a small amount of lipid. In our case, the MM patient showed POX-positive Auer bodies in plasma cells, which is inconsistent with previous related reports. Furthermore, SBB, α -NAE and ACP staining were negative, which is not completely consistent with related cases. Thus, it can be speculated that the Auer bodies in the plasma cells of the patient described here are likely to originate from the deposition of azurophilic granules. Since no MM cases with POX-positive Auer bodies in plasma cells have been reported previously, it remains unclear how these Auer bodies are generated and what chemical properties they possess. Moreover, how these Auer bodies correlate with the POX-positive Auer bodies present in myeloid leukemia cells in terms of clinical implications and prognosis remains to be determined.

A case report of peroxidase-positive Auer bodies

The etiologies of MM are still unclear. Currently, most cases of MM are reported to be correlated with EBV, a tumorigenic DNA herpesvirus that can infect B lymphocytes, leading to immortalization [10]. Furthermore, EBV also promotes the secretion of viral IL-6 by B lymphocytes and results in the transformation of B lymphocytes to malignant plasma cells in the presence of oncogenes [11]. Our patient tested positive for anti-EBV CA IgG antibodies, anti-EBV NA-1 IgG antibodies and high-affinity anti-EBV IgG antibodies, indicating a history of EBV infection. Inclusion bodies are a proteinic pathological structure, formed mainly in host cells during the proliferation of some viruses. Under light microscopy inclusion bodies appear circular, orbicular-ovate or undetermined in shape. In general, inclusion bodies are formed by the aggregation of integrated virus particles or non-assembled virus subunits in the cytoplasm (e.g., smallpox virus), nucleus (herpes virus) or both (measles virus). In addition to EBV, our patient was also complicated by distant prior exposure to cytomegalovirus, herpes simplex virus types 1 and 2 and rubella virus. The Auer bodies in the plasma cells of the bone marrow showed distinct shapes and the histochemical staining was negative, with the exception of POX. Rare cases have been reported and few related studies have been conducted. Consequently, the relationship between Auer body formation in plasma cells and virus inclusion remains to be established.

The 14q⁺ anomaly, which is the most common aberration in MM, is observed in at least 90% of MM cell lines and 74% of MM patients. The switch region of the IgH gene at 14q32 is frequently involved in the production of more than 10 types of anomalies, among which genetic translocations at 11q13 (Cyclin D1), 4p16.3 (FGFR3, MMSET), 16q23 (c-Maf), 8q24 (c-Myc) and 6p21 (Cyclin D3) are common. In our case, the IgH gene rearrangement was positive and further investigations revealed the positive rate of t(11; 14) at 27%. Golovleva et al. [12] reported c-Myc oncogene amplification in the initial cells of three AML cases with abnormal inclusion and concluded that the c-Myc oncogene may be involved in the formation of abnormal inclusion particles. The c-Myc oncogene is located at 8q24; however, chromosome and FISH analyses in our patient did not indicate 8q24 abnormalities and the Auer bodies appeared only in plasma cells. Thus, the symp-

toms of our patient cannot be attributed to the c-Myc oncogene. Moreover, the patient was t(11; 14) positive in FISH analysis and the risk stratification was standard. Since the patient responded poorly to two courses of VTD chemotherapy regimen containing velcade, pegylated liposomal doxorubicin was added to the original chemotherapy regimen (to form PATD chemotherapy) and PR was achieved after a further two courses of treatment.

Conclusions

Auer bodies, a specific diagnostic morphological marker for AML, are frequently present in myeloid leukemia cells and shows positive POX-staining. These structures appear occasionally in myeloma cells and show negative POX-staining. The POX-positive Auer bodies in the plasma cells of our patient are significantly different in origin and chemical properties from POX-negative Auer bodies and have not been reported previously. Thus, evaluation of the clinical value of POX-positive Auer bodies in the diagnosis, treatment and prognostic evaluation of MM is warranted.

Disclosure of conflict of interest

None.

Address correspondence to: Lin Zhu, Department of Hematology, People's Hospital of Xinjiang Uygur Autonomous Region, Urumqi 830001, China. Tel: +86-13659917193; Fax: +86-021-64085875; E-mail: bestgirl00@163.com

References

- [1] Freeman JA. The ultrastructure and genesis of Auer bodies. *Blood* 1960; 15: 449-465.
- [2] Freeman JA. Origin of Auer bodies. *Blood* 1966; 27: 499-510.
- [3] Blood Physicians Association of Chinese Medical Doctor Association, Chinese Hematologic Society of Chinese Medical Association, Chinese Multiple Myeloma Working Group. Chinese Guidelines on the Management and Diagnosis of Multiple Myeloma (2013 revision). *Chin J Intern Med* 2013; 52: 791- 795.
- [4] Mikhael JR, Dingli D, Roy V, Reeder CB, Buadi FK, Hayman SR, Dispenzieri A, Fonseca R, Sher T, Kyle RA, Lin Y, Russell SJ, Kumar S, Bergsagel PL, Zeldenrust SR, Leung N, Drake MT, Kapoor P, Ansell SM, Witzig TE, Lust JA, Dalton RJ, Gertz MA, Stewart AK, Rajkumar SV, Chanan-Khan A and Lacy MQ. Management of

A case report of peroxidase-positive Auer bodies

- newly diagnosed symptomatic multiple myeloma: updated Mayo Stratification of Myeloma and Risk-Adapted Therapy (mSMART) consensus guidelines 2013. *Mayo Clin Proc* 2013; 88: 360-376.
- [5] Bai Q, Guo B and Li S. Analysis of Auer bodies in acute non-lymphocytic leukemia: A report of 132 cases. *Chin J Med Officer* 2010; 4: 657-658.
- [6] Kanoh T, Nomura S and Yamamoto A. Unique crystalline inclusions in monoclonal plasma cells (author's transl). *Nihon Ketsueki Gakkai Zasshi* 1979; 42: 421-427.
- [7] Hristov AC, Saladino A, Nava VE and Gocke CD. Auer rod-like inclusions in a low-grade B-cell leukemia. *Ann Diagn Pathol* 2010; 14: 292-295.
- [8] Juneja HS, Rajaraman S, Alperin JB and Bainton DF. Auer rod-like inclusions in prolymphocytic leukemia. *Acta Haematol* 1987; 77: 115-119.
- [9] Li Y, Shi M and Liu Y. Auer rod-like inclusions in multiple myeloma: morphology and cytochemical studies. *Chin J Lab Med* 2010; 10: 972-973.
- [10] Rezk SA and Weiss LM. Epstein-Barr virus-associated lymphoproliferative disorders. *Hum Pathol* 2007; 38: 1293-1304.
- [11] Klein E, Kis LL and Klein G. Epstein-Barr virus infection in humans: from harmless to life endangering virus-lymphocyte interactions. *Oncogene* 2007; 26: 1297-1305.
- [12] Golovleva I, Hultdin J, Roos G, Wahlin A and Holmgren G. Co-existence of pseudo-Chediak-Higashi anomaly and double minutes containing C-MYC oncogene in three patients with AML M2. *Leukemia* 2002; 16: 152-154.