

Original Article

Immunohistochemistry is highly sensitive and specific for detecting the BRAF V600E mutation in papillary thyroid carcinoma

Jian Sun*, Jing Zhang*, Junliang Lu, Jie Gao, Tao Lu, Xinyu Ren, Huanli Duan, Zhiyong Liang

*Department of Pathology, Peking Union Medical College Hospital, Chinese Academy of Medical Sciences and Peking Union Medical College, Beijing 100730, People's Republic of China. *Equal contributors.*

Received September 6, 2015; Accepted October 21, 2015; Epub November 1, 2015; Published November 15, 2015

Abstract: The V600E mutation in the B-type Raf kinase (BRAF) gene is a common genetic change in cases of papillary thyroid carcinoma (PTC) that appears to play a key role in the development and progression of this disease. We sought to assess the sensitivity and specificity of immunohistochemical detection of this mutation with a V600E mutated BRAF antibody in a Chinese PTC cohort. In this study, we used fully automated immunohistochemistry (IHC) assay with a BRAF V600E (VE1) mouse monoclonal primary antibody to screen for the BRAF V600E mutation in 556 cases of PTC. Moreover, to verify the IHC staining results, real-time PCR was applied to detect this mutation in the same patient cohort. Among the 556 cases in the examined primary PTC cohort, 414 (74.5%) cases and 419 (75.4%) cases were positive for the BRAF V600E mutation by IHC staining and by real-time PCR, respectively. The real-time PCR results indicated that the sensitivity and specificity of IHC staining for the BRAF V600E mutation were 98.8% and 100%, respectively. The BRAF V600E mutation was common among Chinese patients with primary PTC, and was strongly correlated with older patient age and the conventional subtype of PTC but was not associated with parameters of clinicopathological aggressiveness. The fully automated IHC is a reliable technique that can serve as an alternative to molecular biological approaches for the routine detection of the BRAF V600E mutation in PTC patients.

Keywords: BRAF V600E, mutation, immunohistochemistry, papillary thyroid carcinoma

Introduction

Papillary thyroid carcinoma (PTC) is the most common endocrine malignancy, and its incidence is rapidly increasing worldwide [1]. To date, several genetic changes have been associated with PTC. The most common such change is the B-type Raf kinase (BRAF) V600E mutation. This mutation, a substitution in which valine is replaced by glutamic acid in codon 600 (V600E) of BRAF, results in the activation of the mitogen-activated protein kinase (MAPK) pathway, prompting cells to grow, survive and invade [2, 3].

BRAF V600E mutations are detected in 20% to 80% of sporadic PTCs, with a higher prevalence of these mutations in conventional PTCs than in follicular variants of this disease [4]. In several clinical studies of PTC, the BRAF V600E mutation was associated with advanced tumor

stage and a higher risk of recurrence; thus, BRAF V600E mutation analysis has been suggested as an important prognostic parameter [5-7]. However, several studies have found no associations between the BRAF V600E mutation and high-risk pathological characteristics, whereas other studies have reported partial associations [8-10].

Many different methods for BRAF V600E mutation analyses have been developed, including single-strand conformation polymorphism, gene sequencing (direct DNA sequencing or pyrosequencing), and mutation-specific PCR. However, the clinical applicability of these methods is limited because they are expensive and time-consuming. Recently, several studies have demonstrated that a BRAF V600E mutation-specific monoclonal antibody (clone VE1) can detect the BRAF V600E-mutated BRAF protein in various carcinomas [11-13].

IHC for detecting of the BRAF V600E mutation in PTC

The objectives of the present study were to evaluate the performance of an automated immunohistochemistry (IHC) assay relative to real-time PCR with respect to screening for the BRAF V600E mutation in a large cohort of Chinese PTC patients and to evaluate the relationships between BRAF V600E mutation and various clinicopathological features of PTC in this cohort.

Materials and methods

Case selection

In this study, 595 consecutive patients with primary PTC who underwent radical surgical resection at the Peking Union Medical College Hospital between January 2010 and December 2012 were clinicopathologically reviewed.

The following exclusion criteria were applied: treatment less extensive than a subtotal thyroidectomy; a lack of available paraffin blocks containing pathological specimens; and insufficient clinical information.

The final population for the clinicopathological analyses of this study consisted of 556 patients (163 men and 393 women, with patient ages ranging from 11 to 73 years). Tissue samples from all cases had been fixed in formalin and embedded in paraffin. Clinicopathological information was obtained by reviewing patients' medical records in detail to note age; sex (male or female); tumor size, monofocality or multifocality, and unilaterality or bilaterality; date of surgery; lymph node metastasis; distant metastasis; histological findings; time of postoperative recurrence; and tumor-node-metastasis (TNM) stage. TNM stages were determined based on the 7th edition of the American Joint Committee on Cancer (AJCC)/Union for International Cancer Control (UICC) TNM classification system [14]. Clinical staging information was available for all 556 patients, and adequate follow-up information was obtained for 373 patients. The follow-up periods ranged from 2 to 50 months, with a mean of 28.6 months. This study was conducted with the approval of the Peking Union Medical College Hospital's ethics committee, and informed consent was obtained from all patients.

Immunohistochemistry

BRAF V600E IHC was performed using the anti-BRAF V600E (VE1) antibody on the Benchmark

XT platform (Ventana Medical Systems). The specific visualization of V600E-mutated BRAF protein was accomplished using the Opti-View DAB IHC Detection Kit (Ventana Medical Systems). Pre-validated BRAF V600E positive and negative PTC specimens were used as positive and negative controls, respectively. The immunoreactivity of V600E-mutated BRAF protein was evaluated based on the cytoplasmic staining of tumor cells. In accordance with the approaches utilized by prior studies [10-12] and our examinations, staining intensities were recorded as weak, moderate, or strong. Faint diffuse staining, any type of isolated nuclear staining, weak staining of single interspersed cells, and staining of monocytes/macrophages were scored as negative. Moderate or strong staining was scored as positive.

DNA extraction

DNA from collected tissue samples was extracted with the QIAGEN QIAamp DNA FFPE Tissue Kit (56404, QIAGEN) in accordance with the manufacturer's protocols. DNA from each sample was eluted in 50 μ l of ATE (included in the kit). Absorbance was measured using a spectrophotometer, and DNA samples were diluted to approximately 2-3 ng/ μ l with distilled water.

Detection of the BRAF V600E mutation

We detected the BRAF V600E mutation using the CFDA-approved human BRAF V600E ARMS-PCR kit (Amoy Diagnostics Co. Ltd., Xiamen, China). The quality of the extracted DNA was evaluated by amplifying a housekeeping gene in the kit's HEX channel in accordance with the manufacturer's directions. The amplification protocol involved 47 cycles (1 cycle of 95°C for 5 min; 15 cycles of 95°C for 25 s, 64°C for 20 s, and 72°C for 20 s; and 31 cycles of 93°C for 25 s, 60°C for 35 s, and 72°C for 20 s). FAM and HEX signals were collected during the third stage. The run files were analyzed and interpreted as specified in the manufacturer's manual.

Statistical analysis

Individual information and baseline characteristics were summarized using descriptive statistics. Univariate analyses were performed for qualitative variables, and chi-square tests and Fisher's exact test were applied as appropriate to draw comparisons. Data analysis was per-

IHC for detecting of the BRAF V600E mutation in PTC

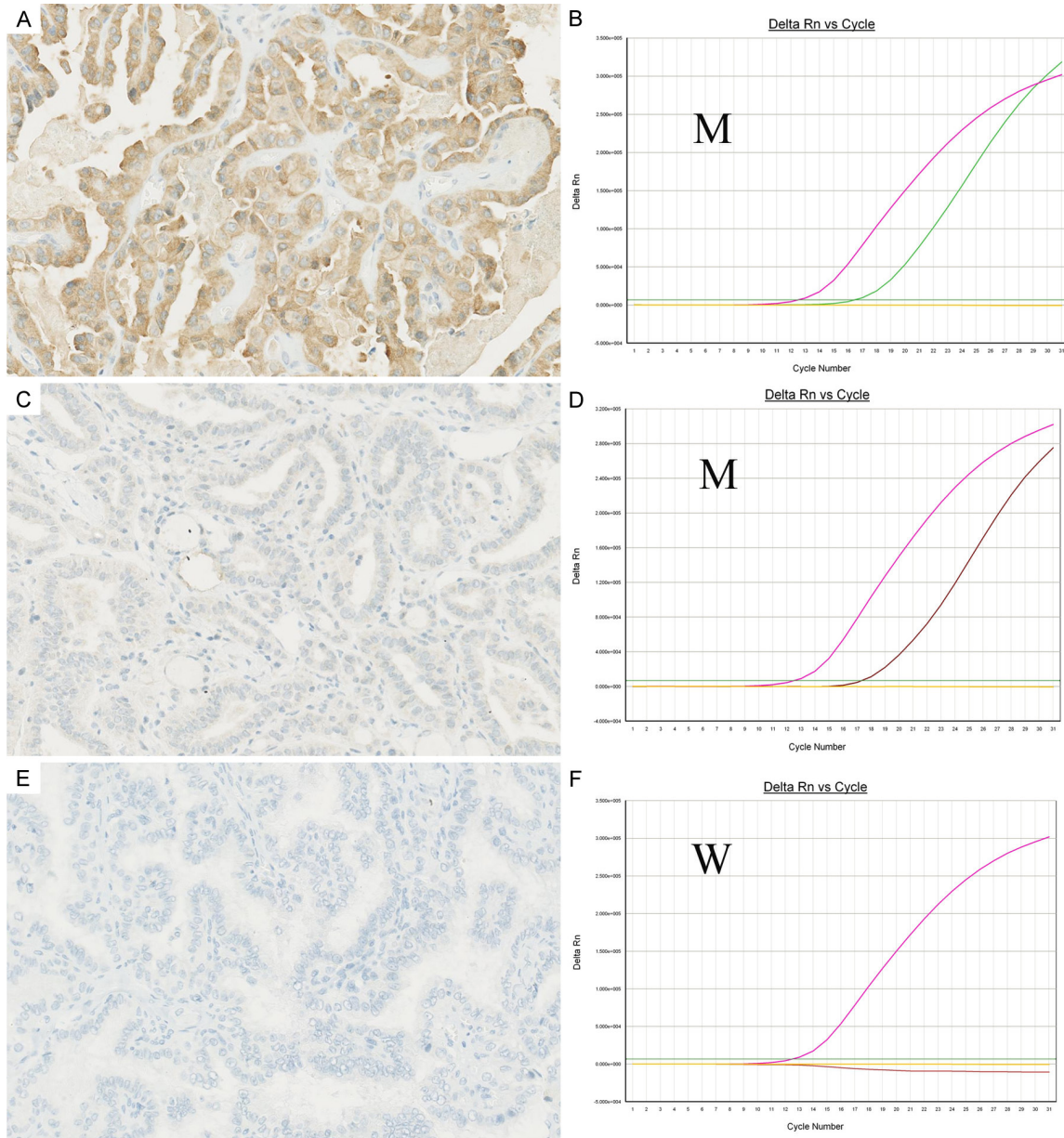


Figure 1. BRAF V600E mutation detection with immunohistochemistry and real-time PCR in papillary thyroid carcinoma. A, B. Case #2: A. Strong cytoplasmic immunostaining with BRAF V600E (VE1) antibody; B. This case was also mutation-positive by real-time PCR ('M' denoted the amplification curve for BRAF V600E mutation). C, D. Case # 346: C. This tumor showed very weak staining with BRAF V600E (VE1) antibody; D. BRAF V600E mutation was detected by real-time PCR ('M' denoted the amplification curve for BRAF V600E mutation). E, F. Case # 65: E. This tumor was immuno-negative for BRAF V600E (VE1) antibody; F. BRAF V600E mutation was not detected by real-time PCR ('W' curve indicated that no BRAF V600E sequence was amplified).

formed using SPSS, version 17; $P < 0.05$ was regarded as statistically significant.

Results

Immunohistochemistry of mutant-specific BRAF and molecular analyses

The Ventana IHC assay was performed to screen for the BRAF V600E mutation in the

556 PTC patients. Among the 556 cases, 414 (74.5%) cases had samples with IHC BRAF V600E expression, and 142 (25.5%) cases had samples with negative staining (Figure 1A, 1C, 1E).

Using real-time PCR, the BRAF V600E mutation was detected in 419 (75.4%) of the 556 examined primary PTC patients (Figure 1B, 1D, 1F).

IHC for detecting of the BRAF V600E mutation in PTC

Table 1. Correlation of BRAF V600E mutation detection between immunohistochemistry and real-time PCR in papillary thyroid carcinoma

		Real-time PCR		Total
		Positive	Negative	
IHC	positive	414	0	414 (75.5%)
	negative	5	137	142 (25.5%)
Total		419 (75.4%)	137 (24.6%)	556 (100%)

Comparisons of immunohistochemistry findings and molecular analyses

As indicated in **Table 1**, 414 and 419 patients were positive for the BRAF V600E mutation by the Ventana IHC assay and by real-time PCR, respectively. Among the 556 examined patients, 5 patients were negative for the BRAF V600E mutation by the Ventana IHC assay (which resulted in 3 samples with weak staining and 2 samples without staining) but positive by real-time PCR (**Figure 1C, 1D**). Therefore, relative to the results obtained for the detection of the BRAF V600E mutation by real-time PCR, the sensitivity and specificity of the BRAF Ventana IHC assay for detecting this mutation were 98.8% (414/419) and 100% (137/137), respectively.

Correlations between BRAF V600E mutation and clinicopathological parameters

The study results presented in **Table 2** summarize the relationships between BRAF V600E mutation and various clinicopathological features. The 556 examined patients ranged from 11 to 73 years of age (mean, 41.5 years; median, 41 years). Patients who had BRAF V600E mutation were significantly older than patients without mutation (42.8 vs. 37.5 years, $P < 0.001$). No significant relationships were observed between BRAF V600E mutation and either gender ($P = 0.368$) or tumor size ($P = 0.161$), multifocality ($P = 0.172$) or bilaterality ($P = 0.321$). Furthermore, BRAF V600E mutation was not significantly correlated with clinicopathological parameters of aggressiveness, such as lymph node metastasis ($P = 0.958$), recurrence ($P = 0.746$), or advanced TNM stage ($P = 0.136$). Distant metastases were found in 3 patients with PTC, although such metastases were not significantly associated with BRAF V600E mutation.

Among the 556 PTC tumors, 350 (62.9%), 148 (26.6%), 48 (8.6%) and 10 (1.8%) tumors were

classified as conventional, follicular, solid, and other rare subtypes, respectively. The frequency of BRAF V600E mutation tumors was higher among patients with solid tumors than among patients with follicular subtype. Rare subtypes were found in 10 patients from our sample, including 5 patients with a tall cell subtype and 5 patients with a disseminated sclerosing variant of PTC. The BRAF V600E mutation was present in 80% of patients with the tall cell subtype but none of the patients with a disseminated sclerosing variant of PTC.

Discussion

In this study, we performed a fully automated IHC analysis in which the Ventana BRAF V600E (VE1) mouse monoclonal primary antibody was used to detect the mutated BRAF V600E protein in Chinese patients with primary PTC. We then compared the IHC findings with molecular assay results. The sensitivity and specificity of IHC staining for the BRAF V600E mutation were 98.8% and 100%, respectively.

It has been well established that IHC is a rapid, easily applied, and economic alternative to current techniques. Several studies have previously evaluated the performance of the VE1 antibody in cases of PTC [11-13, 15-18]. However, in most of these studies, direct sequencing was used as the standard reference for BRAF genotyping. In such settings, VE1-based analyses would inevitably produce a relatively high number of false positive results relative to the reference findings generated by direct sequencing. Our study used real-time PCR results as a reference in analyses of a large cohort of Chinese patients with primary PTC. The sensitivity and specificity of IHC staining for BRAF V600E mutation were 98.8% and 100%, respectively. The high sensitivity and specificity of the VE1 antibody for the BRAF V600E mutation demonstrated that IHC would be a useful tool for screening for this mutation among PTC patients. However, in several cases, we observed ambiguous (weak or focal) immunostaining that could cause uncertainty in diagnostic settings. In such cases, additional genetic analysis may be required to clarify patients' BRAF statuses [11, 17].

A recent meta-analysis reported that the prevalence of the BRAF V600E mutation among PTC patients ranged from 27% to 90%, with an aver-

IHC for detecting of the BRAF V600E mutation in PTC

Table 2. Clinicopathologic parameters and BRAF V600E mutation

Parameters	Total	BRAF (V600E) mutation	BRAF (V600E) without mutation	p Value
Number of patients	556	419 (75.4%)	137 (24.6%)	
Gender				
F	393	292	101	0.368
M	163	127	36	
Age (years), mean ± SD	41.49 (11-73)	42.78±11.4	37.53±12.8	<0.001
Size (mm), mean ± SD	11.56 (1-45)	11.31±7.1	12.32±8.1	0.161
Monofocality	391	301	90	0.172
Multifocality	165	118	47	
Unilateral	387	287	100	0.321
Bilateral	169	132	37	
Variants types				
Conventional	350	277 (79.1%)	73 (20.9%)	0.001
Follicular	148	97 (65.5%)	51 (34.5%)	
Solid	48	36 (75.0%)	12 (25.0%)	
Others	10	4 (40.0%)	6 (60.0%)	
LN metastasis				
Yes	413	311	102	0.958
No	143	108	35	
TNM				
I-II	407	300	107	0.136
III-IV	149	119	30	
Recurrence				
Yes	59	41	18	0.746
No	497	335	162	

age prevalence of 56.3% [9]. Our results revealed that this mutation was highly prevalent among the examined PTC patients; this finding was consistent with the results of prior studies [9, 19]. The current investigation also demonstrated that BRAF V600E mutation was more common among patients with solid tumor subtype than among patients with follicular PTC [18]. With respect to other rare PTC subtypes, the BRAF V600E mutation was extremely prevalent among patients with the tall cell subtype but was not detected among patients with disseminated sclerosing variants of PTC. However, in this study, there were few patients with these two forms of PTC.

Several studies have shown that BRAF mutations are associated with patient age [11, 20]. In accordance with these findings, we found BRAF V600E mutation was strongly associated with patient age, with a higher prevalence of BRAF V600E among elderly patients.

A prior comprehensive, multicentre study demonstrated that the presence of the BRAF V600E mutation was strongly associated with poor clinicopathological outcomes for PTC, including extrathyroidal extension, advanced TNM stage, lymph node metastasis, multifocality and increased recurrence [9]. However, Trovisco et al. reported that the types and prevalences of BRAF mutations are closely associated with PTC histotype and patient age but not tumor aggressiveness [21]. Sancisi et al. demonstrated that in cases of PTC, BRAF mutation is not associated with the development of distant metastases or with a fatal outcome [22]. Thus, debate continues regarding whether the BRAF V600E mutation is associated with more aggressive clinicopathological features in PTC cases. In our study, BRAF mutation was associated with older patient age and a conventional tumor subtype. Our

results, which agree with certain prior findings, suggest that the BRAF V600E mutation may be unrelated to biological aggressiveness, including lymph node metastasis, advanced TNM stage and recurrence.

In conclusion, we demonstrated that the BRAF V600E mutation is common among patients with primary PTC. The BRAF V600E mutation was strongly correlated with older patient age and the conventional subtype of PTC but not with parameters of clinicopathological aggressiveness. Our study demonstrates that fully automated IHC assay is a reliable method for detecting the BRAF V600E mutation in PTC and can be used as an alternative to molecular biological approaches for the routine detection of this mutation in PTC patients.

Disclosure of conflict of interest

None.

IHC for detecting of the BRAF V600E mutation in PTC

Address correspondence to: Zhiyong Liang, Department of Pathology, Peking Union Medical College Hospital, Chinese Academy of Medical Sciences and Peking Union Medical College, 1 Shuai Fu Yuan Hu Tong, Beijing 100730, People's Republic of China. Tel: (86) 10-69155969; Fax: (86) 10-69155969; E-mail: liangzhiyong1220@yahoo.com

References

- [1] Pellegriti G, Frasca F, Regalbuto C, Squatrito S, Vigneri R. Worldwide Increasing Incidence of Thyroid Cancer: Update on Epidemiology and Risk Factors. *J Cancer Epidemiol* 2013; 2013: 965212.
- [2] Davies H, Bignell GR, Cox C, Stephens P, Edkins S, Clegg S, Teague J, Woffendin H, Garnett MJ, Bottomley W, Davis N, Dicks E, Ewing R, Floyd Y, Gray K, Hall S, Hawes R, Hughes J, Kosmidou V, Menzies A, Mould C, Parker A, Stevens C, Watt S, Hooper S, Wilson R, Jayatilake H, Gusterson BA, Cooper C, Shipley J, Hargrave D, Pritchard-Jones K, Maitland N, Chenevix-Trench G, Riggins GJ, Bigner DD, Palmieri G, Cossu A, Flanagan A, Nicholson A, Ho JW, Leung SY, Yuen ST, Weber BL, Seigler HF, Darrow TL, Paterson H, Marais R, Marshall CJ, Wooster R, Stratton MR, Futreal PA. Mutations of the BRAF gene in human cancer. *Nature* 2002; 417: 949-954.
- [3] Kimura ET, Nikiforova MN, Zhu Z, Knauf JA, Nikiforov YE, Fagin JA. High prevalence of BRAF mutations in thyroid cancer: genetic evidence for constitutive activation of the RET/PTC-RAS-BRAF signaling pathway in papillary thyroid carcinoma. *Cancer Res* 2003; 63: 1454-1457.
- [4] Liu X, Yan K, Lin X, Zhao L, An W, Wang C, Liu X. The association between BRAFV600E mutation and pathological features in PTC. *Eur Arch Otorhinolaryngol* 2014; 271: 3041-3052.
- [5] Basolo F, Torregrossa L, Giannini R, Miccoli M, Lupi C, Sensi E, Berti P, Elisei R, Vitti P, Baggiani A, Miccoli P. Correlation between the BRAF V600E mutation and tumor invasiveness in papillary thyroid carcinomas smaller than 20 millimeters: analysis of 1060 cases. *J Clin Endocrinol Metab* 2010; 95: 4197-4205.
- [6] Elisei R, Ugolini C, Viola D, Lupi C, Biagini A, Giannini R, Romei C, Miccoli P, Pinchera A, Basolo F. BRAF (V600E) mutation and outcome of patients with papillary thyroid carcinoma: a 15-year median follow-up study. *J Clin Endocrinol Metab* 2008; 93: 3943-3949.
- [7] Xing M, Alzahrani AS, Carson KA, Viola D, Elisei R, Bendlova B, Yip L, Mian C, Vianello F, Tuttle RM, Robenshtok E, Fagin JA, Puxeddu E, Fugazzola L, Czarniecka A, Jarzab B, O'Neill CJ, Sywak MS, Lam AK, Riesco-Eizaguirre G, Santisteban P, Nakayama H, Tufano RP, Pai SI, Zeiger MA, Westra WH, Clark DP, Clifton-Bligh R, Sidransky D, Ladenson PW, Sykorova V. Association between BRAF V600E mutation and mortality in patients with papillary thyroid cancer. *JAMA* 2013; 309: 1493-1501.
- [8] Li C, Lee KC, Schneider EB, Zeiger MA. BRAF V600E mutation and its association with clinicopathological features of papillary thyroid cancer: a meta-analysis. *J Clin Endocrinol Metab* 2012; 97: 4559-4570.
- [9] Sancisi V, Nicoli D, Ragazzi M, Piana S, Ciarrocchi A. BRAFV600E mutation does not mean distant metastasis in thyroid papillary carcinomas. *J Clin Endocrinol Metab* 2012; 9: 1745-1749.
- [10] McKelvie PA, Chan F, Yu Y, Waring P, Gresshoff I, Farrell S, Williams RA. The prognostic significance of the BRAF V600E mutation in papillary thyroid carcinoma detected by mutation-specific immunohistochemistry. *Pathology* 2013; 45: 637-644.
- [11] Koperek O, Kornauth C, Capper D, Berghoff AS, Asari R, Niederle B, von Deimling A, Birner P, Preusser M. Immunohistochemical detection of the BRAF V600E-mutated protein in papillary thyroid carcinoma. *Am J Surg Pathol* 2012; 36: 844-850.
- [12] Capper D, Preusser M, Habel A, Sahm F, Ackermann U, Schindler G, Pusch S, Mechtersheimer G, Zentgraf H, von Deimling A. Assessment of BRAF V600E mutation status by immunohistochemistry with a mutation-specific monoclonal antibody. *Acta Neuropathol* 2011; 122: 11-19.
- [13] Qiu T, Lu H, Guo L, Huang W, Ling Y, Shan L, Li W, Ying J, Lv N. Detection of BRAF mutation in Chinese tumor patients using a highly sensitive antibody immunohistochemistry assay. *Sci Rep* 2015; 5: 9211.
- [14] AJCC Cancer staging manual. 7th edition. New York: Springer-Verlag; 2012.
- [15] Bullock M, O'Neill C, Chou A, Clarkson A, Dodds T, Toon C, Sywak M, Sidhu SB, Delbridge LW, Robinson BG, Learoyd DL, Capper D, von Deimling A, Clifton-Bligh RJ, Gill AJ. Utilization of a MAB for BRAF (V600E) detection in papillary thyroid carcinoma. *Endocr Relat Cancer* 2012; 19: 779-784.
- [16] Zagzag J, Pollack A, Dultz L, Dhar S, Ogilvie JB, Heller KS, Deng FM, Patel KN. Clinical utility of immunohistochemistry for the detection of the BRAF v600e mutation in papillary thyroid carcinoma. *Surgery* 2013; 154: 1199-1204.
- [17] Ilie MI, Lassalle S, Long-Mira E, Bonnetaud C, Bordone O, Lespinet V, Lamy A, Sabourin JC, Haudebourg J, Butori C, Guevara N, Peyrottes I, Sadoul JL, Bozec A, Santini J, Capper D, von Deimling A, Emile JF, Hofman V, Hofman P. Diagnostic value of immunohistochemistry for

IHC for detecting of the BRAF V600E mutation in PTC

- the detection of the BRAF (V600E) mutation in papillary thyroid carcinoma: comparative analysis with three DNA-based assays. *Thyroid* 2014; 24: 858-66.
- [18] Jung YY, Yoo JH, Park ES, Kim MK, Lee TJ, Cho BY, Chung YJ, Kang KH, Ahn HY, Kim HS. Clinicopathologic correlations of the BRAFV600E mutation, BRAF V600E immunohistochemistry, and BRAF RNA in situ hybridization in papillary thyroid carcinoma. *Pathol Res Pract* 2015; 211: 162-170.
- [19] Lee JH, Lee ES, Kim YS. Clinicopathologic significance of BRAF V600E mutation in papillary carcinomas of the thyroid: a meta-analysis. *Cancer* 2007; 110: 38-46.
- [20] Xing M. BRAF mutation in thyroid cancer. *Endocr Relat Cancer* 2005; 12: 245-262.
- [21] Trovisco V, Soares P, Preto A, de Castro IV, Lima J, Castro P, Máximo V, Botelho T, Moreira S, Meireles AM, Magalhães J, Abrosimov A, Cameselle-Teijeiro J, Sobrinho-Simões M. Type and prevalence of BRAF mutations are closely associated with papillary thyroid carcinoma histotype and patients' age but not with tumour aggressiveness. *Virchows Archv* 2005; 446: 589-595.
- [22] Sancisi V, Nicoli D, Ragazzi M, Piana S, Ciarrocchi A. BRAFV600E mutation does not mean distant metastasis in thyroid papillary carcinomas. *J Clin Endocrinol Metab* 2012; 97: 1745-1749.