

Case Report

Metastasis of breast cancer to renal cancer: report of a rare case

Zhijun Huo¹, Yongsheng Gao², Zhiyong Yu¹, Wenshu Zuo¹, Yanfang Zhang³

¹Department of Breast Disease Centre, Shandong Cancer Hospital and Institute, Shandong Academy of Medical Sciences, People's Republic of China, Shandong, China; ²Department of Pathology, Shandong Cancer Hospital and Institute, Shandong Academy of Medical Sciences, People's Republic of China, Shandong, China; ³Department of Endocrinology, Laiyang Central Hospital, Changshan Road, Laiyang, Shandong Province, People's Republic of China, Shandong, China

Received September 13, 2015; Accepted October 23, 2015; Epub November 1, 2015; Published November 15, 2015

Abstract: Tumor-to-tumor metastasis (TTM) is a rare phenomenon. We present a case of an invasive ductal carcinoma (IDC) of the breast metastasizing to a clear cell renal cell carcinoma (RCC). Breast cancer (BC) metastasis to the RCC is rarely reported, especially in resected kidney tumor. In several cases reported, IDC was the exclusively histologic type of BC metastasized to RCC. It seems that the different molecular type of IDC doesn't affect the metastatic tendencies to RCC. TTM was an indicator of diffuse disease. For any patient with a history of breast cancer, especially with multi-organs metastasis, resection of kidney tumor should be carefully considered.

Keywords: Breast cancer, tumor-to-tumor metastasis, renal cell carcinoma

Introduction

Although the coexistence of two or more primary neoplasms in the same patient is fairly common, tumor-to-tumor metastasis (TTM) is a rare phenomenon. Here, we present a case of breast cancer (invasive duct cancer, IDC) metastasizing to a renal cell carcinoma (RCC) in the kidney. To the best of our knowledge, this is the third reported case of a resected RCC as the recipient tumor of breast IDC in tumor-to-tumor metastasis. Also, we identified 4 cases of metastases to the RCC from breast carcinoma according to previous case reports (2 cases by autopsy) in the literature. It showed that the metastasizing tendency of IDC to RCC have no relation with the estrogen receptor (ER) and/or progesterone receptor (PR) and HER-2/neu status.

Case report

A 43-year-old female was presented for suspected liver metastasis in regular follow-up after breast cancer surgery. The patient had a history of left breast carcinoma (diameter 2.5

cm) and received a modified radical mastectomy in 2010-3-21. Pathological examination of the tumor revealed an invasive duct carcinoma, stage II (T2N0M0). There was no lympho-vascular invasion and all 7 axillary lymph nodes were free of tumor. Immuno-histochemical staining showed the following result: approximately 90% of the cells were positive for estrogen receptor (ER) and progesterone receptor (PR), while HER-2/neu, P53 and EGFR were negative. These cells displayed a moderately high Ki-67 (20%) expression. The patient received 6 cycles of adjuvant chemotherapy composed of cyclophosphamide, epirubicine and fluorouracil (CEF protocol) after surgery. Five years of tamoxifen therapy was planned. No family history of breast cancer.

Follow-up: 4 years after mastectomy, computed-tomography (CT) examination revealed several enlarged mediastinal lymph nodes (**Figure 1A**), three nodules in the liver (**Figure 1B**), all were suspicious for metastatic disease. A mass (3.1 cm in diameter) in the middle-low pole of the left kidney (**Figure 1C**), was suspicious for malignancy. The tumor markers (TMs) expres-

Breast cancer metastasis to renal cancer

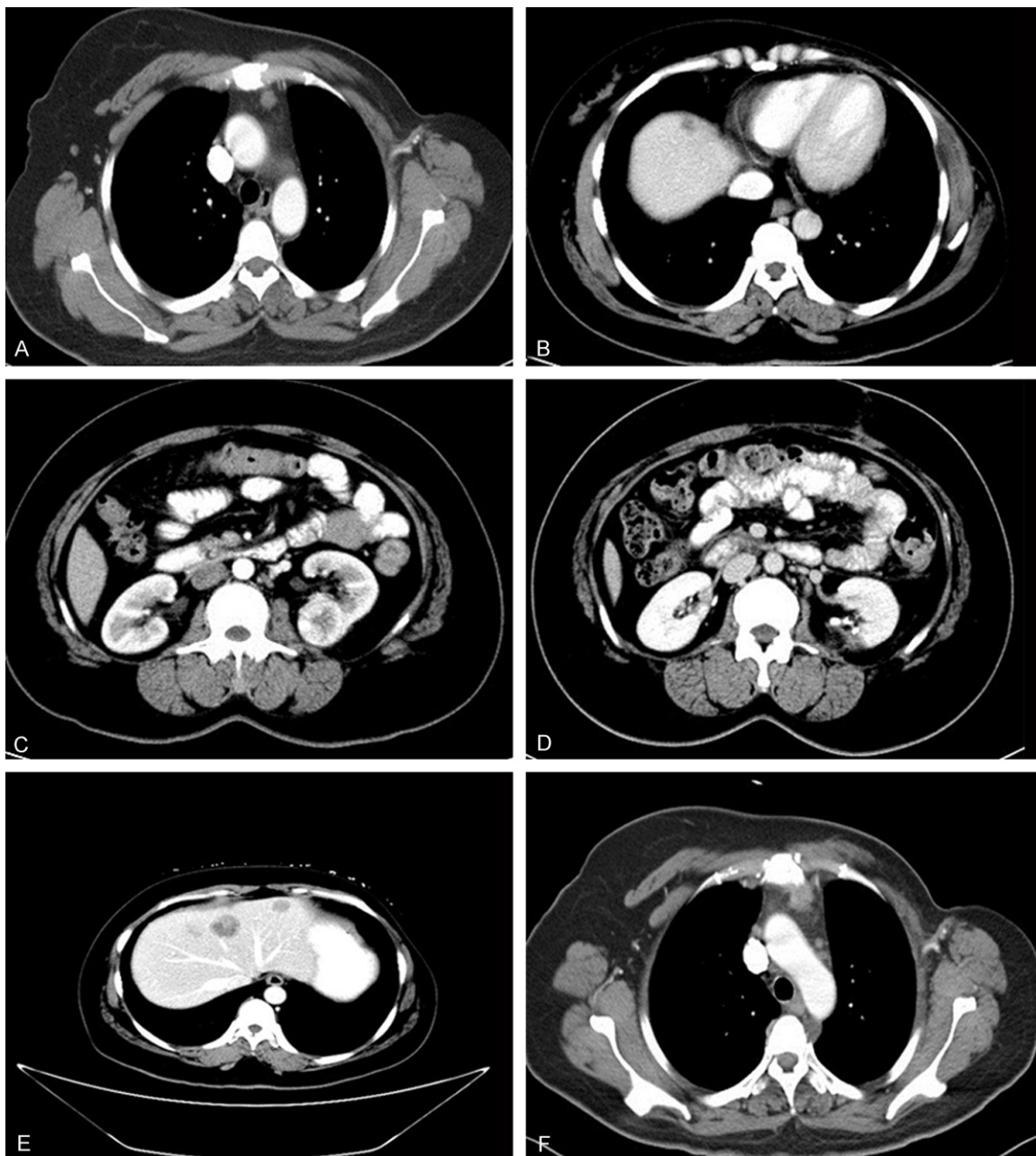


Figure 1. A. Chest CT: mediastinal lymph node enlargement, consider for breast cancer metastasis. B. Abdomen CT: intrahepatic nodules, consider for metastatic carcinoma. C. CT scan with the left renal mass, 3.0 cm in diameter. D. Abdomen CT after RCC operation. E. Metastatic disease progressed in the liver (4 months after RCC operation). F. Mediastinal metastatic disease progressed (4 months after RCC operation).

sion was also evaluated. Cancer antigen 125 (CA 125) level and CA 153 level were normal; carcinoembryonic antigen (CEA) level was elevated, which is 33.5 ng/mL (normal level: 0-3.4). The patient was diagnosed as metastatic breast cancer and underwent 4 cycles of chemotherapy consisted of docetaxel and cisplatin. Tumor response was evaluated by CT: the nodules in liver were partial response (PR), the

kidney mass and mediastinal lesion were stable disease (SD). CEA level was 12.96 ng/mL.

With relatively small burden of metastatic breast disease, surgical management for the renal mass was deemed appropriate. The patient received nephron-sparing surgery for left renal tumors in 2014-11-12. On gross examination, the removed renal tumor mea-

Breast cancer metastasis to renal cancer

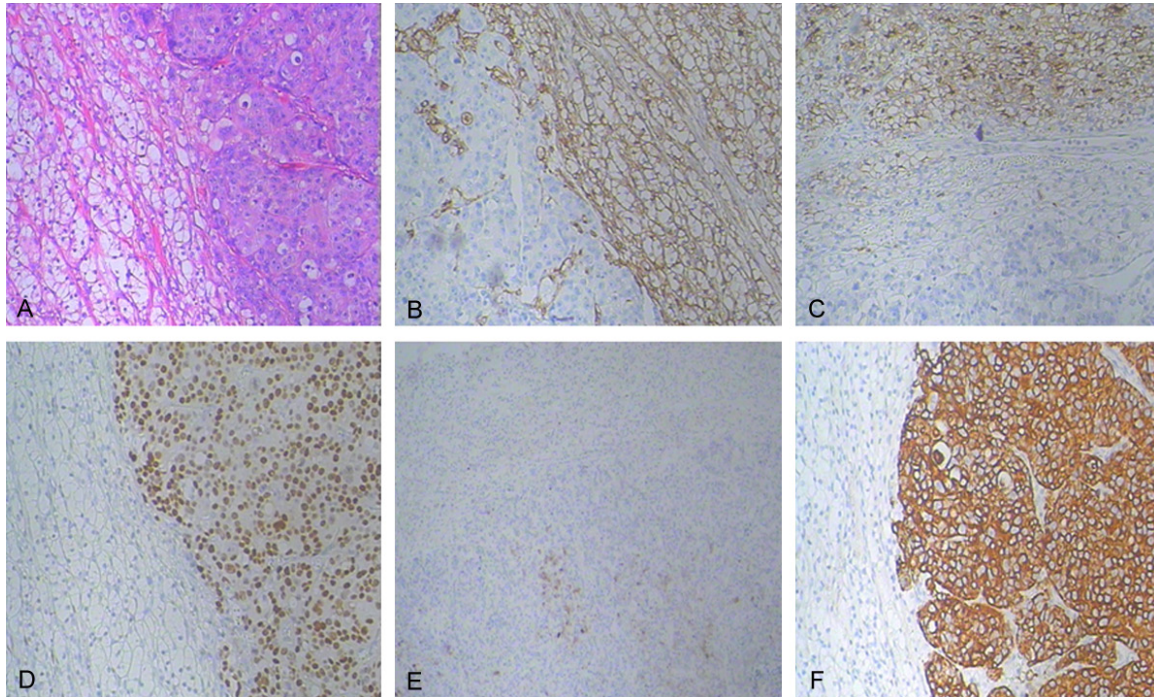


Figure 2. A. One small distinct lesion circumscribed by the RCC. HE ($\times 100$). B. Immunohistochemical (IHC) staining of RCC: positive for Vimentin ($\times 100$). C. IHC staining of RCC: positive for CD10 ($\times 100$). D. IHC staining of the metastatic focus: positive for ER ($\times 100$). E. IHC staining of the metastatic focus: positive for mammaglobin (MGB) ($\times 40$). F. IHC staining of the metastatic focus: positive for CK7 ($\times 100$).

Table 1. Character of breast cancer metastases to the RCC

Author	Age	Tumor type	TNM stage	Metastases Sites	Recurrence interval	Followup	ER	PR	HER-2
Sella A [6]	62	ductal	T2N2M0	RCC, liver, spleen, lung, bone	1 year	autopsy	no	no	no
Val-Bernal [10]	75	ductal	T2N0M0	Pleura, RCC pericardium, peritoneum lung, thoracic vertebrae	30 years	autopsy	-	-	+
Moller MG [9]	62	ductal	T4N3M0	RCC, pleura, scalp	2 years	die in 10 M	+	+	-
Christophe Perrin [11]	49	ductal	T2NxM1	RCC, lung and bone	2 months	no	-	-	-

M: month; +: positive; -: negative.

sured 3.0 cm \times 3.5 cm \times 3.0 cm. Histological analysis revealed conventional clear cell carcinoma, Fuhrman grade II. The lesion had invaded the renal capsule, had not reach to the perinephric fat, with negative lymph nodes (stage T1aN0M0). However, there was a small distinct focus measuring 0.8 cm \times 0.8 cm in dimensions found mostly circumscribed by the RCC (**Figure 2A**). The margin was clear and the renal parenchyma was uninvolved. Immunohistologic staining: RCC cells were positive for Vimentin (**Figure 2B**) and CD10 (**Figure 2C**). The distinct foci cells showed the following staining characteristics: approximately 80% of the cells were positive for estrogen receptor (ER) (**Figure 2D**), approximately 1% of the cells were positive

for progesterone receptor (PR), most cells were moderately positive for mammaglobin (MGB) (**Figure 2E**) and strong positive for cytokeratin-7 (CK7) (**Figure 2F**); These malignant cells were negative for Her-2/neu by fluorescence in situ hybridization (FISH) studies. This immunophenotype is consistent with the previously diagnosed breast cancer. Moreover, Mammaglobin (MGB) is a specific marker for breast carcinoma [1]. A diagnosis of duct breast carcinoma with metastasis to the RCC was then established.

The patient received 2 cycles of chemotherapy with single vinorelbine after operation, followed two cycles chemotherapy by single gemcitabine. Tumors response was evaluated by CT

Breast cancer metastasis to renal cancer

four months after kidney operation: no relapse at the left kidney (**Figure 1D**), hepatic lesions (**Figure 1E**) and the mediastinal lymph nodes (**Figure 1F**) progressed. Chemotherapy was stopped. The patient continues to take anti-estrogen hormonal therapy including luteinizing hormone-releasing hormone analog (Goserelin) and an aromatase inhibitor. Regular follow-up (in 3 months) showed that above lesions were even worse. The patient refused further treatment.

Discussion

It is rarely reported to have metastasis from one cancer to another. This phenomenon is clinically called tumor-to-tumor metastasis (TTM), first described by Bernet in 1902 [2]. The diagnosis of TTM requires the fulfillment of criteria described in 1968 by Campbell [3]. First, the patient must have two or more different tumors, and the recipient tumor being a true benign or malignant neoplasm. Second, the metastatic neoplasm must be a true metastasis, not a contiguous growth such as a “collision tumor”. Other additional criteria includes that the metastatic tumor must be compatible with the primary carcinoma by morphological or immunohistochemical means. This criteria excludes tumors that metastasized to the lymphatic system where lymphatic malignant disease already exists. Our case met all of the above criteria. Thus, it can be considered a true TTM.

Two theories are proposed to explain the pathophysiology of tumor-to-tumor metastasis. The “seed and soil” theory proposes that metastatic tumor cells (seeds) attain successful growth and propagation in a hospitable environment (soil) [4], such as tumor with a low metabolic rate and high collagen and lipid content. The “mechanical” theory proposes that the recipient tumors may be particularly susceptible to metastases because of high blood flow, highly vascular architecture, and anatomical location.

RCC was the most common tumor found to coexist with other malignancies [5]. The phenomenon of cancer-to-cancer is not as infrequent as previously thought and may be present in up to 15 percent of patients with simultaneous RCC and second neoplastic disease [6]. About 150 cases of tumor-to-tumor metastasis have been reported till 2003, in which the most frequent recipient is RCC, followed by sarcomas, meningiomas, thyroids

neoplasms and pituitary adenomas; Among the donor tumors, lung cancers is the most frequent primary, followed by breast, prostate, and thyroid carcinomas [7].

It is possible that RCC could provide a suitable environment for tumor growths due to its high lipid and glycogen content. In this regard Gore and Barr [8] suggested that RCC in its local stage may be a “dormant” tumor that has not yet attained anaerobic metabolism, a characteristic of the fully malignant neoplasms. According to “mechanical” theory, it assumes that a greater number of circulating metastatic cells will enter the RCC because of the high proportion of cardiac output that is received by the kidney.

There have been 47 cases of cancer-to-cancer metastases reported till 2005 [9]. We identified 4 cases of metastases to the RCC from breast carcinoma from series and case reports in the literature (PubMed) (**Table 1**). A review of these data inclusion of our case revealed that all cases were invasive duct type, without lobular type. Two cases (2/5) were ER/PR positive, two cases (2/5) were ER and PR negative, one patient was Her-2/neu positive, one patient had unknown ER/PR and Her-2/neu status. It seems that the different molecular type of IDC doesn't affect the metastatic tendency to RCC. Patient age was from 43 to 75 years old. In all these five cases, the longest interval time from mastectomy to diagnosis of TTM was 30 years while the shortest was 1 year. One patient showed lung and bone metastasis when diagnosed breast cancer. TTM accompanied multi-organs metastasis in all five cases (5/5). Two cases were found by autopsy. Three cases were found in resected RCC. Resection of RCC was helpful to get pathology diagnosis. But the prognosis of these 3 patients was poor. As can be seen from the above table, TTM was an indicator of diffuse disease. For any patient with a history of breast cancer, especially with multi-organs metastasis, resection of kidney tumor should be carefully considered.

In conclusion, this is the third case report of breast cancer with metastasis in a resected RCC. Because of the limited number of cases that occur and availability of follow-up information, additional studies are needed to further improve our understanding of the TTM and give these patients an appropriate treatment.

Breast cancer metastasis to renal cancer

Disclosure of conflict of interest

None.

Address correspondence to: Dr. Yanfang Zhang, Department of Endocrinology, Laiyang Central Hospital, Laiyang, Shandong Province, People's Republic of China, Shandong, China. Tel: 008653167626958; E-mail: hzj197610@163.com

References

- [1] Watson MA, Dintzis S, Darrow CM, Voss LE, DiPersio J, Jensen R, Fleming TP. Mammaglobin expression in primary, metastatic, and occult breast cancer. *Cancer Res* 1999; 59: 3028-31.
- [2] Ricketts R, Tamboli P, Czerniak B, Guo C. Tumor-to-tumor metastasis: report of 2 cases of metastatic carcinoma to angiomyolipoma of the kidney. *Arch Pathol Lab Med* 2008; 132: 1016-20.
- [3] Campbell LV, Gilbert E. Metastases of cancer to cancer. *Cancer* 1968; 22: 635-643.
- [4] Hart IR. "Seed and soil" revisited: mechanisms of site-specific metastasis. *Cancer Metastasis Rev* 1982; 1: 5-16.
- [5] Richardson J, Katamaya I. Neoplasma to neoplasm metastasis. *Arch Path* 1971; 91: 135-9.
- [6] Sella A, Ro JY. Renal cell cancer: best recipient of tumor-to-tumor metastasis. *Urology* 1987; 30: 35-38.
- [7] Petraki C, Vaslamatzis M, Argyrakos T, Petraki K, Strataki M, Alexopoulos C, Sotsiou F. Tumor to tumor metastasis: Report of two cases and review of the literature. *Int J Surg Pathol* 2003; 11: 127-135.
- [8] Gore I, Barr R. Metastasis of cancer to cancer. *Arch Pathol (Chicago)* 1958; 66: 293-8.
- [9] Möller MG, Gribbin T, Ebrom S, Padula G, Fitzgerald TL. Breast cancer metastatic to renal cell carcinoma. *Surgery* 2006; 139: 577-9.
- [10] Val-Bernal JF, Villoria F, Pérez-Expósito MA. Concurrent angiomyolipomas and renal cell carcinoma harboring metastatic foci of mammary carcinoma in the same kidney: an incidental autopsy finding in a patient with a follow-up of thirty years. *Ann Diagn Pathol* 2001; 5: 293-9.
- [11] Perrin C, Talarmin M, Fontaine A, Kerbrat P, Audrain O, Rioux-Leclercq N, Chiforeanu DC. Breast carcinoma metastasis into a renal cell carcinoma. *Ann Pathol* 2011; 31: 399-401.