

## Case Report

# Kissing molars: report of three cases and new prospective on aetiopathogenetic theories

Dardo Menditti<sup>1</sup>, Luigi Laino<sup>2</sup>, Marco Cicciù<sup>3</sup>, Antonio Mezzogiorno<sup>1</sup>, Letizia Perillo<sup>1</sup>, Marco Menditti<sup>1</sup>, Gabriele Cervino<sup>3</sup>, Lorenzo Lo Muzio<sup>2</sup>, Alfonso Baldi<sup>4</sup>

<sup>1</sup>Department of Multidisciplinary Medicine and Dental Science, Second University of Naples, Italy; <sup>2</sup>Department of Experimental Medicine, University Hospital of Foggia, Italy; <sup>3</sup>Department of Experimental Medicine and Odontostomatology, University Hospital of Messina, Messina 98125, Italy; <sup>4</sup>Department of Environmental, Biological and Pharmaceutical Sciences and Technologies Second University of Naples, Italy

Received October 1, 2015; Accepted November 22, 2015; Epub December 1, 2015; Published December 15, 2015

**Abstract:** Kissing molars (KMs) is an extremely rare condition of impacted third molars, pointed in the opposite direction in a single follicular space; it consists exactly in a full impacted of permanent molars which occurs only in the lower jaw. Actually, about less than thirty cases have been reported in scientific literatures. The aetiology and pathogenesis of this pathological double dental inclusion remain unknown; above all events that lead two molars to appear, as KMs remain mysterious. The association to metabolic connective diseases such as mucopolysaccharidosis was emphasized. KMs considered as an isolated event, may be associated to an abnormal position of the tooth-bud from lower permanent molars, or fourth supernumerary tooth (distomolar). Recently, hyperplastic dental follicle (HDF), with a down regulation of matrix metal-proteinases and up regulation of several genes of collagens, has been mentioned in association with KMs. In this paper, after having analyzed three new cases of KMs that have been treated, we report a new hypothesis. This last is based on the failure in the dental follicle's ability to initiate or continue properly resorption of the overlying alveolar bone, by many exogenous factors which may act on eruptive phase that would lead to its rotation with its contents coming out a pathological situation of KMs. The therapy of choice is related to the surgical removal of KMs through a double odontectomy with transalveolar method. Other treatments can be, eventually, orthodontic therapy of the impacted teeth and a radiological follow-up without surgery.

**Keywords:** Impacted teeth, kissing molars, dental follicle, hyperplastic dental follicles

## Introduction

Kissing molars (KMs) represent an extremely rare mandibular pathological condition. They are impacted permanent molars that have "occlusal surfaces contacting each other while their roots are pointed in the opposite direction, sharing a single follicular space with a continuous cement-enamel junction" [1-3].

Van Hoofer [1] presented the first description of this dental pathological condition in 1973, Robinson et al. [3] coined the specific term "kissing molars" in 1991. At the present time, about thirty cases have been reported in the scientific literature [4-18].

This dental inclusion is very rare because it presents a full impacted of permanent mandibular molars, more frequently unilateral, sometimes

bilateral, involving typically the last two molars (the second and third and, more rarely, the third and a fourth supernumerary molar), which are developed with an opposite position [5]. Due to all of these peculiar features, some authors [5, 12, 19] emphasized the association of KMs to metabolic diseases such as mucopolysaccharidosis. Nakamura et al. [5] described this pathological association with a particular situation of impacted teeth called "rosette formation" (sometimes reported in Literature as a synonym for KMs); Akbulut et al. [11] reported one case of KMs associated with MPS, and Cawson [19] associated a similar dental inclusion to gargoylism; some of them [5] reported KMs associated to the hyperplastic dental follicle (HDF); while others [11, 18] in an attempt to give an explanation accepted the hypothesis of pathological isolated events. However, the etiology and pathogenesis of this pathological

double dental inclusion remain unknown and above all events that lead two molars to appear, as KMs remain mysterious. From the epidemiological point of view, 27 KMs cases reported in Literature do not have a gender predilection, while the age range is young-adult (13 to 50 years), 11 cases are bilateral and only a few refer to patients with alteration of the connective tissue as the MPS [5, 11, 19] simultaneously with multiple dental inclusions. Regarding the teeth involved, it stands out as the wisdom tooth has a prominent role in percentage because it is the most present in the clinical/radiological conditions of KMs. Only one reported case of KMs regards teeth-bud of first and second molars treated with orthodontic therapy [11] of the first molar. From the clinical point of view [5, 13-15], patients with KMs may not report symptoms (in most cases, patients present only radiographic detection of KMs, sometimes associated with cystic dilatation of their dental follicle) or submit general symptoms (facial pain) [13] or specific (lack on the dental arch of impacted permanent teeth, facial swelling of the affected side) [5]. One of these symptoms may be the first and the only way that allows discovering this pathology. Usually, the diagnosis is occasional and it is made by radiological features on orthopantomography (OPG) [5, 7, 15]; the CT [14, 17] confirms with a detailed insight the aspects of the OPG and the close contact of the occlusal surfaces, it is required especially for the surgical procedure because it allows to display the topographical relationships with the anatomical structures to safeguard during surgical operation (avoiding inferior alveolar and lingual nerves damage and iatrogenic jaw fracture). Gulses et al. [14] in 2012 proposed a radiological classification of KMs based on involved teeth: Class I, opposed impaction of lower first and second molars; Class II, impaction of lower second and third molars; Class III, impaction of lower third and fourth molars. It seems appropriate to add to this classification the presence or absence of cystic dilatation of the dental follicle also as variant forms of KMs. For accuracy, Shahista et al. [15] emphasizes the importance of the close proximity of the occlusal surfaces of the two KMs, much to define them as the "true form" of this disease. The use of the terms 'true' justifies the use of the term "pseudo-kissing molars" [18]. In our opinion, it seems more appropriate to distinguish the

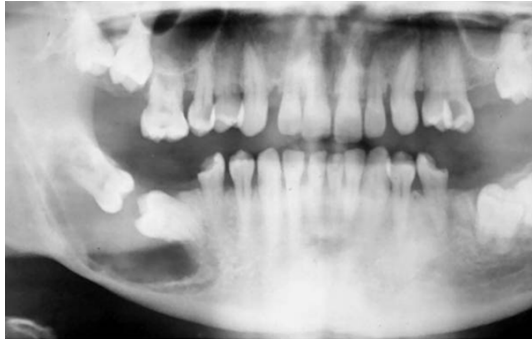cases of KMs that are not associated with MPS or to other diseases such as HDF, apart from identifying KMs in which the occlusal surfaces are not in direct contact, although in a single follicular space. Thus at date, the classification of KMs appears to be more complex with: True KMs, Pseudo-KMs; the True-KMs are isolated cases with three classes (I-II-III) and each of them can have a variant with cystic dilatation of the dental follicle [9, 13, 14]. Pseudo-KMs are considered the cases in syndromes and some don't have close contact of their occlusal surfaces. The therapy [12, 16], when the patient is able to undergo a surgical intervention, is surgical electively with removal of KMs in one intervention. More often, it is performed in regional anaesthesia, especially for mono-lateral cases or rarely under general anaesthesia, for the bilateral cases, in any case through a double odontectomy with transalveolar method. Other treatment options [5, 13, 14] may be: orthodontic therapy [11] of the impacted teeth, only if an eruption into occlusion of the second or a first molar involved in KMs is possible [5, 11]; a follow-up without surgery, if there are no symptoms and if there isn't a cystic dilatation of the dental follicle of KM [15].

However, the choice of treatment should always be discussed with the patient who makes the final decision. In the present study we report three cases of molars in the opposite position that can be referred to KMs and other pathological dental conditions that may be understood as variant of KMs.

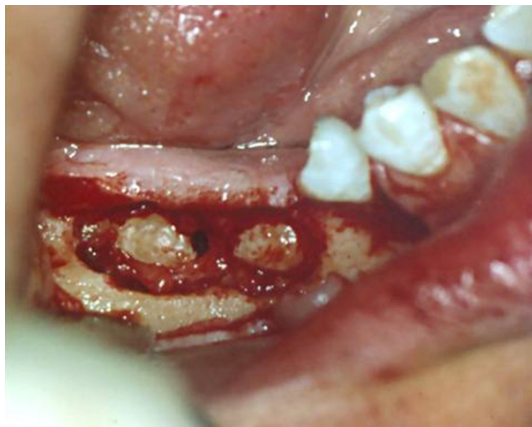### Patients and methods

In each of the reported cases the suggestive diagnosis of KMs was made. The combination with MPS was excluded. Medical history of patients was negative for any disease and only surgical therapy has been chosen for each of them. Operations were carried out in local anaesthesia. The impacted teeth were approached with a vestibular incision flap conducted on the edentulous ridge. After osteotomy, the impacted teeth were exposed. Next step was the section of one impacted molar and its removal. Then, the next molar was removed. The surgical sites were sutured with 2-0 silk with interrupted technique. The sutures were removed on the seventh post-operative day and the patients healed without any complica-

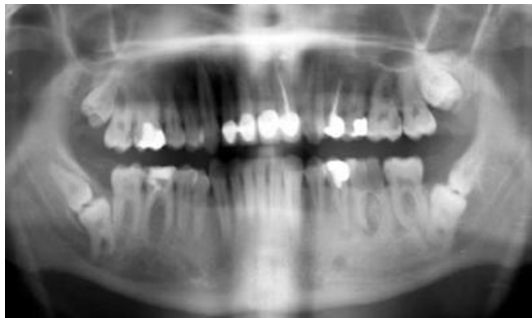## Etiopathogenesis of atopic lower third molars



**Figure 1.** True-KMs class I with a cystic dilatation of follicular sac; other disorders of eruption are visible to occur in other molar teeth (Pseudo-KMs).



**Figure 2.** Intraoperative phase in which is visible the cystic tissue surrounding KMs.

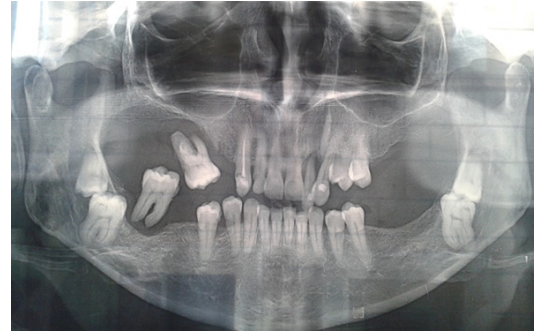


**Figure 3.** Bilateral True-KMs class III without cystic variant of third and fourth lower molars.

tion. Patient referred no post-operative complications: no pain, no paresthesia or infections were observed.

### Case 1

A 35 years old female patient, came to the Department of Oral Surgery of the Second

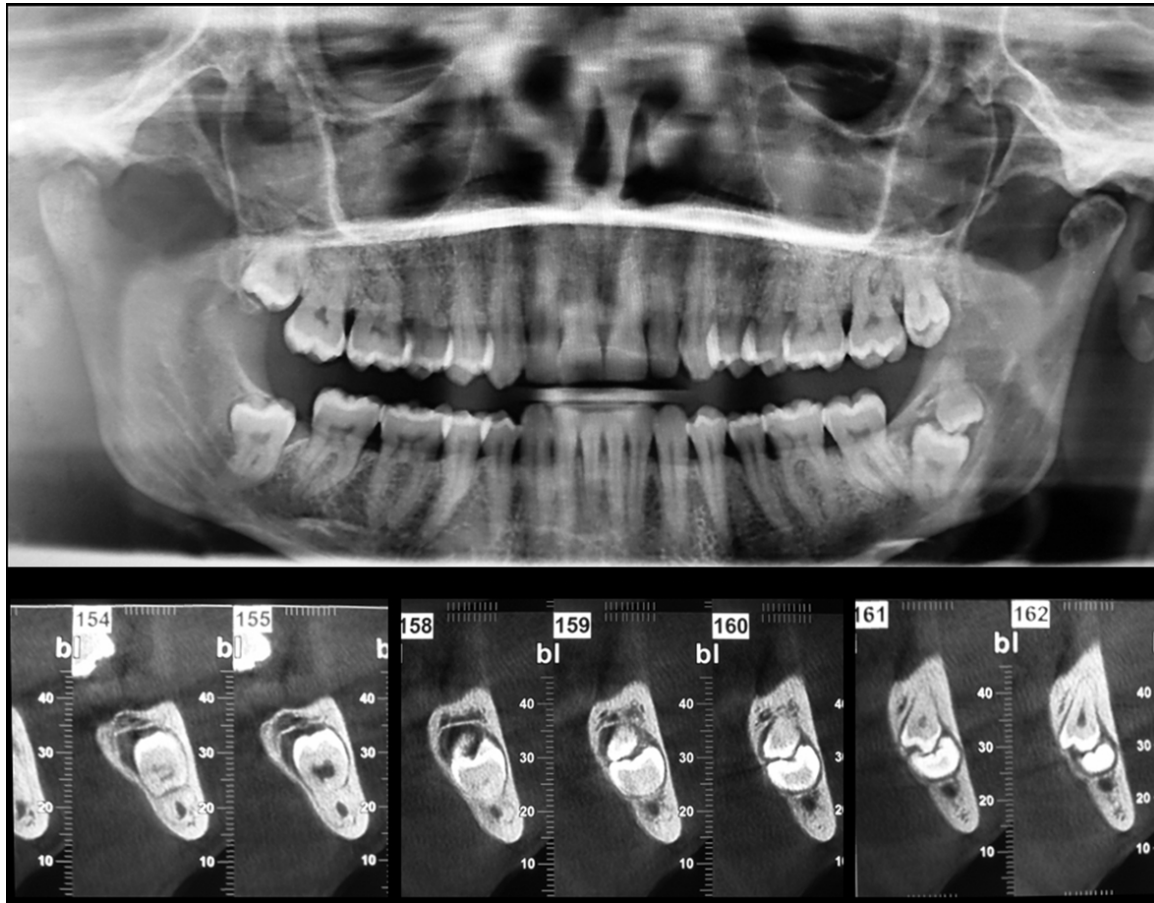


**Figure 4.** Rx OPT control revealing on the left side of the mandible the presence of KMs of the third and fourth molars (True-KMs class III without cystic variant); on the opposite side a third and a fourth molars appear impacted differently by KMs (pseudo-KMs).

University of Naples, Italy, sent by a dentist after Radiographic OPG-control, for a first visit Dental. OPG showed the inclusion of the first and second lower molars of the right side as KMs with a large cyst of the dental follicle (True-KMs class I with cystic variant) while the other side had an inclusion of the first and second molar without enlargement of follicular space, also the maxilla presented inclusion of the second and third molar of both sides without pathologies of the dental follicle; on the opposite side and in both sides of the maxilla other molars appear impacted paired between them but differently by KMs. The clinical intraoral exam showed the absence of molar teeth in the posterior region on all four molar sides, as well as absence of pain and symptoms of inflammation (**Figures 1, 2**). CT confirmed the data of OPG.

The treatment choice consisted in surgical removal of the KMs and follicular odontogenic cyst.

The follicular tissue removed and included in Haematoxylin and Eosin, was submitted to histopathological analysis, presenting a dentigerous cyst derived from dental follicle lined by a thin epithelium of 2-4 layers of cylindrical-cuboidal cells with some mucous-producing cells and attached at the amelo-cemental junction; it was surrounded by a tissue with poor evidence of fibrosis containing areas of odontogenic epithelial rests; a low grade of chronic inflammatory cells was showed in its wall. The cystic lumen showed atransudate fluid with desquamated scarces and inflammatory cells. A diagnosis of KMs with dentigerous cyst was made.



**Figure 5.** X ray orto panoramic evaluation and CT Dental scan evaluation of Kissing molars.

#### Case 2

A 56 years old male patient, came to the Department of Oral Surgery of the Second University of Naples, Italy, sent by a dentist after RxOPG-control revealing the presence of KMs of third and supposedly, fourth molars bilaterally (True-KMs class III without cystic variant) which have occlusal surfaces contacting each other in same follicular space with indication of their removal. The intraoral examination didn't show signs of inflammation or the presence of mandibular third molars. The prophylactic removal of both teeth was proposed to the patient.

To set the correct positioning of the teeth, as well as the exact relationship with the alveolar nerve channel, a cone beam computed tomography was obtained (CBCT).

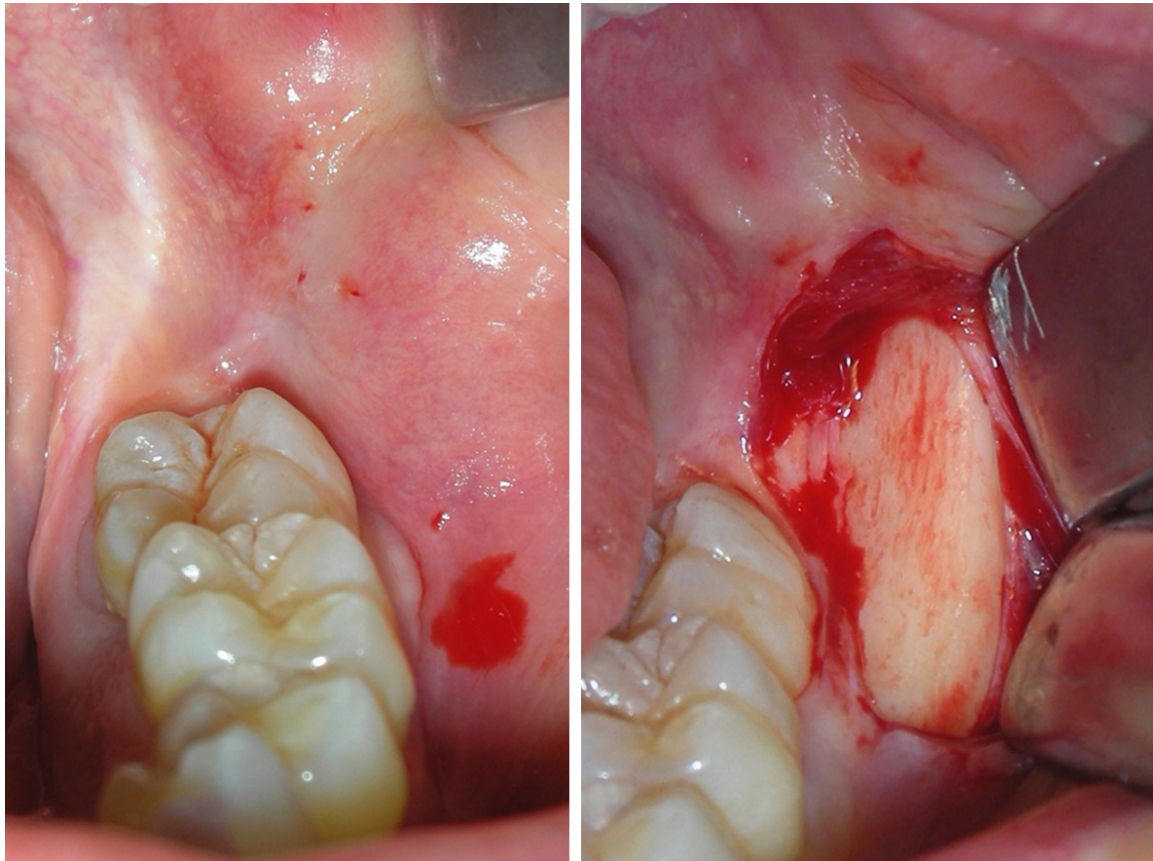
The follicular tissue removed was subjected to histopathologic analysis.

Histologically, the specimen included in haematoxylin and eosin, showed an abundant fibrous tissue containing areas of odontogenic epithelial rests and areas of calcifying and calcified tissue; a low grade of chronic inflammatory cells was showed in this wall (**Figures 3, 4**).

#### Case 3

A 30 years old female patient, came to the Department of Oral Surgery of the Second University of Naples, Italy, sent by a dentist after Rx OPG control revealing on the left side of the mandible the presence of KMs of the third and fourth molars (True-KMs class III without cystic variant) which have occlusal surfaces contacting each other in same follicular space with indication of their removal. On the opposite side a third and a fourth molars appear impacted differently by KMs: the two teeth are joined side by side, however, combining their space follicular as if something abnormal in the eruptive process had happened but unlike that





**Figure 6.** Clinical view of the surgical approach. A full thickness flap is opened in order to highlight the bone retro-molar cortical wall.

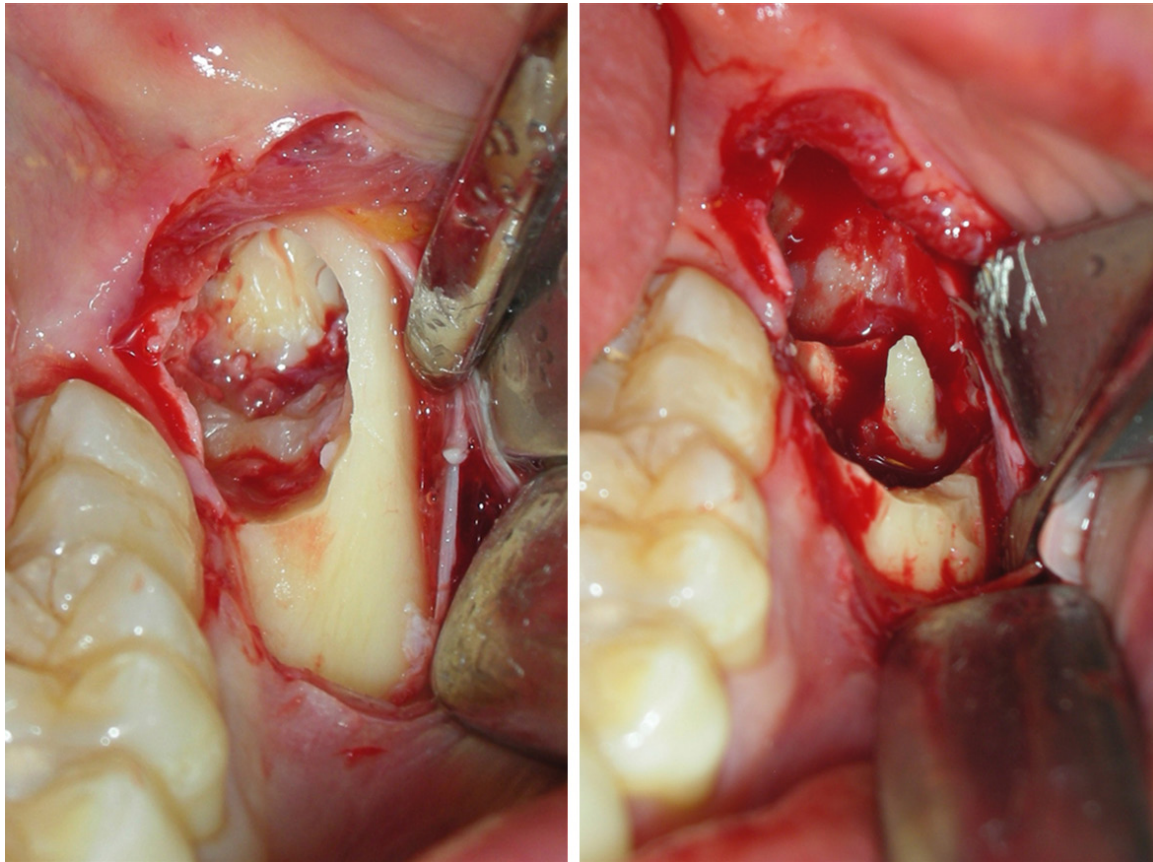
for KMs. CT confirmed the data of OPT and revealed a bone resorption of lingual side and sharp proximity to the alveolar nerve channel (Figures 5-9).

The patient accepted the surgery with removal of KMs and impacted teeth on other side, with its possible surgical complications. The clinical intraoral examination showed the absence of molar teeth in the posterior region bilaterally in both dental arches, as well as the absence of pain and symptoms of inflammation. The treatment choice consisted in surgical removal of the impacted teeth on both side. The specimen was subjected to Pathologist for analysis and included in Haematoxylin and Eosin. Some areas of calcified and calcifying stroma were present. It showed its wall with an abundant fibrous tissue, which contains areas of odontogenic epithelial, rests; a low grade of chronic inflammatory cells was showed in the wall. A suggestive diagnosis of KMs with HDF was made.

### Discussion

Among the cases reported by Nakamura et al. [4], we consider only one of them like KMs, because the other ones were multiple dental adjacent inclusions in MPS. We report three cases of KMs that, added to the 27 cases described in Literature, increase to 30. There is to be considered which present: 2 women and 1 male, with adult patients, one of them aged 56; no symptoms; one odontogenic cyst associated with KMs (case 1); one bilateral case (case 2), and one case with two contra-lateral molars were joined instead of opposing (case 3); the age of patients is as average statistic, without a gender predilection.

Among the thirty cases of KMs, it should be noted that most of them are related to young-adult patients (aged 13 to 50 years) with permanent dentition, without a predilection for sex; instead data concerning bilateral KMs appear to be more important; slightly less than



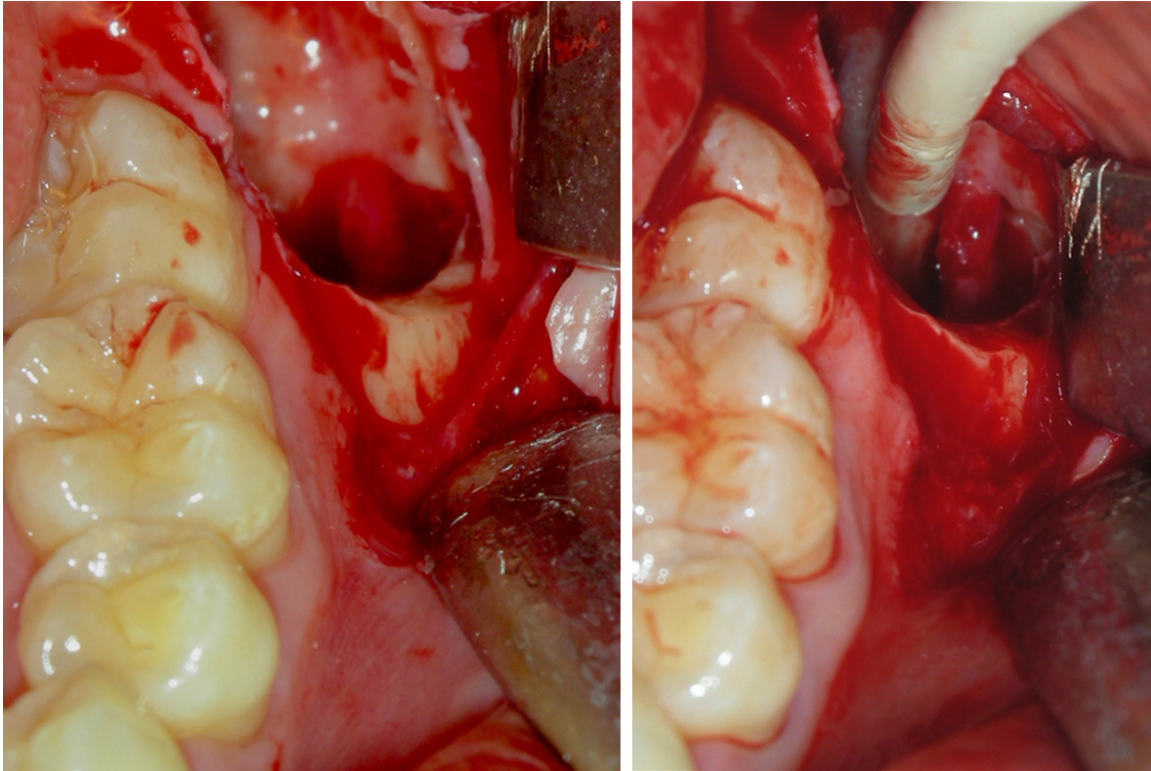
**Figure 7.** The surgical procedure by vestibular and occlusal osteotomy is underlined. The two kissing molars are highlighted and then removed.

half cases are bilateral, statistically in low percentage, and in terms of etiology they assume an important role in a critical discussion.

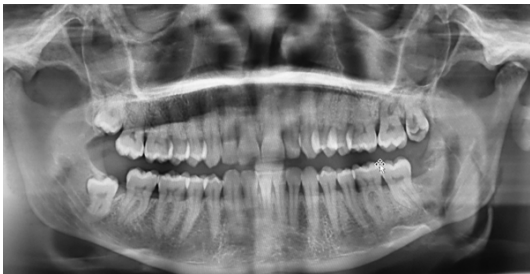Many theories have been reported in the literature [18] to explain the anomalous position of double dental inclusion in KMs. Some consider KMs as isolated events [4, 15]: an abnormal position of the tooth-bud from an early developmental stages of one or more normal lower permanent molars or fourth supernumerary tooth (so-called distomolar) [15] could lead to abnormal direction of development of their dental follicles; then, they could have abnormal eruption pathway of both teeth which come together and lead to a situation of KMs [4, 21]. Just one distomolar could impede the eruption of a third molar with his own presence and then the anomalous position of dental buds leads to a situation of KMs. For the theory of “bone loss” [14], a cystic formation of a molar resulting in a bone loss on the mesial root of an impacted molar through expansion cystic, may lead

the movement and rotation of teeth forming KMs; in addition, a fourth molar may be a predisposing factor for the bone loss adjacent to a third molar behaving the dual rotation of the molars involved [14]. These theories cannot be answers to all cases of KMs and namely the bilateral cases. Impacted molars forming “multiplerosetting” sometimes just like KMs have been reported with mucopolysaccharidoses (as type VI) [4, 20] and other with Gargoylism (mucopolysaccharidosis: MPS type I) [19]: inherited disorders caused by the absence or accumulation of some enzymes required to break down glycosaminoglycans (GAGs) which have ubiquitous nature in the connective tissues and relevance for its formation, maintenance, and repair. The important aspect of these inherited connective diseases associated with impacted molars, in our view, is that they affect the connective tissue and then the bone surrounding the tooth-bud: its pathological changes can lead to altered tooth eruption with lock and sometimes radiographic imaging





**Figure 8.** The surgical site after the kissing molars removal.



**Figure 9.** The 6 months post-operative x ray ortho panoramic shows the healing in the treated area.

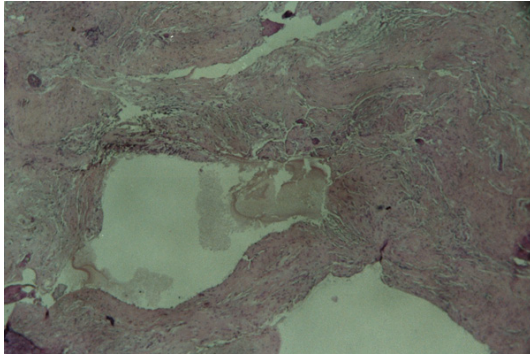
characteristics referred sometimes as KMs and other like “rosetting”. Another disorder that involves an impaired dental eruption is the hyperplastic dental follicle (HDF) [24], recently mentioned associated with KMs5. It is currently considered a hamartomatous odontogenic lesion of the pericoronal tissue of an unerupted tooth involving last molars of young patients [22]; however, hamartomatous tissue formation from odontogenic tissue is a known phenomenon [23].

HDF is a disease with expansion of the follicular space of about 3-5 mm around the crown of an

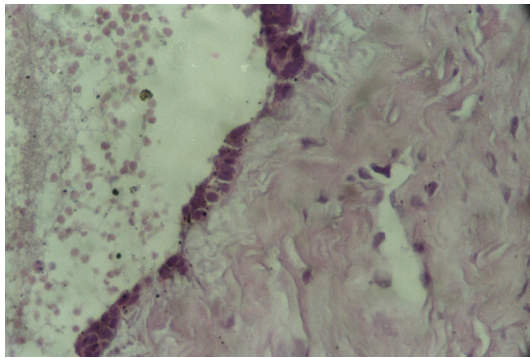
unerupted tooth in non syndromic patients [22-24]; the histological analysis of the tissue of HDF reveals copious amounts of fibrous connective tissue and collagen fibers of the dental follicle, islands of odontogenic epithelium, mesenchymal multinucleated giant cells, and mineralized areas calcifying [5, 22].

HDF, according to histological observations [22], may be confused with odontogenic fibroma, although Gardner [25] and Philipsen et al. [26] clearly marked the differences between the two diseases. Multiple impacted teeth in the same patient with enlargement of dental follicles, presenting fibrous tissue with numerous calcifications and areas of odontogenic epithelial rests, is termed multiple calcifying hyperplastic dental follicles (MCHDF) [27, 28], for the first time described by Sandler as Calcified-HDF [39]; this condition should be considered a distinct pathology.

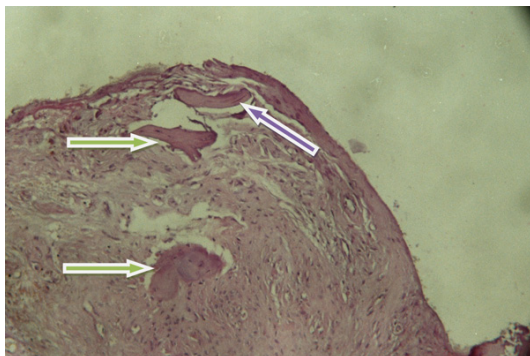
Its histological features are similar to HDF, although involving more teeth [28]. Recent scientific documents emphasize the familiarity of the MCHDF [29]; up now no association with KMs are reported.



**Figure 10.** Follicular cystic wall (Case 1) presenting relatively homogenous calcified areas with distributed cells. Islands of odontogenic epithelium, fibrous connective tissue relatively dense, moderately cellular with low grade of chronic inflammatory cells are presented.

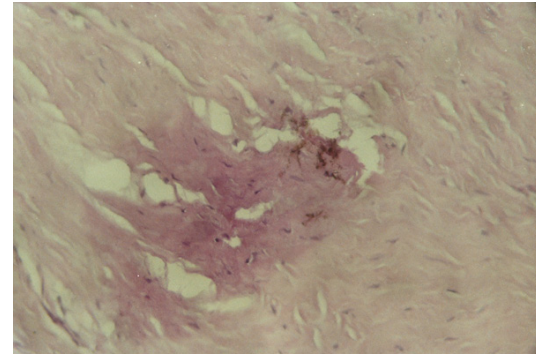


**Figure 11.** Follicular cystic-wall of True-KMs.

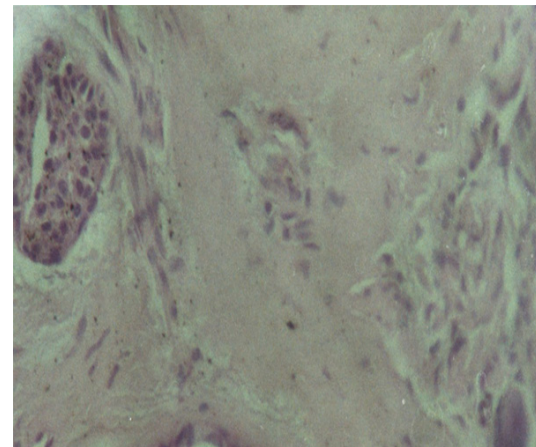


**Figure 12.** Cellular homogenous calcified areas (type II of MCHDF): blue arrow; on the upper side an area presenting a cellular calcification resembling woven bone (type I of MCHDF): green arrows.

However, it is quite common to find calcifying epithelial odontogenic rests in normal dental follicles of unerupting teeth [30-32].



**Figure 13.** An area of cellular calcification information: some cells appear to be in the calcific tissue resembling woven bone.



**Figure 14.** Epithelial islands are clearly highlighted in the follicular wall.

By histological observations [33], normal dental follicle (NDF) is characterized by dense/ loose connective tissue with reduced enamel epithelium lining, areas of epithelial rests, inflammatory cells, myxoid tissue and calcification similarly to the cases presented. Kiran et al. [5] who has analyzed the cases of KMs, reported to date describes kMs and HDF for the first time in pathological association in Literature. Kim et al. [30] found a downregulation of matrix metalloproteinases and upregulation of several genes of collagens in non-syndromic HDF resulting in abnormal connective tissue remodelling with defective tooth eruption, also found an overexpression of BMP-4 that are involved in the morphogenesis dental [34] and that may be related to the formation of ectopic calcifications in fibrous dental follicle. In the process of tooth eruption [35, 36] it



seems that NDF [37] has a main role [38, 39]. It acts with its upper half with specific enzymes (MMP) [40-43], which play a role in bone resorption for the dental eruption. The causes of dental inclusion could be failure in the dental follicle's ability, to initiate or continue properly resorption of the overlying alveolar bone. In particular, it seems that many exogenous factors may act on eruptive phase such as: cortisone, which presents inhibition of rat molar eruption [35]; the LASER which has a stimulating effect on tooth movement [44-46], chronic stress that seems to have a negative effect the eruption of the molars in rats [47]. Wise et al. [48] reported that injections of osteoprotegerin or phorbolmyristate acetate (PMA), an activator of protein kinase, upregulating expression in the follicle delay tooth eruption. In our opinion, in case of isolated KMs without association with non-syndromic HDF, based on the data collected from literature (involvement of connective tissue metabolism as KMs in MPS, hyperplasia of the connective tissue of the DF in HDF, recent theories on tooth eruption, exogenous factors that affect tooth eruption, the role of MMP), it seems plausible to assume that: in the aetiology of KMs an exogenous factor could alter the action of the MMP and the alveolar bone resorption in the coronal area of the follicle of dental bud. Maybe, this alteration may not be the same on all sides of this area with inhibition or stimulation of MMP on only one part; a greater activity of MMP only on one side of DF would lead to its rotation with its contents. Continuing the eruptive process, one or both of the dental follicles revolve and then combine them together to form a single follicular space. Although it is only one dental follicle that revolves still could, joining the adjacent one, forcing him to turn conforming pathological situation of KMs.

### Conclusion

With regard to the aetiology, it is necessary to add some considerations of ours. The histological features of cases of KMs presented (**Figures 10-14**) don't appear specific but similar to those reported in the literature with some characteristics reported for HDF (calcifications acellular and cellular). All of these appear to be in relation with a prolonged activity of the DF and static or in the sense of involution from the functional point of view.

The cystic expansion ("bone-loss" theory) of the dental follicle is not always present in case of KMs and therefore more likely, it may be a consequence more than the cause of the inclusion of these molars; often, the permanent state of included teeth can lead to a fibrotic reaction of the wall of their dental follicle as well as a transformation of fibrotic areas with calcification; the KMs can be unilateral or bilateral and simultaneous with other impacted teeth in other mandibular regions or in the maxilla; the KMs could include the distal supernumerary lower molar or the first and second lower molar but the third molar is almost always involved, probably because of its position and its phylogenetic/ontogenetic history [49]; the pathological condition of KMs, regards, almost always, the lower molars without participation of the other portions of lower dental arch. Just the first and the second case we have presented, with two different bilateral fates of the last mandibular molars, could corroborate our hypothesis: an external factor may have disturbed the tooth eruption, probably by acting on enzymes of the dental follicle, on one side leading to a situation of KMs, on the other side to a different situation of impacted teeth. Through the analysis of the cases we observed and data reported in Literature, the DF seems to have its own autonomy and consequently a pathology which may lead, in some cases, to the KMs. Therefore, it seems plausible the hypothesis about the fate of some molar teeth including in relation to the role of MMPs in the process of dental eruption, but more studies are required about it. However in the case of patients with KMs it seems appropriate to search of the MPS, as happened in the case of Nakamura et al. [4] and Akbulut et al. [11].

The diagnosis of KMs is radiological. All the data reported in the literature [39] and in our work allow us to speculate that KMs are a consequence of a disorder of the eruption dental could be consider as pathology of the dental follicle; on the other hand the presence of calcifications, nests of odontogenic epithelium and multinucleated cells is frequent in normal pericoronal dental tissues or in odontogenic cyst and tumors [50, 51]. The main purpose of the current scientific study, after a critical point of view for the pathogenesis of KM, is to point out the chance to meet in dental practice on Rx-OPG molar-buds in abnormal position that

could become KMs and therefore might get an interceptive orthodontic treatment.

## Disclosure of conflict of interest

None.

**Address correspondence to:** Dr. Marco Cicciù, Oral Surgery Medical Practitioner, Department of Human Pathology, School of Dentistry, University of Messina, Policlinico G. Martino, Via Consolare Valeria 98100, Italy. Tel: +390902216920; E-mail: acromarco@yahoo.it

## References

- [1] Van Hoof RF. Four kissing molars. *Oral Surg Oral Med Oral Pathol* 1973; 35: 284.
- [2] Juneja M. Not kissing. *Br Dent Journal* 2008; 204: 597.
- [3] Robinson JA, Gaffney W Jr, Soni NN. Bilateral 'kissing' molars. *Oral Surg Oral Med Oral Pathol* 1991; 72: 760.
- [4] Nakamura T, Miwa K, Kanda S, Nonaka K, Anan H, Higash S, Beppu K. Rosette formation of impacted molar teeth in mucopolysaccharidoses and related disorders. *Dentomaxillofac Radiol* 1992; 21: 45-49.
- [5] Kiran HY, Bharani KS, Kamath RA, Manimangalath G, Madhushankar GS. Kissing molars and hyperplastic dental follicles: report of a case and literature review. *Chin J Dent Res* 2014; 17: 57-63.
- [6] McIntyre G. Kissing molars: an unaccepted finding. *Dent Update* 1997; 24: 373-73.
- [7] Manani A. Kissing molars: unexpected finding. *Dent Update* 1998; 25: 219.
- [8] Bakaeen G, Baqain ZH. Interesting case: kissing molars. *Br J Oral Maxillofac Surg* 2005; 43: 534.
- [9] Krishnan B. Kissing molars. *Brit Dent J* 2008; 204: 281-282.
- [10] Boffano P, Gallesio C. Kissing molars. *J Craniofac Surg* 2009; 20: 1269-1270.
- [11] Akbulut N, Tatidze M, Kolsuz ME, Sindel A, Çolok G. Kissing molars: a rare condition of two case. *A.U. Dis Hek Fak Derg* 2009; 36: 169-172.
- [12] GiralardiNeto FO, Rocha JHV, Martinez JW, Duarte GB, Salgueiro DG, Sant'ana E. Interesting cases of kissing molars. Report of Two Cases *Rev Odontol UNESP* 2012; 41: 292-295
- [13] Sá Fortes RZ, Júnior VS, Modolo F, Mackowiecky E. Kissing molars: report of a case. *J Oral Maxillofac Surg Med Pathol* 2012; 26: 48-51.
- [14] Gulses A, Varol A, Senceman M, Dumlu A. A study of impacted love: kissing molars. *Oral Health Dent Manag* 2012; 11: 185-8.
- [15] Shahista P, Mascarenhas R, Shetty S, Husain A. Kissing molars: an unusual unexpected impaction. *Arch Med Health Sci* 2013; 1: 52.
- [16] Jannu AA, Veena GC, Kamath R, Bharani KSN, Vivek GK. Missing molars caught kissing. *IOSR* 2014; 14: 51-54.
- [17] Scheuber S, Bornstein M. Kissing molars. A peculiar radiologic finding. *Swiss Dent J* 2014; 124: 16-7.
- [18] Nedjat-Shokouhi B, Webb RM. Bilateral kissing molars involving a dentigerous cyst: report of a case and discussion of terminology. *Oral Surgery* 2014; 7: 107-110.
- [19] Cawson RA. The oral changes in gargoylism. *Proc R Soc Med* 1962; 55: 1066-1070.
- [20] Cavaleiro RM, PinheiroMd, Pinheiro LR, Tuji FM, FeioPdo S, de Souza IC, Feio RH, de Almeida SC, Schwartz IV, Giugliani R, Pinheiro JJ, Santana-da-Silva LC. Dentomaxillofacial manifestations of mucopolysaccharidosis VI: clinical and imaging findings from two cases, with an emphasis on the temporomandibular joint. *Oral Surg Oral Med Oral Pathol Oral Radiol* 2013; 116: 141-8.
- [21] Nishikawa S, Cheng J, Koyano Y, et al. Dentigerous cyst involving two impacted molars: report of a case. *Oral Med Pathol* 1996; 1: 60-2.
- [22] Schmitd LB, Bravo-Calderón DM, Soares CT, Oliveira DT. Hyperplastic dental follicle: a case report and literature review. *Case Rep Dent* 2014; 2014: 251892.
- [23] Ide F, Obara K, Yamada H, Mishima K, Saito I, Horie N, Shimoyama T, Kusama K. Hamaromatous proliferations of odontogenic epithelium within the jaws: a potential histogenetic source of intraosseous epithelial odontogenic tumors. *J Oral Pathol Med* 2007; 36: 229-35.
- [24] Villalba L, Stolzizer F, Blasco F, Mauriño NR, Piloni MJ, Keszler A. Pericoronal follicles of asymptomatic impacted teeth: radiographic, histomorphologic, and immunohistochemical study. *Int J Dent* 2012; 2012: 935310.
- [25] Gardner DG. The central odontogenic fibroma: an attempt at clarification. *Oral Surg Oral Med Oral Pathol* 1980; 50: 425-432.
- [26] Philipsen HP, Thosaporn W, Reichart P, Grundt G. Odontogenic lesions in opercula of permanent molars delayed in eruption. *J Oral Pathol Med* 1992; 21: 38-41.
- [27] Cho YA, Yoon HJ, Hong SP, Lee JI, Hong SD. Multiple calcifying hyperplastic dental follicles: comparison with hyperplastic dental follicles. *J Oral Pathol Med* 2011; 40: 243-249.
- [28] Jamshidi S, Zargarani M, Mohtasham N. Multiple Calcifying Hyperplastic Dental Follicle (MCHDF): a case report. *J Dent Res Dent Clin Dent Prospects* 2013; 7: 174-176.

- [29] Sun CX, Ririe C, Henkin JM. Hyperplastic dental follicle-review of literature and report of two cases in one family. *Chin J Dent Res* 2010; 13: 71-75.
- [30] Kim SG, Kim MH, Chae CH, Jung YK, Choi JY. Downregulation of matrix metalloproteinases in hyperplastic dental follicles results in abnormal tooth eruption. *BMB Rep* 2008; 41: 322-7.
- [31] Verma DK, Nair PN, Luder HU. Quantitative histological and ultrastructural features of opercula of normally erupting human teeth. *Microsc Res Tech* 2005; 67: 279-285.
- [32] Barnes L, Everson JW, Reichart P, Sidranski D. Clasification of Tumours. Pathology and genetics of head and neck tumours. Lyon, France: IARC Press; 2005.
- [33] Kotrashetti VS, Kale AD, Bhalaerao SS, Hallikeremath SR. Histopathologic changes in soft tissue associated with radiographically normal impacted third molars. *Indian J Dent Res* 2010; 21: 385-90.
- [34] Kim SG, Yang BE, Oh SH, Min SK, Hong SP, Choi JY. The differential expression patterns of BMP-4 between the cyst and the odontogenic Dentigerous Keratocyst. *J Oral Pathol Med* 2005; 34: 178-183.
- [35] Wise GE, Yao S, Henk WG. Bone formation as a potential motive force of tooth eruption in the rat molar. *Clin Anat* 2007; 20: 632-639.
- [36] Kjær I. Mechanism of human tooth eruption: review article including a new theory for future studies on the eruption process. *Scientifica* 2014; 2014: 341905.
- [37] Wang XP. Tooth erupting without roots. *J Dent Res* 2012; 92: 212-214.
- [38] Marks SC Jr, Cahill DR. Experimental studies in the dog highlight the non-active role of the tooth in the eruptive process. *Arch Oral Biol* 1984; 29: 311-322. The DF acts with its upper half with specific enzymes, MMP.
- [39] Brkic A. Dental follicle: Role in development of odontogenic cysts and tumors. *Journal of Istanbul University Faculty of Dentistry* 2014; 48: 89-96.
- [40] Beertsen W, Holmbeck K, Niehof A, Bianco P, Chrysovergis K, Birkedal-Hansen H, Everts V. On the role of MT1-MMP, a matrix metalloproteinase essential to collagen remodeling, in murine molar eruption and root growth. *Eur J Oral Sci* 2002; 110: 445-451.
- [41] Beertsen W, Holmbeck K, Niehof A, Bianco P, Chrysovergis K, Birkedal-Hansen H, Everts V. Inhibition of molar eruption and root elongation in MT1-MMP-deficient mice. *Connect Tissue Res* 2003; 44 Suppl 1: 298-299.
- [42] Omar NF, Gomes JR, Neves Jdos S, Salmon CR, Novaes PD. MT1-MMP expression in the odontogenic region of rat incisors undergoing interrupted eruption. *J Mol Histol* 2011; 42: 505-511.
- [43] Liu D, Yao S, Pan F, Wise GE. Chronology and regulation of gene expression of RANKL in the rat dental follicle. *Eur J Oral Sci* 2005; 113: 404-409.
- [44] Domínguez A, Gómez C, Palma JC. Effects of low-level laser therapy on orthodontics: rate of tooth movement, pain, and release of RANKL and OPG in GCF. *Lasers Med Sci* 2015; 30: 915-23.
- [45] Stein E, Koehn J, Sutter W, Wendtlandt G, Wanschitz F, Thurnher D, Baghestanian M, Turhani D. Initial effects of low-level laser therapy on growth and differentiation of human osteoblast-like cells. *Wien Klin Wochenschr* 2008; 120: 112-7.
- [46] Jawad MM, Husein A, Alam MK, Hassan R, Shaari R. Overview of non-invasive factors (low level laser and low intensity pulsed ultrasound) accelerating tooth movement during orthodontic treatment. *Lasers Med Sci* 2014; 29: 367-72.
- [47] Fontanetti PA, De Lucca RC, Mandalunis PM, Vermouth NT. Impairment of rat tooth eruption in pups born to mothers exposed to chronic stress during pregnancy. *Arch Oral Biol* 2013; 58: 643-651.
- [48] Wise GE, Yao S, Liu D. Injections of osteoprotegerin and PMA delay tooth eruption. *Clin Anat* 2006; 19: 19-24.
- [49] Laino L, Menditti D, Lo Muzio L, Laino G, Lauritano F, Cicciù M. Extraoral surgical approach of ectopic mandibular third molar to the lower border of mandible. *J Craniofac Surg* 2015; 26: e256-60.
- [50] In: Barnes L, Everson JW, Reichart P, Sidranski D, editors. World Health Organization Classification of Tumours. Pathology and genetics of head and neck tumours. Lyon, France: IARC Press; 2005.
- [51] Schmitz LB, Bravo-Calderón DM, Soares CT, Oliveira DT. Hyperplastic dental follicle: a case report and literature review. *Case Rep Dent* 2014; 2014: 251892.