

Original Article

Effects of angiotensin-converting enzyme inhibition and bradykinin peptides in rats with myocardial infarction

Zhe Qu^{1*}, Hongxin Xu^{1*}, Yihao Tian^{1,2}

¹Department of Cardiology, Renmin Hospital of Wuhan University, Wuhan 430060, China; ²Department of Anatomy, Basic Medical College of Wuhan University, Wuhan 430071, China. *Equal contributors.

Received January 11, 2015; Accepted February 28, 2015; Epub March 1, 2015; Published March 15, 2015

Abstract: Background and objective: Angiotensin-converting enzyme (ACE) inhibitors have been reported to decrease myocardial remodeling and facilitate cardiac function improvement in the setting myocardial infarction by affecting bradykinin. The purpose of this study was to evaluate the combination effects of perindopril and bradykinin (BK) in rats with myocardial infarction. Methods: Wistar Rats underwent to left anterior descending (LAD) coronary artery ligation were allocated into MI group (n = 6); Perindopril group (n = 7); Perindopril + BK group (n = 7). An additional sham operation group (Sham group, n = 6) were also established. After 4 weeks, the left ventricle function, myocardial tissue morphology, myocardial collagen volume fraction, infarcted ventricular wall thickness, myocardial infarction area and neovascular formation were evaluated. Results: Combination treatment with perindopril and BK were showed significant improvement on LVEDV, LVEF and LVFS than MI group. Moreover, a significant improvement on LVEF was found in Perindopril + BK group than Perindopril group but not on LVEDV and LVFS between these two groups. Furthermore, neo-vessel density was significantly increased in Perindopril + BK group than other groups while no significant improvement on vessel density was found after the treatment of perindopril. In addition, myocardial infarction thickness improvement was found in Perindopril and group than MI group while combination treatment with perindopril and BK can significant improve the myocardial infarction thickness than perindopril only. Conclusions: Combination treatment with ACE inhibitor perindopril and BK can significantly improve the ventricle function in the rat model of myocardial infarction. Our data suggest BK can serve as adjuvant treatment in myocardial infarction treatment.

Keywords: Myocardial infarction, angiotensin-converting enzyme (ACE) inhibitors, perindopril, bradykinin (BK)

Introduction

Myocardial infarction (MI), usually known as a heart attack, is an irreversible process of heart muscle necrosis secondary to prolonged ischemia [8]. It is the major medical issues with high morbidity and mortality worldwide. In the United States, the occurrence of MI was approximately 1.5 million cases per year [7]. Due to the occurrence of industrialization, urbanization and life-style changes worldwide, the population grows older in relationship with the risks of cardiovascular diseases [13]. Therefore, seeking for the appropriate treatments are urgently needed.

Previous studies have shown that ACE inhibitors are effective therapeutic choice for the treatment of heart failure, hypertension, and

other cardiovascular and renal diseases [1]. Moreover, ACE inhibition has also been confirmed as a novel agent for the macrovascular and microvascular disorders treatment in the patients with more complicated setting (such as diabetes) [4]. In addition, activation of the bradykinin (BK) B₂ receptor signaling pathway by ACE inhibition could result in increasing of ischemia induced neovascularization in rabbit and rodent hind limbs [10]. However, the exact role of BK has not determined yet in the pathological condition of myocardial infarction.

Here, we presented a study on combination application with angiotensin-converting enzyme (ACE) inhibitor perindopril and bradykinin in a rat model of myocardial infarction and found that perindopril and BK can significantly improve the ventricle function, which may impli-

Table 1. Cardiac function evaluation by echocardiography

	Sham (n = 6)	MI (n = 6)	Perindopril (n = 7)	Perindopril + BK (n = 7)
LVd (cm)	0.54 ± 0.72*	0.71 ± 0.12	0.64 ± 0.12	0.56 ± 0.08*
LVEDV (mL)	0.30 ± 0.36*	0.87 ± 0.26	0.43 ± 0.13*	0.39 ± 0.09*
LVEF (%)	78.91 ± 2.95*	50.86 ± 4.04	64.63 ± 6.88*	72.45 ± 2.67*.#
LVFS (%)	42.76 ± 3.67*	22.27 ± 1.99	32.3 ± 6.32*	36.49 ± 2.17*

LVd: left ventricle diameter; LVDEV: left ventricle end-diastolic volume; LVEF: left ventricle ejection fraction; LVFS: left ventricle shortening fraction. * $P < 0.05$ when compared with MI group; # $P < 0.05$ when compared with Perindopril group.

cate its further employment in the clinical practice.

Materials and methods

Animals and myocardial infarction model

Male Wistar rats (8-12 weeks old and weighed from 200-250 g) were obtained from Center of Disease control in Hubei Providence and were handled in accordance with the standards set forth in the Guide for the Care and Use of Laboratory Animals Edition eight. The protocol was allowed by the Bioethics Broad of Wuhan University. Rats were randomly divided into 4 groups as follows: Group 1 underwent saline injection (n = 6); Group 2 underwent perindopril treatment (n = 7); Group 3 underwent perindopril and BK treatment (n = 7); Group 4 was the rats with sham operation.

Intraperitoneal (IP) injection of 2% pentobarbital sodium (40 mg/kg) (Shanghai second chemical reagent company, China) was used to anaesthetize the rats and endotracheal intubation was used to maintain the airway. The rats were placed in supine position. Myocardial infarction (MI) model was induced by ligation of the left anterior descending coronary artery (LAD). After performing the left thoracotomy, the LAD was ligated by irreversible tightening of a suture loop at a level immediately below the bottom of the left atrium. A successful establishment of coronary occlusion was determined by the presence of typical S-T segment elevation on the electrocardiogram (ECG) and regional myocardial surface cyanosis which was distal to the suture. No LAD ligation was performed in sham operation group.

Drug delivery

Three days post-MI, osmotic mini-pumps (Model No. 2004, Alzet, CA) were implanted subcu-

taneously at the nape of the neck to continuously deliver BK (0.5 µg/h) in MI animals (n = 7); and perindopril (Sigma, St Louis, US) at 2 mg/kg/day was administered in drinking water after LAD ligation.

Echocardiographic analyses

After 4 weeks, all rats were anesthetized and were subjected to echocardiographic analyses. Transthoracic echocardiography was performed using a Sequoia 512 machine (Acuson, Mountain View, CA, US) equipped with 6 MHz cardiac transducer and 7V3 probe. Rabbits were fixed on four limbs in the supine position in a non-narcotic state. Two-dimensional M-mode imaging was taken in the parasternal short and long axis views apical two-chamber and four-chamber views, and left ventricular (LV) long and short axis views. LV end-diastolic diameter (Dd) and systolic diameter (Ds) were measured in the LV long axis view; LV ejection fraction (EF) was determined in the papillary muscle level short axis view; LV end-diastolic volume and LV shortening fraction was automatically calculated as: $LVEDV = [7.0 / (2.4 + D_d)] D_d^3$, $LVFS = [(Dd - Ds) / Dd] \times 100\%$. All values were taken as the mean of triplicate measurements.

Tissue processing

After measurements of cardiac function, the hearts were arrested in diastole with the injection of 10% potassium chloride through the right carotid artery. Then the myocardium was immersed in 10% formalin. The LV chamber was perfused with fixative at a pressure equal to the measured end diastolic pressure in vivo. The measurement of LV intracavitary axis was then performed. The heart was cut into three sections (from the base to the apex of the LV). The section in the middle was used for LV thickness measurement. The endocardium and epicardium of the entire LV and the lengths of the endocardial and epicardial surfaces delimiting the infarcted region were measured in each section. Then, the heart was cut along the short axis and chopped. The tissue blocks from infarct and border zones were separately cryo-sectioned and embedded in paraffin for later use.

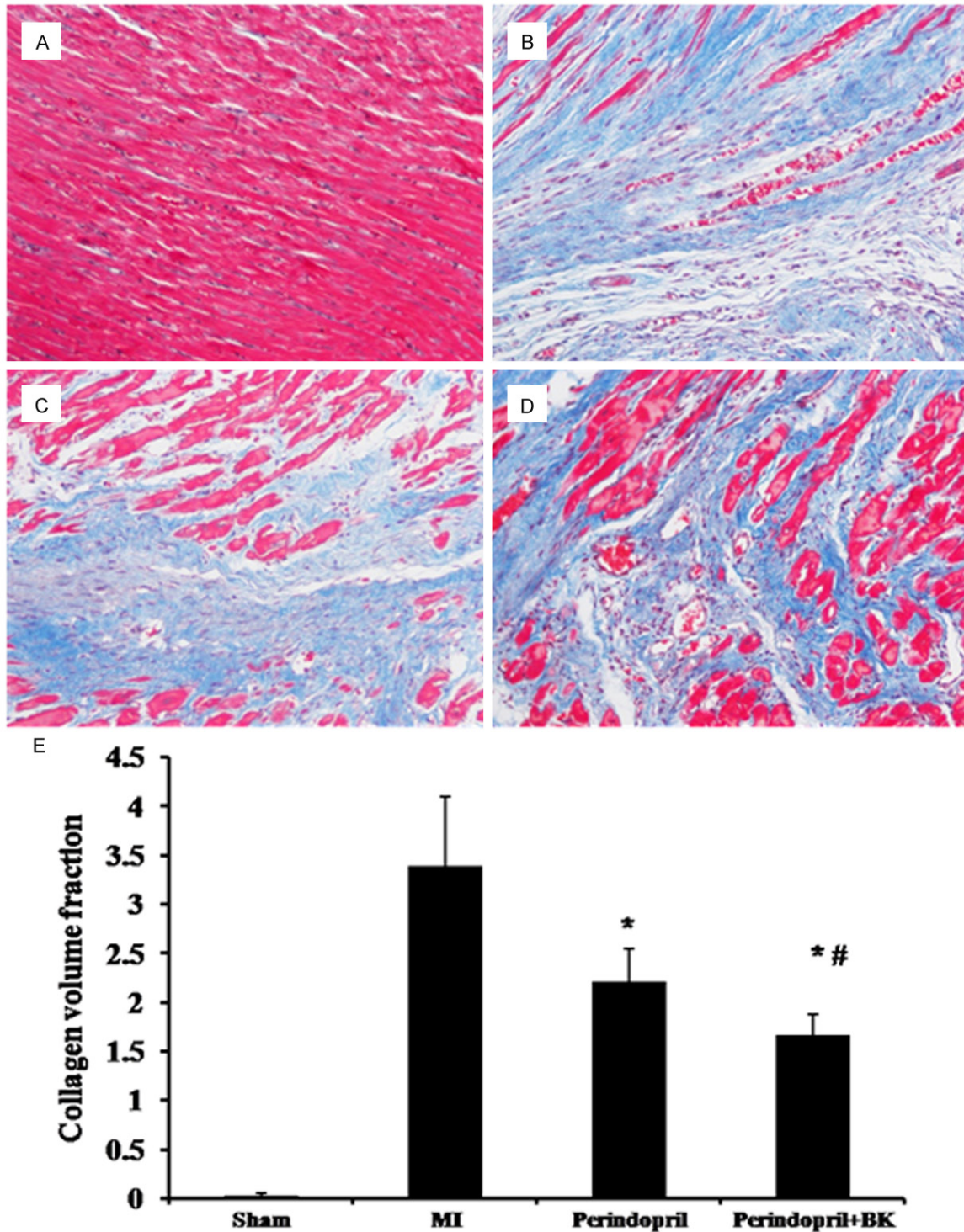


Figure 1. Masson's Trichrome staining of the myocardial tissue. A: MI group (200 ×); B: Perindopril group (200 ×); C: Perindopril + BK group (200 ×); D: Sham group (200 ×); E: Quantification of Collagen volume fraction. *P < 0.05 when compared with MI group while #P<0.05 when compared with Perindopril group.

Hematoxylin and eosin (H&E) and Masson's trichrome staining

The paraffin-embedded sections were cut at a thickness of 3 mm and processed with H&E or

Masson's Trichrome staining. For Masson's Trichrome staining, collagen was in blue, muscle fibers in red, and nucleus in blue-black. The collagen volume fraction was determined according to previous description [5].

Immunohistochemistry

Immunostaining for the endothelial cell marker CD31 with frozen section was employed to determine the extent of capillary formation. Capillaries was regarded when the presence of individual endothelial cells or clusters of endothelial cells, with or without a lumen. Five randomly (each section) picked microscopic fields (400 ×) was used for capillaries and surrounding cardiomyocytes counting.

Statistical analysis

All the statistical analyses were processed by SPSS19.0 software (SPSS Inc. Chicago, IL, US). The data was presented as Mean ± Standard Deviation (SD). One way-ANOVA or Student's t test was employed to examine the difference in two or multiple groups. $P < 0.05$ was recognized as significant difference.

Results

Combination of perindopril and BK improves the cardiac function

Echocardiography was employed to evaluate the cardiac function and the results were shown in **Table 1**. Significant improvement on LVD was found in perindopril + BK group than MI group (0.56 ± 0.08 vs. 0.71 ± 0.12 , $P < 0.05$). On LVEDV, significant decreasing was found in perindopril group (0.43 ± 0.13 vs. 0.87 ± 0.26 , $P < 0.05$) and perindopril + BK group (0.39 ± 0.09 vs. 0.87 ± 0.26 , $P < 0.05$) than that in MI group. A significant increasing on LVEF was also found in perindopril group (64.63 ± 6.88 vs. 50.86 ± 4.04 , $P < 0.05$) and perindopril + BK group (72.45 ± 2.67 vs. 50.86 ± 4.04 , $P < 0.05$) than that in MI group. Moreover, a significant increasing on LVEF was also found in perindopril + BK group than that in perindopril group (72.45 ± 2.67 vs. 64.63 ± 6.88 , $P < 0.05$). On LVFS, a significant improvement was found in perindopril group (32.3 ± 6.32 vs. 22.27 ± 1.99 , $P < 0.05$) and perindopril + BK group (36.49 ± 2.17 vs. 22.27 ± 1.99 , $P < 0.05$).

Combination of perindopril and BK improves the myocardial repair

As depicted in **Figure 1**, Masson's Trichrome staining demonstrated profound myocardial impairment in the infarction region. After perin-

dopril and BK treatment can significant improve the myocardial impairment (**Figure 1C**). The CVF quantification showed that a significant decreasing was found in perindopril + BK group (1.66 ± 0.22 vs. 3.39 ± 0.71 , $P < 0.05$) and perindopril group (2.21 ± 0.33 vs. 3.39 ± 0.71 , $P < 0.05$) than that in MI group. Moreover, a significant decreasing was also found between perindopril + BK group and perindopril group (3.39 ± 0.71 vs. 2.21 ± 0.33 , $P < 0.05$).

Combination of perindopril and BK improves angiogenesis

As shown in **Figure 2**, an improvement on vessel formation was found after perindopril and BK treatment than MI group and perindopril only. Capillaries counting under HPF showed that a significant more number of capillaries was found in perindopril + BK group than MI group (19.6 ± 3.36 vs. 10.4 ± 1.14 , $P < 0.05$) and perindopril group (19.6 ± 3.36 vs. 11.6 ± 1.52 , $P < 0.05$).

Combination of perindopril and BK improves LV wall thickness

As shown in **Figure 3**, a significant improvement on LV wall thickness was found after perindopril and BK treatment (**Figure 3D**) than that in MI group and perindopril group. The quantification data showed the LV wall thickness in perindopril + BK group was significant higher than that in MI group (0.80 ± 0.04 vs. 0.64 ± 0.03 , $P < 0.05$) and perindopril group (0.80 ± 0.04 vs. 0.69 ± 0.04 , $P < 0.05$).

Discussions

In present study, our data revealed that combination treatment with perindopril and BK offered significant beneficial effect in the condition of myocardial infarction, as manifested by the improvements as follows: (1) Perindopril and BK improve ischemic cardiac dysfunction, as reflected by the magnified restoration of the enlarged Dd and LVEDV, and decreased LVEF and LVFS in myocardial infarction. (2) Perindopril and BK improve ischemic myocardial repairmen, as indicated by the synergetic effects against cardiac fibrosis and derangement of myocardial morphology/structure. (3) Perindopril and BK improve angiogenesis in the infarction region. (4) Perindopril and BK improve the LV wall thickness. All these effects point to

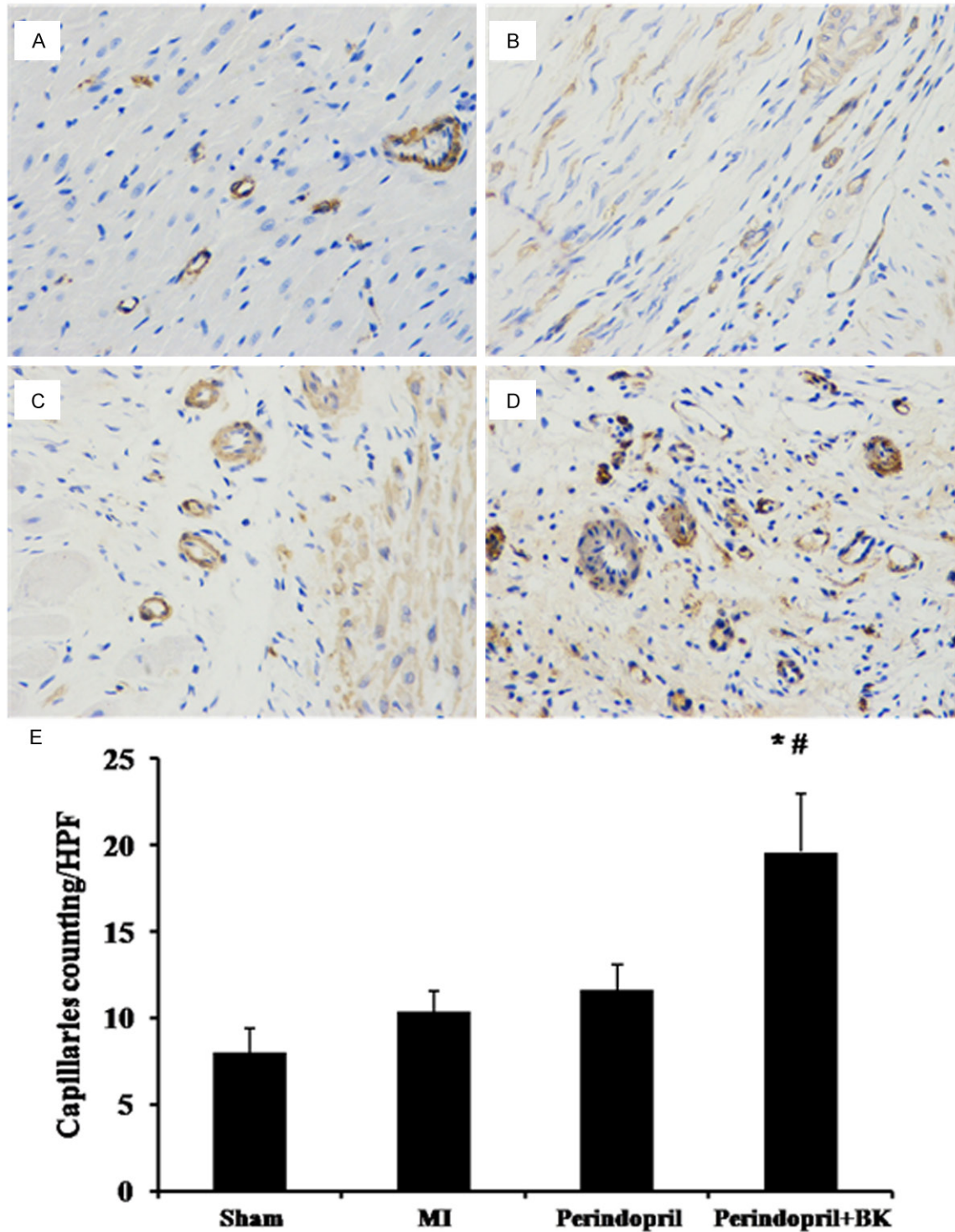


Figure 2. Immunohistochemistry staining of the myocardial tissue by CD31. A: MI group (400 ×); B: Sham group (400 ×); C: Perindopril group (400 ×); D: Perindopril + BK group (400 ×); E: Quantification of capillaries counting under high power field (HPF). * $P < 0.05$ when compared with MI group while # $P < 0.05$ when compared with Perindopril group.

the ability of BK to protect the microenvironment and improve cardiomyocytes leading to

amelioration of cardiac function and myocardial repair in myocardial infarction. Clearly, com-

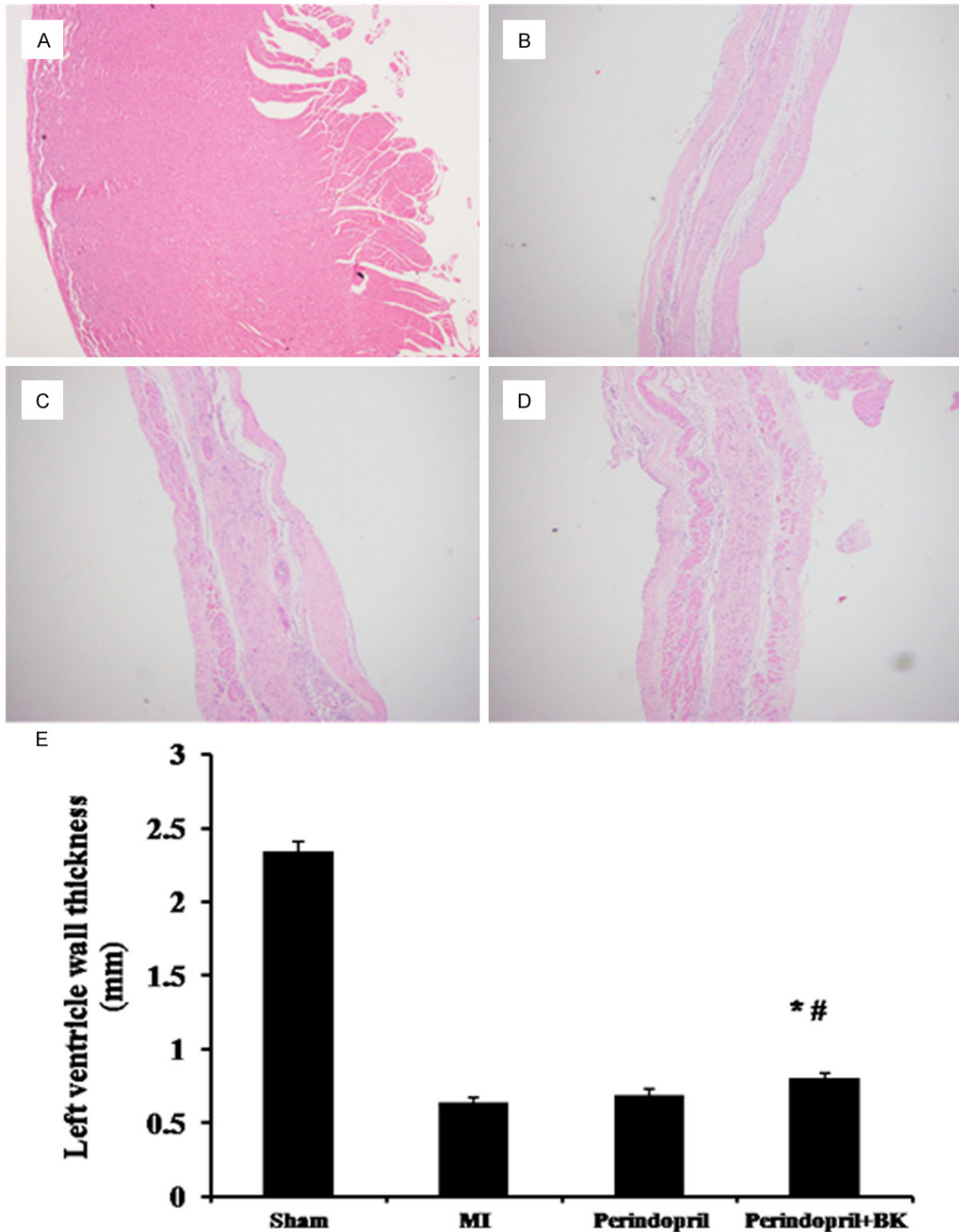


Figure 3. Left ventricle wall thickness determined by hematoxylin and eosin (H&E) staining. A: Sham group (40 ×); B: MI group (40 ×); C: Perindopril group (40 ×); D: Perindopril + BK group (40 ×); E: Quantification of left ventricle wall thickness. * $P < 0.05$ when compared with MI group while # $P < 0.05$ when compared with Perindopril group. Cardioprotection effect exerted by angiotensin-converting enzyme inhibition and bradykinin peptides in rats with myocardial infarction.

Combination treatment with perindopril and BK is a superior therapeutic approach which may merit future preclinical and clinical studies.

Multiple factors such as mechanical, neurohormonal and genetic factor were reported to be involved in LV remodeling [12]. Remodeling

could be considered as a physiological and adaptive process during normal or pathological condition. In the setting of myocardial infarction, an abrupt increase in loading condition caused by loss of myocardium could result in a unique remodeling pattern which involved the infarcted border zone and remote non-infarcted myocardium (Data not shown). Myocyte necrosis and loading increasing trigger an intracellular biochemical signaling cascade, which includes dilatation, hypertrophy, and a discrete collagen scar formation [3]. Previous studies have shown that ACE inhibitors could reduce infarct size after ischemia-reperfusion injury [6]. The decreased abnormalities in LV relaxation and diastolic stiffness as well as attenuated LV hypertrophy and fibrosis could be exerted by perindopril through ACE inhibition. Moreover, combination treatment with perindopril and BK improves the therapeutic effect by perindopril only, which showed a significant improvement on LVEF, some degree of increasing on LVFS and decreasing on LVd and LVEDV.

As a fundamental physiological process, new blood vessels could be generated from pre-existing vasculature under the specific microenvironment [16]. In a pathologic setting such as myocardial infarction, obesity, and diabetes, the insufficient or blunted angiogenic response can be presented [15]. The progression of cardiac hypertrophy has been suggested to be related with the development of a mismatch between capillaries number and cardiomyocytes size which will ultimately lead to myocardial hypoxia [11]. Enhanced or attenuated coronary angiogenesis could be appeared during the acute phase of adaptive cardiac growth or when the heart undergoes pathologic remodeling [9]. Here, we observed a significant increasing on capillaries counting after perindopril and BK treatment while no such effect was found when only performing with perindopril treatment.

For the patients with acute MI, proangiogenic therapy has shown as a promising strategy as de novo formation of microvessels because of its potential for ischemic myocardium salvage at early stages after MI, and the prevention of heart failure transition through the control of cardiomyocyte hypertrophy and contractility [2]. We also found a significant increasing on LV wall thickness after perindopril and BK treatment. By comparing with perindopril only, a sig-

nificant improvement on LV wall thickness was found by combining perindopril with BK.

In addition, previous studies have shown that ACE inhibitor induced capillary density increasing is inhibited in mice lacking the bradykinin B2 receptor [17]. Most of effects of BK was accounted by the bradykinin B2 receptor that constitutively expressed in various tissues [14]. The BK treatment we employed here may serve as signaling amplifier. This may explain the possible mechanism in our study.

Conclusion

In conclusion, we found here is about combination effects with ACE inhibitor perindopril and BK, which can significantly improve the ventricle function in the rat model of myocardial infarction. Our data suggest BK can serve as adjuvant treatment in myocardial infarction treatment and may provide an effective way for the employment of ACE inhibitors for coronary angiogenesis stimulation as part of a general strategy to prevent or reverse the myocardial infarction.

Disclosure of conflict of interest

None.

Address correspondence to: Dr. Yihao Tian, Department of Cardiology, Renmin Hospital of Wuhan University, Wuhan, No. 99 Ziyang Rd, Wuchang 430060, China. Tel: +86-27-68759171; Fax: +86-27-6875-8689; E-mail: yihao.tian01@126.com

References

- [1] Brooks WW, Bing OH, Robinson KG, Slawsky MT, Chaletsky DM, Conrad CH. Effect of angiotensin-converting enzyme inhibition on myocardial fibrosis and function in hypertrophied and failing myocardium from the spontaneously hypertensive rat. *Circulation* 1997; 96: 4002-10.
- [2] Cochain C, Channon KM, Silvestre JS. Angiogenesis in the infarcted myocardium. *Antioxid Redox Signal* 2013; 18: 1100-13.
- [3] Davis J, Molkentin JD. Myofibroblasts: trust your heart and let fate decide. *J Mol Cell Cardiol* 2014; 70: 9-18.
- [4] Ebrahimiyan TG, Tamarat R, Clergue M, Duriez M, Levy BI, Silvestre JS. Dual effect of angiotensin-converting enzyme inhibition on angiogenesis in type 1 diabetic mice. *Arterioscler Thromb Vasc Biol* 2005; 25: 65-70.

- [5] Hayashidani S, Tsutsui H, Shiomi T, Suematsu N, Kinugawa S, Ide T, Wen J, Takeshita A. Fluvastatin, a 3-hydroxy-3-methylglutaryl coenzyme A reductase inhibitor, attenuates left ventricular remodeling and failure after experimental myocardial infarction. *Circulation* 2002; 105: 868-73.
- [6] Kobara M, Tatsumi T, Kambayashi D, Mano A, Yamanaka S, Shiraishi J, Keira N, Matoba S, Asayama J, Fushiki S, Nakagawa M. Effects of ACE inhibition on myocardial apoptosis in an ischemia-reperfusion rat heart model. *J Cardiovasc Pharmacol* 2003; 41: 880-9.
- [7] Lloyd-Jones D, Adams RJ, Brown TM, Carnethon M, Dai S, De Simone G, Ferguson TB, Ford E, Furie K, Gillespie C, Go A, Greenlund K, Haase N, Hailpern S, Ho PM, Howard V, Kissela B, Kittner S, Lackland D, Lisabeth L, Marelli A, McDermott MM, Meigs J, Mozaffarian D, Mussolino M, Nichol G, Roger VL, Rosamond W, Sacco R, Sorlie P, Stafford R, Thom T, Wasserthiel-Smoller S, Wong ND, Wylie-Rosett J; American Heart Association Statistics Committee and Stroke Statistics Subcommittee. Heart disease and stroke statistics—2010 update: a report from the American Heart Association. *Circulation* 2010; 121: e46-e215.
- [8] Mendis S, Thygesen K, Kuulasmaa K, Giampaoli S, Mähönen M, Ngu Blackett K, Lisheng L; Writing group on behalf of the participating experts of the WHO consultation for revision of WHO definition of myocardial infarction. World Health Organization definition of myocardial infarction: 2008-09 revision. *Int J Epidemiol* 2011; 40: 139-46.
- [9] Shiojima I, Sato K, Izumiya Y, Schiekofer S, Ito M, Liao R, Colucci WS, Walsh K. Disruption of coordinated cardiac hypertrophy and angiogenesis contributes to the transition to heart failure. *J Clin Invest* 2005; 115: 2108-18.
- [10] Silvestre JS, Bergaya S, Tamarat R, Duriez M, Boulanger CM, Levy BI. Proangiogenic effect of angiotensin-converting enzyme inhibition is mediated by the bradykinin B (2) receptor pathway. *Circ Res* 2001; 89: 678-83.
- [11] Smiley D, Smith MA, Carreira V, Jiang M, Koch SE, Kelley M, Rubinstein J, Jones WK, Tranter M. Increased fibrosis and progression to heart failure in mrl mice following ischemia/reperfusion injury. *Cardiovasc Pathol* 2014; 23: 327-34.
- [12] Sutton MG, Sharpe N. Left ventricular remodeling after myocardial infarction pathophysiology and therapy. *Circulation* 2000; 101: 2981-8.
- [13] Takii T, Yasuda S, Takahashi J, Ito K, Shiba N, Shirato K, Shimokawa H; MIYAGI-AMI Study Investigators. Trends in acute myocardial infarction incidence and mortality over 30 years in Japan: report from the MIYAGI-AMI Registry Study. *Circ J* 2010; 74: 93-100.
- [14] Tang SC, Leung JC, Lai KN. The kallikrein-kinin system. *Contrib Nephrol* 2011; 170: 145-55.
- [15] Toblli JE, Cao G, DeRosa G, Di Gennaro F, Forcada P. Angiotensin-converting enzyme inhibition and angiogenesis in myocardium of obese Zucker rats. *Am J Hypertens* 2004; 17: 172-80.
- [16] Ucuzian AA, Gassman AA, East AT, Greisler HP. Molecular mediators of angiogenesis. *J Burn Care Res* 2010; 31: 158-75.
- [17] Yoshida J, Yamamoto K, Mano T, Sakata Y, Nishikawa N, Nishio M, Ohtani T, Miwa T, Hori M, Masuyama T. AT1 receptor blocker added to ACE inhibitor provides benefits at advanced stage of hypertensive diastolic heart failure. *Hypertension* 2004; 43: 686-91.