

## Case Report

# A rare case of secretory breast carcinoma in a male adult with axillary lymph node metastasis

Jinhua Ding<sup>1</sup>, Li Jiang<sup>2</sup>, Yongli Gan<sup>3</sup>, Weizhu Wu<sup>1</sup>

<sup>1</sup>Department of Breast and Thyroid Surgery, Ningbo Medical Treatment Center Lihuili Hospital, Ningbo, PR China; <sup>2</sup>Department of Oncology, Ningbo Medical Treatment Center Lihuili Hospital, Ningbo, PR China; <sup>3</sup>Ningbo Pathological and Diagnosis Center, Ningbo, PR China

Received January 12, 2015; Accepted February 28, 2015; Epub March 1, 2015; Published March 15, 2015

**Abstract:** Secretory breast carcinoma is a rare tumor originally described in children but occurring equally in adult population, especially in women. This unusual subtype has a generally favorable prognosis, although several cases have been described in adults with increased aggressiveness and a risk of metastases even death. So far, merely ten cases of secretory breast carcinoma with metastatic axillary lymph node in male were reported. Here, we describe the eleventh case, a 24-years-old male who presented with a painless mass in the right breast was diagnosed to be “secretory breast carcinoma”, and subsequently underwent modified radical mastectomy and adjuvant chemotherapy.

**Keywords:** Secretory breast carcinoma, triple-negative breast carcinoma, prognosis, immunohistochemistry

## Introduction

Secretory breast carcinoma (SBC) is a rare low-grade tumor, it does account for most of the breast carcinomas described in childhood and was first reported as “juvenile breast carcinoma” by McDivitt and Stewart [1] in 1966. In the report, they described seven patients with a range of three to fifteen years, and the average age was just nine years old. Subsequent studies have shown that adults also can be affected by this disease, and the ratio of male to female is 1:6 [2]. Along with more and more adult cases reported, the original term has been replaced by the more appropriate “secretory breast cancer” (SBC) in 1980s (2/3 of approximately of 100 published cases of SBC have been in adult population) [3].

SBC can occur on any quadrant of the breast and frequently below the mammary areola. It always presents as a mobile, well-circumscribed mass, sometimes resembling a fibroadenoma [2, 4]. Ultrasonography is ideally suited to the evaluation of breast mass, especially in male [5-7]. The histology may include ductal, solid, microcystic, or mixed patterns and tumor cells demonstrate minimal atypia and rare

mitotic activity [8]. Tumor cells are characterized by a granular eosinophilic cytoplasm and show abundant intra- and extracellular secretion of material, which is PAS-positive. SBC are generally negative for estrogen and progesterone receptors, have a low proliferation index. Recent studies have demonstrated that SBC has a specific molecular and genetic marker, characterized by the presence of a chromosomal translocation t(12;15) that results in the expression of a chimeric tyrosine kinase, encoded by the ETV6-NTRK3 fusion gene [9, 10].

To our knowledge, there have been 29 previous reports of SBC in male (**Table 1**). Ten cases with axillary lymph node metastasis were described, and only three cases were adults over 20 years old. The objective of this article is to draw more attention to the diagnosis of breast mass in male adults and to the treatment options for this unusual type.

## Case report

A 24-years-old Chinese male presented to our department presented with a mass in the right breast which had been discovered four months previously. The mass had gradually increased

## Secretory breast carcinoma in male adult

**Table 1.** Data on 30 male patients with secretory breast cancer

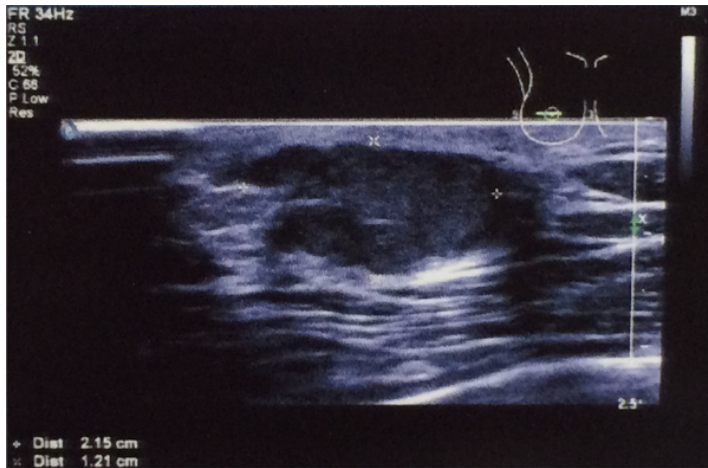
Author	Year	Age	Duration symptom	size (mm)	Axillary status	Treatment	Hormone Receptors	Follow up
Simpson [11]	1969	5	ND	ND	-(clinical)	LE	ND	NED 4 y
Tavassoli [3]	1980	9	ND	ND	-(clinical)	LE	ND	ND 1.75 y
Karl [12]	1985	3	1 month	15	+(1/4)	SM+ALND	ND	ND
Roth [13]	1988	23	21 y	20	-(0/21)	MRM	ND	NED 4 y
Krausz [14]	1989	24	many years	40	ND	SM+RT	ND	DOD 20 y
Serour [15]	1992	17	4 y	15	-(0/3)	WLE+ALND	ER- PR+	NED 5 y
Lamovec [16]	1994	20	ND	12	-(0/?)	MRM	ER+ PR+	NED 1 y
Pohar-Marinsek [17]	1994	20	6-7 y	12	-(clinical)	SM	ER+ PR+	NED 6 m
Kuwabara [18]	1988	66	3 y	30	+(2/?)	MRM	ER- PR+	NED 8 m
Vesoulis [19]	1998	33	10 y	15	ND	MRM	ER+ PR+	ND
Kameyama [20]	1998	50	ND	30	-(0/?)	MRM	ER+	ND
Chevallier [21]	1999	9	14 m	20	-(0/?)	LE+ALND	ER- PR-	NED 45 m
Yildirim [22]	1999	11	1 y	15	+(1/18)	MRT+CT+RT	ER -	NED 12 m
Bhagwandeem [23]	1999	9	1 m	12	-(0/15)	MRM	ER- PR-	NED 20 m
De Bree [24]	2001	17	2 y	30	-(0/14)	MRM	ER- PR-	NED 9 m
Diallo [25] <sup>a</sup>	2003	74	74 y	8	+(clinical)	LE	ER- PR-	DTD
Woto-Gaye [26]	2004	20	2.4 y	125	+(6/?)	MRM+CT	ND	DOD 11 m
Kavalakat [27] <sup>b</sup>	2004	17	6 m	60	+(10/12)	CT+MRM+RT+HT	ER-	NED 13 m
Niveditha [28] <sup>c</sup>	2004	19	2 y	40, 20	ND	LE	ER- PR-	ND
Szántó [29]	2004	7.5	6 m	17	-(0/?)	RM+SLNB	ER- PR-	NED 7 m
Grabellus [30] <sup>d</sup>	2005	46	ND	35	ND	LE	ER- PR-	ND
Arce [31]	2005	52	10 y	70	+(2/24)	MRM+CT	ER- PR-	NED 25 m
Alenda [32]	2005	79	ND	30	-(0/?)	MRM	ER- PR-	ND
Iglesias [33]	2009	63	1 y	20	+(1/10)	SM+ALND	ER- PR-	ND
Gabal [34]	2010	19	9 m	20	+(5/19)	SM+ALND	ER + PR-	AWD
Cabello [35]	2011	13	4 y	15	+(1/28)	SSM+ALND+CT	ER- PR-	NED 10 y
Li [36]	2012	10	0.5 m	20	-(0/11)	MRM	ER- PR-	NED 12 m
Li [36]	2012	18	5 y	25	+(2/17)	MRM+CT	ER- PR-	NED 13 m
Din [37]	2012	35	ND	25	-(clinical)	LE	ND	ND
This case	2014	24	2 m	20	+(1/26)	MRM+CT	ER- PR-	NED 2 m

Abbreviations: ND: no defined, LE: Local excision, MRM: Modified Radical Mastectomy, CT: chemotherapy, RT: Radiotherapy, NE: not examined, NED: not evidence of disease, AWD: Alive with disease, ER: estrogen receptor, PR: progesterone receptor. SM: simple mastectomy, ALNS: axillary lymph node sampling, ALND: axillary lymph node dissection, WLE: wide local excision, DOD: Died of disease. DTD: Died at the time of diagnosis. SSM: Skin-sparing mastectomy. <sup>a</sup>The patient had multifocal tumors. <sup>b</sup>The patient underwent excision of a mass 2 years ago, then developed a recurrence on the same site within 6 months. <sup>c</sup>The patient underwent a massectomy in the right breast, and then two small mass reappeared on the right chest wall 3 months after surgery. <sup>d</sup>The patient was a male-to-female transsexual.

slightly in volume during the intervening period. Family history was denied but a nodule in right breast was removed in his childhood. At physical examination, a radial scar over 20-mm was on the out upper quadrant of the right breast, and the palpable mass was painless, with lobulated shape, and increased in density, extended for 20 mm in diameter. There was neither nipple discharge nor dented, nor clinical evidence of lymph node enlargement in ipsilateral or contralateral armpit. Ultrasonography showed a hypoechoic mass with homogeneous

echo texture on the out upper quadrant of the right breast, approximately 20×25 mm (**Figure 1**).

Serum tumor markers and other routine blood test were normal. The liver ultra-sonography, lung computed tomography were negative for metastases. Following the patient's request, core needle biopsy of the tumor was not performed and the mass was therefore immediately removed under local anaesthetic. Regrettably, the mass was diagnosed to be "secretory



**Figure 1.** Breast ultrasonography showing a 20×25 mm, lobulated, irregularly shaped hypoechoic lesion on the out upper quadrant of the right breast.

breast carcinoma” during the operative histopathology. So modified radical mastectomy (MCM) under general anaesthetic was therefore performed during a subsequent operation.

Grossly, the mass was about 25×20 mm, firm, lobulated, and had white glistening cut section. Microscopy examination showed the classical features of secretory carcinoma with microcystic pattern (**Figure 2A**) with abundant intra- and extracellular secretory material (**Figure 2B**), which was PAS positive (**Figure 2C**). The tumor cells were mostly bland looking with round or oval nuclei and had few scattered nucleoli. No tumor cell infiltration was present at the nipple or at surgical margins. 1 of 26 resected lymph nodes were positive for metastatic carcinoma displayed a growth pattern similar to the primary tumor with abundant secretion (**Figure 2D**). On immunohistochemistry, the tumor cells were positive for EMA (**Figure 2E**), S-100 (**Figure 2F**) and low Ki-67 expression (5%), negative for ER, PR and HER2.

The patient received adjuvant chemotherapy consisting of four cycles of Epirubicin and cyclophosphamide plus four cycles of docetaxel, and radiation therapy wasn't planned.

## Discussion

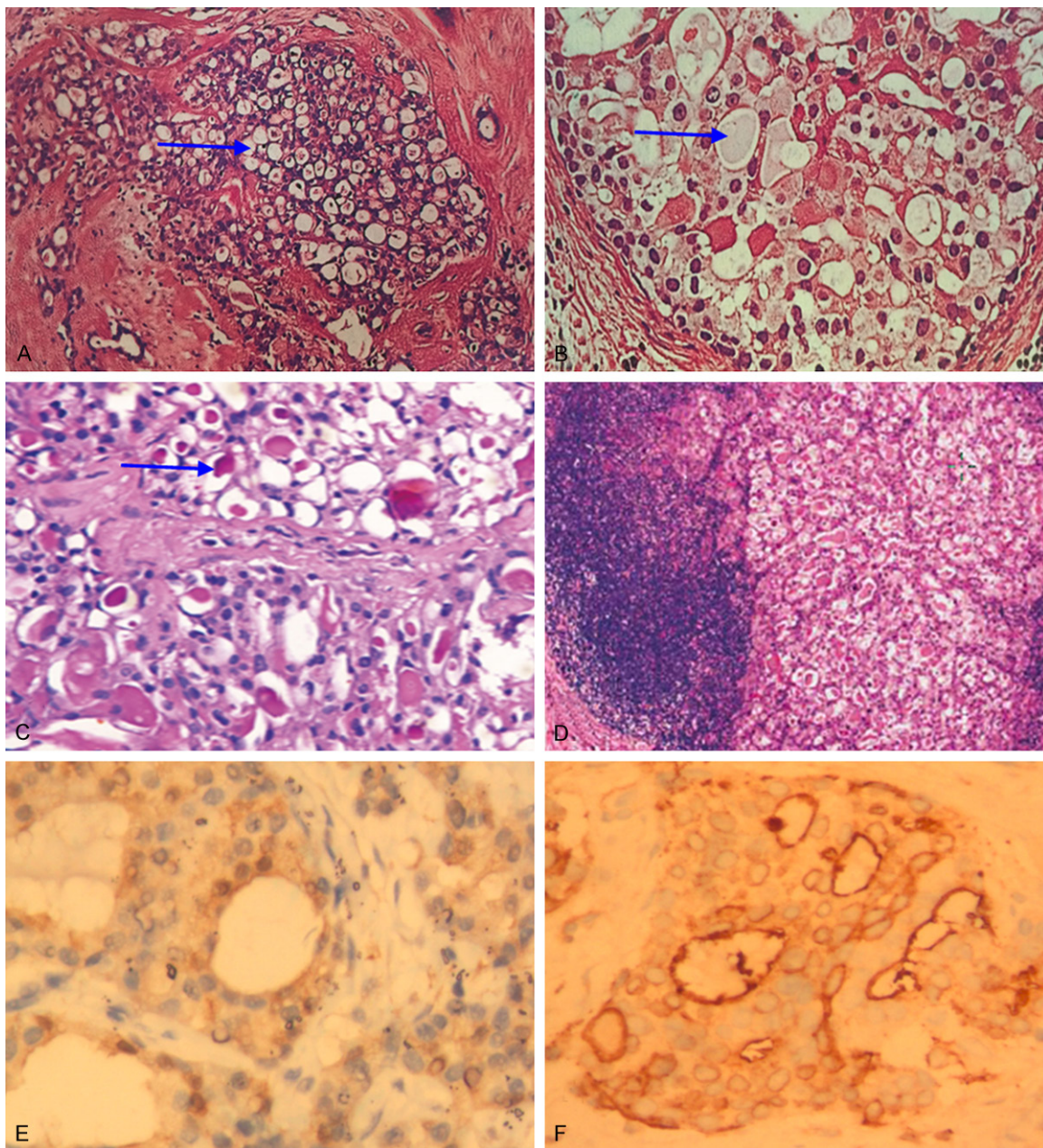
Secretory carcinoma is a rare form of breast cancer, generally with a favorable prognosis. There is no consensus of opinion as to how SBC should be treated, as there are so few case

reports of SBC in the literature. Since very few cases of secretory carcinoma have been described in literature, it is imperative to report any new cases observed in order to establish the most suitable therapeutic approach. Here, we report a case of 24-year-old male patient with secretory breast carcinoma who presented with a painless mass in right breast, and subsequently underwent modified radical mastectomy. We chose to administer adjuvant chemotherapy consisting of four cycles of Epirubicin and cyclophosphamide plus four cycles of docetaxel.

To the best of our knowledge, A total of thirty cases (include one case from our report, see **Table 1**) of male patients with secretory breast carcinoma could be identified in the literature [3, 11-37]. The age of male patients varies from 3 to 79 years old with a median age of nineteen years old [12, 32]. Nine SBC are boys under 14 years old, four are adolescents, and seventeen are adult males. An asymptomatic, firm mass is the most frequent clinical presentation. The tumors are usually located below mammary areola. Tumor size varies from 8 to 125 mm, with an average diameter of approximately 27 mm [25, 26]. The duration of symptoms varies from 2 weeks to 21 years, with a median time of approximately 12 months [13, 36]. Nearly half (11 of 23, 47.8%) of the reported cases with axillary lymph node metastasis were confirmed by pathological examination, and the rate was higher than that of female SBC, with a range from 20% to 30% [24, 29, 38, 39]. No more than two lymph nodes were involved in most (8 of 11, 72.7%) cases. The status of ER and PR was known in 23 cases, and most (16 of 23, 69.6%) of cases were ER and PR negative, three (3 of 23, 13.0%) of cases were ER and PR positive, other four (4 of 23, 17.4%) of case were ER or PR positive.

There is no consensus of opinion as to how SBC should be treated, as there are so few case reports of SBC in the literature. However, surgery is thought to be the primary mode of treatment for this type of breast carcinoma. Obviously, there are many differences between male and female patients. Firstly, the volume of breast tissue in male is much less compared to female, when the tumor is completely removed;





**Figure 2.** A. Show microcystic pattern composed of small cysts (blue arrow) and larger spaces containing abundant pink eosinophilic secretions (hematoxylin-eosin, original magnification  $\times 100$ ). B. Secretory breast carcinoma with intracellular and extracellular secretory material (blue arrow, hematoxylin-eosin, original magnification  $\times 200$ ). C. Secretory material is PAS positive (blue arrow, hematoxylin-eosin, original magnification  $\times 400$ ). D. The metastatic carcinoma in axillary lymph node, displaying a growth pattern similar to the primary tumor with abundant secretion (hematoxylin-eosin, original magnification  $\times 100$ ). E and F. The tumor cells show positive nuclear and cytoplasmic staining by S100 antibody and positive cytoplasmic staining by EMA antibody (original magnification  $\times 200$ ).

there is scarcely breast tissue left. Secondly, breast is just one part of body as for male; while breast means not only a sexy organ, but also confidence, perfect and so on. Finally, radiation therapy is extremely necessary for patients who receive breast conserving surgery. Meanwhile, radiation therapy may bring about some

severe adverse effect and there is a risk for future development of neoplasm. For preserving the breast, female patients are willing to accept this venture while male not. So male patients are more likely to choose mastectomy instead of breast-conserving surgery, which can be seen from **Table 1**. Eight (8 of 30, 26.7%)

cases received local excision or wide local excision without whole breast radiation, while twenty two (22 of 30, 73.7%) cases received mastectomy, and all of patients with axillary lymph node metastasis received mastectomy. In addition, the ratio of lymph node metastasis in male patients was higher than overall population, so they seem to be willing to accept axillary lymph node dissection (ALND). In the literature and our case, there were twenty two (22 of 30, 73.7%) cases in which the status of axillary lymph node was evaluated, and only one of twenty two cases received sentinel lymph node biopsy (SLNB) [29].

SBC is a low-grade triple-negative(ER-/PR-/HER2-) carcinoma that expresses basal cell markers [9, 40]. However, it is genetically unique and is associated with a better prognosis than other basal-like tumors [9]. There is insufficient evidence to recommend adjuvant chemotherapy for this secretory breast carcinoma [2, 15, 29]. However, Adjuvant chemotherapy has been used [9, 41-43] predominantly in node-positive patients. In one case report, a patient with a single positive lymph node responded to traditional chemotherapy consisting of six cycles of cyclophosphamide, methotrexate and 5-fluoro-uracil, with no evidence of local or distant disease after seven years of follow-up [42]. Although chemotherapy can cause potential reproductive risks, according to NCCN guidelines, even some favorable histologies of breast carcinoma (such as tubular carcinoma, mucinous carcinoma) which are ER-and PR-negative should be treated as typical breast cancer.

In conclusion, SBC is a very rare tumor, especially in male, and there is no consensus with regard to the optimal treatment strategy. We believe that this report will add information regarding its knowledge and management.

## Disclosure of conflict of interest

None.

**Address correspondence to:** Dr. Weizhu Wu, Department of Breast and Thyroid Surgery, Ningbo Medical Treatment Center Lihui Hospital, Ningbo, PR China. E-mail: 1144184462@qq.com

## References

[1] McDivitt W, Stewart FW. Breast carcinoma in children. *JAMA* 1966; 195: 144-146.

[2] Herz H, Cooke B, Goldstein D. Metastatic secretory breast cancer. Non-responsiveness to chemotherapy: case report and review of the literature. *Ann Oncol* 2000; 11: 1343-1147.

[3] Tavassoli FA, Norris HJ. Secretory carcinoma of the breast. *Cancer* 1980; 45: 2404-2413.

[4] Costa NM, Rodrigues H, Pereira H, Parda F, Matos E. Secretory breast carcinoma-case report and review of the medical literature. *Breast* 2004; 13: 353-355.

[5] Garcí'a CJ, Espinoza A, Dinamarca V, Navarro O, Daneman A, Garcí'a H, Cattani A. Breast US in children and adolescents. *Radiographics* 2000; 20: 1605-1612.

[6] Weinstein SP, Conant DF, Orel SG, Zuckerman JA, Bellah R. Spectrum of US findings in pediatric and adolescent patients with palpable breast masses. *Radiographic* 2000; 20: 1613-1621.

[7] Chung EM, Cube R, Hall GF, Gonzá'lez C, Stocker FT, Glassman LM. From the archives of the AFIP: breast masses in children and adolescents: radiologic-pathologic correlation. *Radiographics* 2009; 29: 907-931.

[8] Khalbuss WE. Cytomorphology of rare malignant tumors of the breast. *Clin Lab Med* 2005; 25: 761-775.

[9] Laè M, Frèneaux P, Sastre-Garau X, Chouchane O, Sigal-Zafrani B, Vincent-Salomon A. Secretory breast carcinomas with ETV6-NTRK3 fusion gene belong to the basal-like carcinoma spectrum. *Modern Pathology* 2009; 22: 291-298.

[10] Chiosea SI, Griffiyh C, Assaad A, Seethala RR. The profile of acinic cell carcinoma after recognition of mammary analog secretory carcinoma. *Am J Surg Pathol* 2012; 36: 343-350.

[11] Simpson JS, Barson AJ. Breast tumours in infants and children: a 40-year review of cases at a children's hospital. *Can Med Assoc J* 1969; 101: 100-102.

[12] Karl SR, Ballantine TV, Zaino R. Juvenile secretory carcinoma of the breast. *J Pediatr Surg* 1985; 20: 368-371.

[13] Roth JA, Discafani C, O'Malley M. Secretory breast carcinoma in a man. *Am J Surg Pathol* 1988; 12: 150-154.

[14] Krausz T, Jenkins D, Grontoft O, Pollock DJ, Azzopardi JG. Secretory carcinoma of the breast in adults: emphasis on late recurrence and metastasis. *Histopathology* 1989; 14: 25-36.

[15] Serour F, Gilad A, Kopolovic J, Krispin M. Secretory breast cancer in childhood and adolescence: report of a case and review of the literature. *Med Pediatr Oncol* 1992; 20: 341-344.

[16] Lamovec J, Bracko M. Secretory carcinoma of the breast: light microscopical, immunohistochemical and flow cytometric study. *Mod Pathol* 1994; 7: 475-479.



- [17] Pohar-Marinsek Z, Golouh R. Secretory breast carcinoma in a man diagnosed by fine needle aspiration biopsy. A case report. *Acta Cytol* 1994; 38: 446-450.
- [18] Kuwabara H, Yamane M, Okada S. Secretory breast carcinoma in a 66 year old man. *J Clin Pathol* 1998; 51: 545-547.
- [19] Vesoulis Z, Kashkari S. Fine needle aspiration of secretory breast carcinoma resembling lactational changes. A case report. *Acta Cytol* 1998; 42: 1032-1036.
- [20] Kameyama K, Mukai M, Iri H, Kuramochi S, Yamazaki K, Ikeda Y, Hata J. Secretory carcinoma of the breast in a 51-year-old male. *Pathol Int* 1998; 48: 994-997.
- [21] Chevallier A, Boissy C, Rampal A, Soller C, Turc-Carel C, Thyss A, Michiels JF. Secretory carcinoma of the breast. Report of a case in a 9-year-old boy. *Clin Exp Pathol* 1999; 47: 88-91.
- [22] Yildirim E, Turhan N, Pak I, Berberolu U. Secretory breast carcinoma in a boy. *Eur J Surg Oncol* 1999; 25: 98-99.
- [23] Bhagwande BS, Fenton L. Secretory carcinoma of the breast in a nine year old boy. *Pathology* 1999; 31: 166-168.
- [24] de Bree E, Askoxylakis J, Giannikaki E, Chroniaris N, Sanidas E, Tsiftsis DD. Secretory carcinoma of the male breast. *Ann Surg Oncol* 2002; 9: 663-667.
- [25] Diallo R, Tognon C, Knezevich SR, Sorensen P, Poremba C. Secretory carcinoma of the breast: a genetically defined carcinoma entity. *Verh Dtsch Ges Pathol* 2003; 87: 193-203.
- [26] Woto-Gaye G, Kasse AA, Dieye Y, Toure P, Demba Ndiaye P. Secretory breast carcinoma in a man. A case report with rapid evolution unfavorable. *Ann Pathol* 2004; 24: 432-435, quiz 393.
- [27] Kavalakat AJ, Covilakam RK, Culas TB. Secretory carcinoma of breast in a 17-year-old male. *World J Surg Oncol* 2004; 2: 17.
- [28] Niveditha SR, Bajaj P, Nangia A. Secretory carcinoma of the male breast. *J Clin Pathol* 2004; 57: 894.
- [29] Szántó J, András C, Tsakiris J, Gomba S, Szentirmay Z, Bánlaki S, Szilágyi I, Kiss C, Antall P, Horváth A, Lengyel L, Castiglione-Gertsch M. Secretory breast cancer in a 7.5-year old boy. *Breast* 2004; 13: 439-442.
- [30] Grabellus F, Worm K, Willruth A, Schmitz KJ, Otterbach F, Baba HA, Kimmig R, Metz KA. ETV6-NTRK3 gene fusion in a secretory carcinoma of the breast of a male-to-female transsexual. *Breast* 2005; 14: 71-74.
- [31] Arce C, Cortes-Padilla D, Huntsman DG, Miller MA, Dueñas-Gonzalez A, Alvarado A, Pérez V, Gallardo-Rincón D, Lara-Medina F. Secretory carcinoma of the breast containing the ETV6-NTRK3 fusion gene in a male: case report and review of the literature. *World J Surg Oncol* 2005; 3: 35.
- [32] Alenda C, Aranda FI, Segui FJ, Laforga J. Secretory carcinoma of the male breast: correlation of aspiration cytology and pathology. *Diagn Cytopathol* 2005; 32: 47-50.
- [33] Iglesias B, Monteagudo B, Rouco JS, Antón I. Secretory breast carcinoma in a 63-year-old man. *J Cutan Pathol* 2009; 36 Suppl 1: 86-88.
- [34] Gabal S, Talaat S. Secretory carcinoma of male breast: case report and review of the literature. *Int J Breast Cancer* 2011; 2011: 704657.
- [35] Cabello C, Alvarenga M, Alvarenga CA, Duarte GM, Pereira PN, Marshall PS. Case report and review of the literature: Secretory breast cancer in a 13-year-old boy-10 years of follow up. *Breast Cancer Res Treat* 2012; 133: 813-820.
- [36] Li D, Xiao X, Yang W, Shui R, Tu X, Lu H, Shi D. Secretory breast carcinoma: a clinicopathological and immunophenotypic study of 15 cases with a review of the literature. *Modern Pathology* 2012; 25: 567-575.
- [37] Din NU, Idrees R, Fatima S, Kayani N. Secretory carcinoma of breast: clinicopathologic study of 8 cases. *Ann Diagn Pathol* 2013; 17: 54-57.
- [38] Vieni S, Cabibi D, Cipolla C, Fricano S, Graceffa G, Latteri MA. Secretory breast carcinoma with metastatic sentinel lymph node. *World J Surg Oncol* 2006; 4: 88.
- [39] Richard G, Hawk JC 3rd, Baker AS Jr, Austin RM. Multicentric adult secretory breast carcinoma: DNA flow cytometric findings, prognostic features, and review of the world literature. *J Surg Oncol* 1990; 44: 238-244.
- [40] Lambros MB, Tan DS, Jones RL, Vatcheva R, Savage K, Tamber N, Fenwick K. Genomic profile of a secretory breast cancer with an ETV6-NTRK3 duplication. *J Clin Pathol* 2009; 62: 604-612.
- [41] Ozguroglu M, Tascilar K, Ilvan S, Soybir G, Celik V. Secretory carcinoma of the breast. Case report and review of the literature. *Oncology* 2005; 68: 263-268.
- [42] Vieni S, Cabibi D, Cipolla C, Fricano S, Graceffa G, Latteri MA. Secretory breast carcinoma with metastatic sentinel lymph node. *World J Surg Oncol* 2006; 4: 88.
- [43] Costa NM, Rodrigues H, Pereira H, Pardal F, Matos E. Secretory breast carcinoma—case report and review of the medical literature. *Breast* 2004; 13: 353-355.