

Original Article

Anti-inflammatory and antioxidant effects of curcumin on acute lung injury in a rodent model of intestinal ischemia reperfusion by inhibiting the pathway of NF- κ B

Zhe Fan¹, Jihong Yao², Yang Li³, Xiaowei Hu², Huizhu Shao², Xiaofeng Tian⁴

¹Department of General Surgery, The Third People's Hospital of Dalian, Dalian 116033, China; ²Department of Pharmacology, Dalian Medical University, Dalian 116044, China; ³Department of General Surgery, Liaoning Cancer Hospital and Institute, Shenyang 110042, China; ⁴Department of General Surgery, The Second Hospital of Dalian Medical University, Dalian 116023, China

Received December 6, 2014; Accepted March 20, 2015; Epub April 1, 2015; Published April 15, 2015

Abstract: Objective: To investigate the anti-inflammatory and antioxidant effect of curcumin on lung lesion induced by intestinal ischemia reperfusion injury (IIR). Methods: Rats were divided into four groups: sham, intestinal IIR (IIR), 1 mg/kg of curcumin treatment group (1 mg/kg), and 5 mg/kg of curcumin treatment group (5 mg/kg). Curcumin was given respectively (1 mg/kg and 5 mg/kg) following the above doses. IIR was produced by 1 h of intestinal ischemia followed by 2 h of reperfusion. Rats were sacrificed at the end of reperfusion and lung tissues were collected for biochemical and histopathological examination in 4 groups. Lung tissues histology and bronchoalveolar lavage fluid (BALF) protein were assayed. Serum IL-6, lung superoxide dismutase (SOD) and myeloperoxidase (MPO) were measured. The expression level of NF- κ B and ICAM-1 (including immunohistochemical analysis and western blot analysis) were also measured. Results: Lung tissue injury induced by IIR was obviously observed through pathology and BALF protein. MPO activity, IL-6 level and ICAM-1 expression were significantly increased with the elevation of NF- κ B, simultaneously, SOD activity was decreased. With Treatment of curcumin, pathology and BALF protein of lung tissue were improved clearly. Inflammatory indexes (MPO activity, IL-6 level and ICAM-1) were improved and antioxidant index (SOD activity) was enhanced paralleled with NF- κ B. Conclusion: Using curcumin effectively prevented IIR-induced lung injury. Anti-inflammatory and antioxidant effects of curcumin could be observed by inhibiting the pathway of NF- κ B.

Keywords: Curcumin, intestinal ischemia reperfusion, lung injury, NF- κ B

Introduction

Intestinal ischemia reperfusion (IIR) often is a fatal clinical problem, which could occur in the setting of various clinical situations, including necrotizing enterocolitis, midgut volvulus, intussusception, mesenteric ischemia, hemorrhagic, abdominal aortic aneurysm, small bowel transplantation and septic shock [1, 2].

IIR could lead to severe intestine damage, and could induce subsequent destruction of remote organs including liver, lung, and kidney as well [3]. In the process of IIR, intestine barrier dysfunction and bacterial translocation, resulting in inflammatory cytokine release, reactive oxygen species (ROS) overproduction, and even apoptosis [4]. Numerous mediators such as the

above were released into circulation so that multiple organ failure including acute lung injury (ALI) and acute respiratory distress syndrome (ARDS) happens [1]. Our previous study has demonstrated NF- κ B pathway involved in the pathogenesis of lung injury induced by IIR and Many anti-oxidants has been proved to eliminate lung lesion from IIR such as carnosol, lactacystin and PDTTC [5-7].

Curcumin is a dietary antioxidant derived from turmeric and the antiinflammatory, antimicrobial, antiviral, antifungal, antioxidant, chemosensitizing, radiosensitizing effects and wound healing activities have been proved [2, 8, 9].

There have been three articles reporting the protective function of curcumin on acute lung

Effects of curcumin on acute lung injury in intestinal ischemia reperfusion

lesion induced by IIR [2, 8, 10]. However, none of them illuminates role of inhibiting the pathway of NF- κ B about curcumin. In the present study, we have further illuminated mechanism of curcumin in IIR.

Materials and methods

Animals and surgical procedure

Male Wistar rats (from the Animal Center of Dalian Medical University, Dalian, China) weighing 200-240 g were selected for this study. All procedures were carried out according to the Institutional Animal Care and Use Committee guidelines and approved by the Institutional Ethics Committee. Twenty six male rats were housed at a constant temperature ($22\pm 2^\circ\text{C}$) and with 12 hour (h) light and dark cycles. All animals were housed in cages with food and water libitum. All rats were randomly divided into four groups: sham, Intestine ischemia reperfusion (IIR), 1 mg/kg of curcumin treatment groups (1 mg/kg), and 5 mg/kg of curcumin treatment groups (1 mg/kg) (n=6 in each group).

Model of rats IIR was established according to the standardized methods [11].

(1) Sham group, with surgical preparation and superior mesenteric artery (SMA) without occlusion.

(2) IIR group: 1 h intestinal ischemia and 2 h reperfusion.

(3) 1 mg/kg group: 1 h intestinal ischemia and 2 h reperfusion with 1 mg/kg of curcumin treatment.

(4) 5 mg/kg group: 1 h intestinal ischemia and 2 h reperfusion with 5 mg/kg of curcumin treatment.

The 1 mg/kg and 5 mg/kg group's rats underwent surgery with let femoral vein administration of curcumin (Shanghai Usea Biotech Company, China) after occlusion for 50 min. The dosages of curcumin were based on previous study [3]. The sham group and IIR group animals were followed the same procedure with an equal volume of normal saline solution. All rats were sacrificed after 2 h of reperfusion. Blood samples and lung tissues were obtained for respectively analysis.

Lung histology

The right middle lobe of the lung was harvested and was fixed in 40 g/L formaldehyde. After 4 μm sections had been embedded in paraffin, they were stained with hematoxylin and eosin for light microscopy. Pathological injury score was evaluated blindly according to Mikawa's method [12].

Pathological scores (lung damage) were evaluated by (a) alveolar congestion; (b) hemorrhage; (c) neutrophilic infiltration and (d) thickness of the alveolar wall and hyaline membrane formation. Each item was graded on a 5-point scale (0, minimal damage; 1, mild damage; 2, moderate damage; 3, severe damage; 4, maximal damage) [13].

Bronchia alveolus lung fluid (BALF) assay

BALF was gathered according to the process of Cox [14]. After being centrifuged at 1000 rpm/min for 10 min, the protein from the tissues was measured using assay kit (Nanjing Jincheng Corp., China) following the manufacturer's instructions and expressed as g/L.

Serum IL-6 assay

The serum level of IL-6 was determined using commercially available enzyme-linked immunosorbent assay (ELISA) kits (BOSTER Bio-Engineering Limited Company, Wuhan, China).

Lung SOD and MPO assay

The right base lobe of lung tissues was harvested and immediately homogenized on ice-surface in 5 volumes of normal saline. The homogenates were centrifuged at 1200 rpm/min for 10 min. The superoxide dismutase (SOD) and myeloperoxidase (MPO) content in the supernatants were respectively measured using (SOD) and MPO assay kit (Nanjing Jincheng Corp., China).

Lung ICAM-1 and NF- κ B immunohistochemical analysis

Lung tissues were stained by streptavidin/peroxidase immunohistochemistry technique for intercellular adhesion molecule-1 (ICAM-1) and after formalin-fixed and paraffin-embedded. The immunohistochemical tests were performed following the manufacturer's instructions. 4-micrometer sections were treated with

Effects of curcumin on acute lung injury in intestinal ischemia reperfusion

0.3% H₂O₂ in methanol to block endogenous peroxidase activity and then incubated with the polyclonal rabbit anti-rat ICAM-1 antibody (Wuhan Boster Biological Technology Co., Ltd, Wuhan, China, both 1:500 dilution). Then Biotinylated anti-rabbit immunoglobulin was added as a secondary antibody. The horseradish peroxidase labeled streptomycin avidin complex was used to detect the second antibody. Ultimately, color development was carried out by 3, 3'-diaminobenzidine and hematoxylin was used for counter staining. The brown or dark brown stained cells were considered as positive. The index was evaluated semi-quantitatively according to former experiments [6].

NF- κ B immunohistochemical was followed the similar procedure and the difference was polyclonal rabbit anti-rat NF- κ B antibody (Wuhan Boster Biological Technology Co., Ltd, Wuhan, China, both 1:500 dilution).

Western blot analysis of NF- κ B

Nuclear protein was extraction from frozen lung tissues using a protein extraction kit reagent (Beyotime, Shanghai, China) and each 15 μ g aliquot of them was separated by 10% SDS-PAGE gel electrophoresis. The protein extracted from lung was electroblotted onto NC membranes (Millipore, Bedford, MA, USA) at 9 V for 30 min.

The transferred membranes were then incubated overnight at 4°C with rabbit polyclonal antibody NF- κ B (Santa Cruz Biotechnology, CA, USA) and Histone H3.1 (Santa Cruz Biotechnology) against rat in TBS-T (10 mmol/L Tris-HCl, pH 7.5, 150 mmol/L NaCl, 0.1% Tween-20) containing 5% skim milk powder. After washing three times in TBS-T, the membranes were incubated for 1 h at 37°C with an anti-rabbit IgG conjugated with horseradish peroxidase. The results were visualized using the DAB assay kit (ZSGB-biology Company, Beijing, China) and documented with a gel imaging system (UVP Bioimaging System). The signals were quantitated with the Gel-Pro Analyzer Version 4.0 (Media Cybernetics, Rockville, MD, USA).

Statistical analysis

All data were expressed as mean \pm SD. The data was processed by the statistical analysis software SPSS version 16.0 (SPSS Inc. Chicago, IL, USA). One-way analysis of variance (ANOVA) was used to examine significant differences

between the groups. Statistical analysis for every measurement is described within the figures and table legends. $P < 0.05$ was considered statistically significant.

Results

Histopathologic damages of lung were improved by curcumin

The lung architectural structure was normal in sham group. The tissues of lung were observed obvious damage with hemorrhage, edema and inflammatory cell infiltration in IIR group. Statistical analysis was performed by one way analysis of variance and all pairwise multiple comparisons were via L-S-D method. There was a significant difference between IIR and sham group in pathological score ($P < 0.01$) and BALF content ($P < 0.01$).

After the administration of curcumin (1 mg/kg, 5 mg/kg), the pathological score of lung injury markedly improved $P < 0.01$, $P < 0.01$. There was no difference between group 1 mg/kg and group 5 mg/kg (**Figure 1**).

BALF content of lung were decreased by curcumin

With the treatment of curcumin, BALF content was signally improved compared to IIR group $P < 0.01$, $P < 0.01$. There was no difference between group 1 mg/kg and group 5 mg/kg (**Figure 2**). Statistical analysis was performed by one way analysis of variance and all pairwise multiple comparisons were via L-S-D method.

SOD level was restored by curcumin

SOD Level is an index meaning antioxidant effect. Compared with Sham group, SOD level in IIR group reduced signally ($P < 0.01$). In 1 mg/kg group, Compared with IIR group, SOD level were increased significantly ($P < 0.01$). In 5 mg/kg group, Compared with IIR group, SOD level were increased significantly ($P < 0.05$) (**Figure 3**). There was no obvious difference between group 1 mg/kg and group 5 mg/kg. Statistical analysis was performed by one way analysis of variance and all pairwise multiple comparisons were via L-S-D method.

MPO level of lung was decreased by curcumin

MPO content shows the ability of neutrophil recruitment. Compared with Sham group, MPO

Effects of curcumin on acute lung injury in intestinal ischemia reperfusion

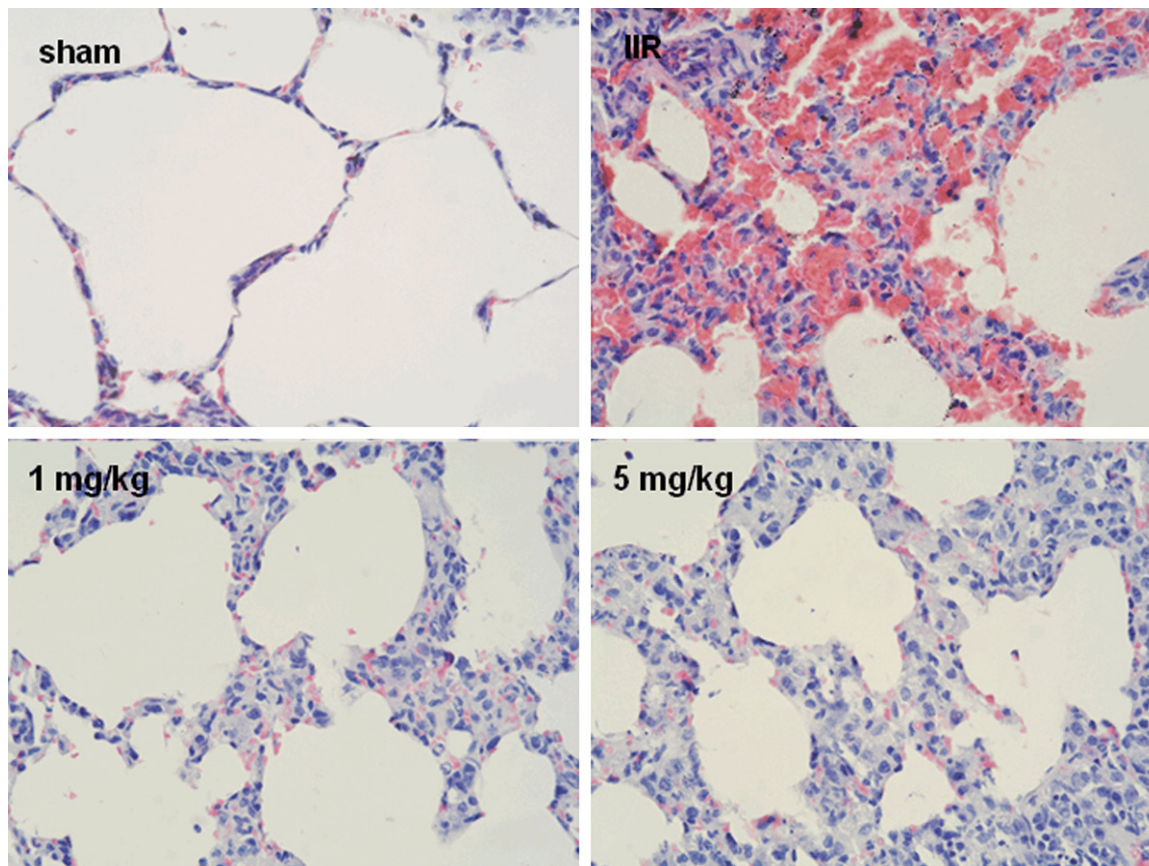


Figure 1. Histology changes of lung tissues ($\times 200$) in the Sham group, IIR group, 1 mg/kg group and 5 mg/kg group. Sham: Normal structure of lung; IIR: Collapsed alveoli, edema, hemorrhage and congested vessels were observed in lung tissue; 1 mg/kg and 5 mg/kg group: Relatively normal histology of lung with less collapsed alveoli, edema, hemorrhage and congested vessels. Compared with Sham, $*P < 0.01$; Compared with the IIR group, $\#P < 0.01$.

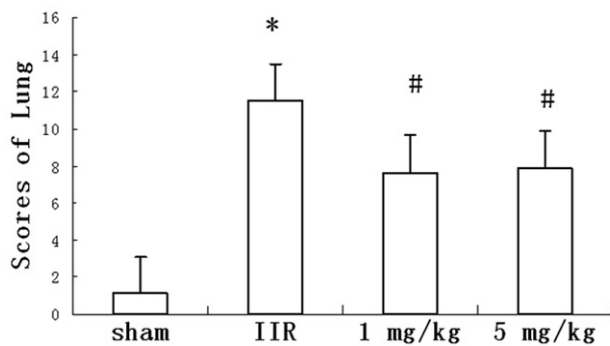


Figure 2. Lung BALF content in Sham group, IIR group, 1 mg/kg group and 5 mg/kg group. Compared with Sham, $*P < 0.01$; Compared with the IIR group, $\#P < 0.01$.

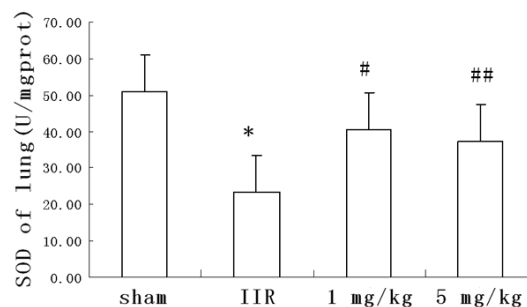


Figure 3. SOD level in Sham group, IIR group, 1 mg/kg group and 5 mg/kg group. Compared with Sham, $*P < 0.01$; Compared with the IIR group, $\#P < 0.01$, $\#\#P < 0.05$.

Effects of curcumin on acute lung injury in intestinal ischemia reperfusion

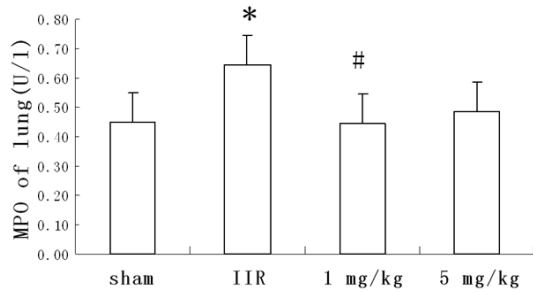


Figure 4. MPO level in Sham group, IIR group, 1 mg/kg group and 5 mg/kg group. Compared with Sham, * $P < 0.01$; Compared with the IIR group, # $P < 0.01$.

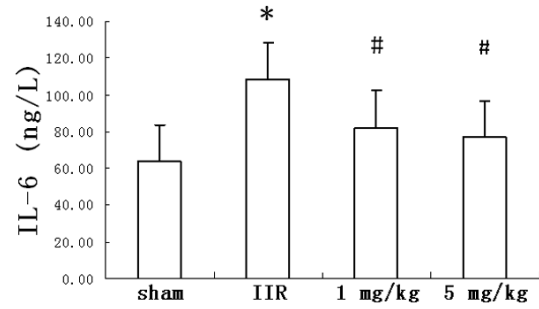


Figure 5. IL-6 Level in Sham group, IIR group, 1 mg/kg group and 5 mg/kg group. Compared with Sham, * $P < 0.01$; Compared with the IIR group, # $P < 0.01$.

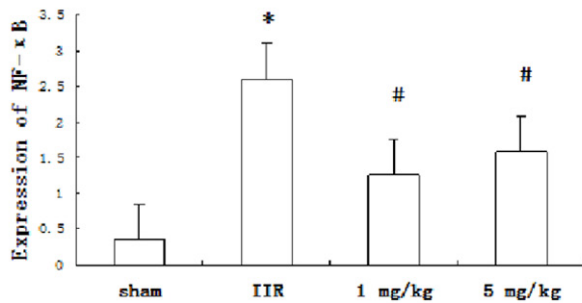
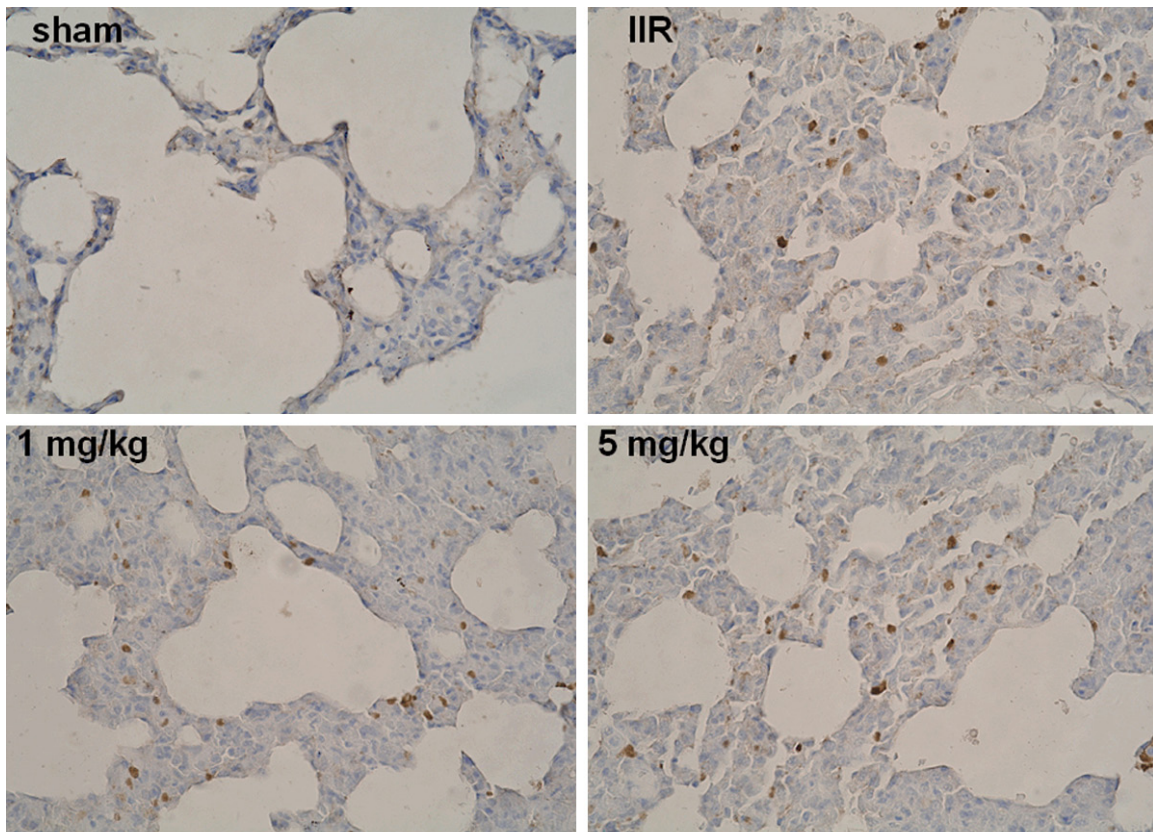


Figure 6. Expression of NF-κB p65 in lung tissue of Sham group, IIR group, 1 mg/kg group and 5 mg/kg group. Compared with Sham, * $P < 0.01$; Compared with the IIR group, # $P < 0.01$.

level in IIR group increased significantly ($P < 0.01$). In 1 mg/kg group, Compared with IIR group, MPO level

were decreased significantly ($P < 0.01$). In 5 mg/kg group, Compared with IIR group, MPO

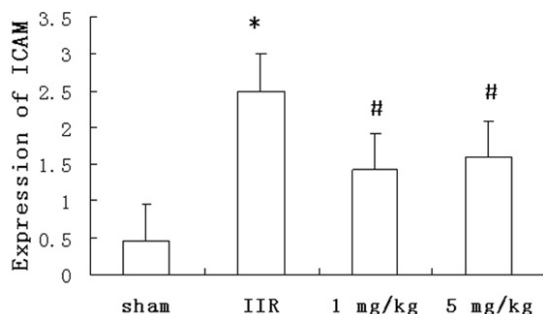
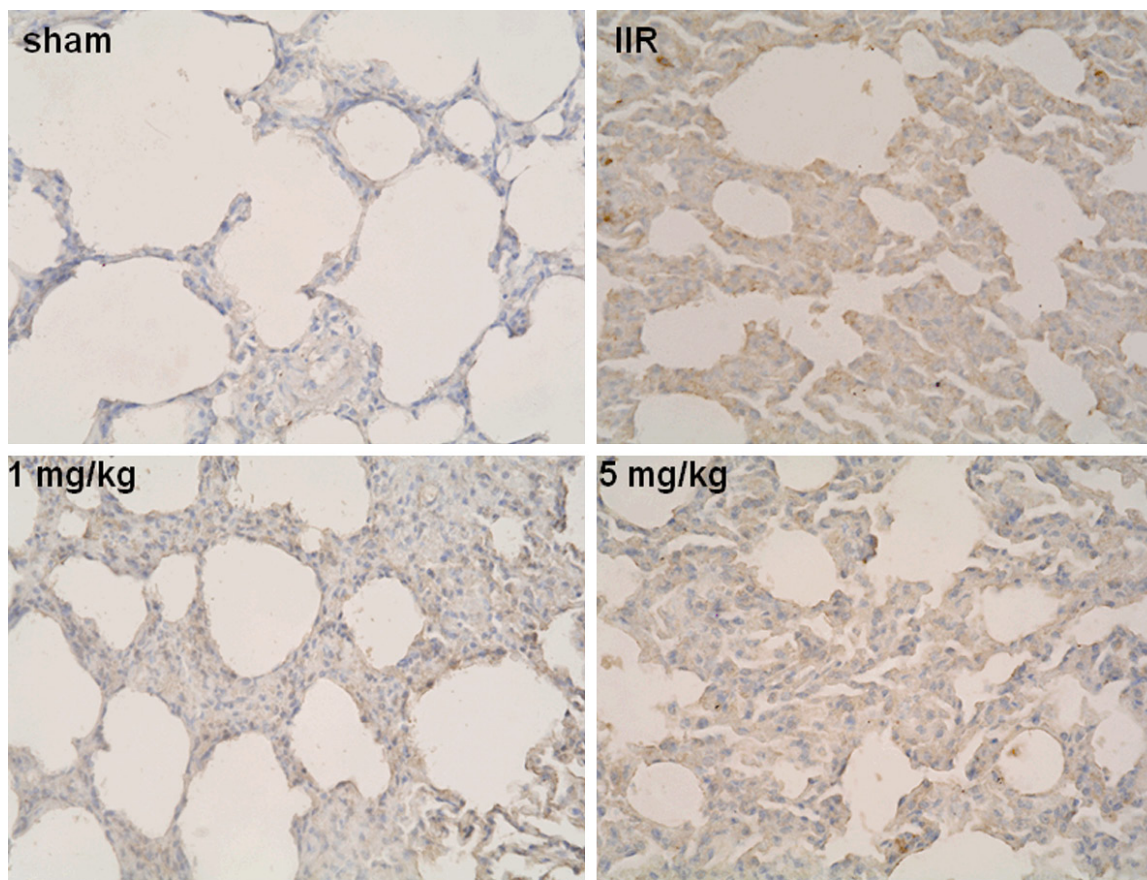


Figure 7. Expression of ICAM-1 in lung tissue of Sham group, IIR group, 1 mg/kg group and 5 mg/kg group. Compared with Sham, * $P < 0.01$; Compared with the IIR group, # $P < 0.01$.

level were decreased significantly ($P < 0.05$) (Figure 4). There was no obvious difference between group 1 mg/kg and group 5 mg/kg. Statistical analysis was performed by one way analysis of variance and all pairwise multiple comparisons were via L-S-D method.

Curcumin decreased serum il-6 level in lung after I/R

In the present study, the IL-6 cytokine increased significantly after IIR compared with the sham group ($P < 0.01$). IL-6 levels dramatically reduced in 1 mg/kg group and 5 mg/kg group ($P < 0.01$, $P < 0.01$; Figure 5). Statistical analy-

sis was performed by one way analysis of variance and all pairwise multiple comparisons were via L-S-D method.

Expression of NF- κ B p65 in lung tissue was decreased by curcumin

In Sham group, no staining in the nuclei; in IIR group ($P < 0.01$), positive expressions; in 1 mg/kg group ($P < 0.01$) and 5 mg/kg group ($P < 0.01$), the positive rates decreased obviously compared to IIR group (Figure 6). Statistical analysis was performed by one way analysis of variance and all pairwise multiple comparisons were via L-S-D method.

Effects of curcumin on acute lung injury in intestinal ischemia reperfusion

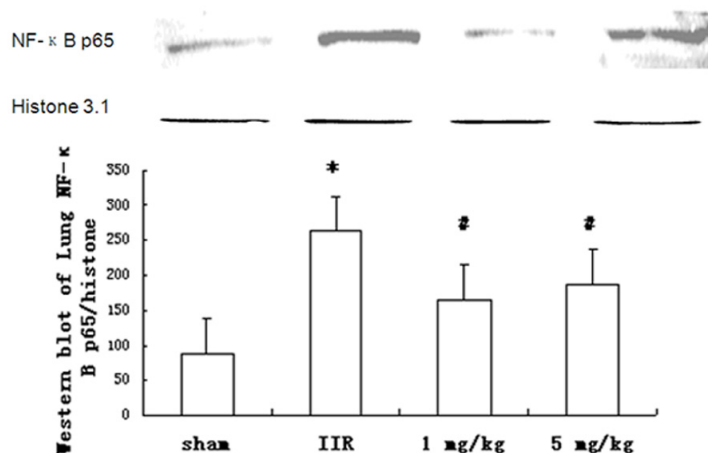


Figure 8. Lung NF-κB protein signals in lung tissue of Sham group, IIR group, 1 mg/kg group and 5 mg/kg group. Compared with Sham, * $P < 0.01$; Compared with the IIR group, # $P < 0.01$.

Expression of ICAM-1 in lung tissue was decreased by curcumin

In Sham group, no staining in the cytoplasm; in IIR group ($P < 0.01$), positive expressions; in 1 mg/kg group ($P < 0.01$) and 5 mg/kg group ($P < 0.01$), the positive rates decreased obviously compared to IIR group (**Figure 7**). Statistical analysis was performed by one way analysis of variance and all pairwise multiple comparisons were via L-S-D method.

Western blot signal of NF-κB in lung tissue was weakened by curcumin

Western blot showed weak NF-κB p65 protein positive signal in the lung of sham group. In contrast, significant increase of NF-κB p65 expression was found in IIR group ($P < 0.01$). Compared to IIR group, in 1 mg/kg group ($P < 0.01$) and 5 mg/kg group ($P < 0.01$), the signals weakened obviously respectively (**Figure 8**). Statistical analysis was performed by one way analysis of variance and all pairwise multiple comparisons were via L-S-D method.

Discussion

Intestine ischemia reperfusion (I/R) is a frequent event in clinic process, inducing distant organ dysfunction especially acute pulmonary tissues injure which is the most important component of the MODS. The injury of intestinal mucosa induced by IIR could lead to recruitment of neutrophils and release of proinflam-

matory cytokines [1, 15]. Those endogenous substances, such as free oxygen radicals, platelet activating factor and bacterial endotoxins have been released to gastrointestinal and other tissue for example lung injury [16].

Our previous studies have demonstrated NF-κB pathway involved in the lung lesion induced by IIR and several antioxidants could improve the damage [5-7]. NF-κB is a rapid response nuclei transcription factor and two subunits of 50 and 65 ku were included in NF-κB. NF-κB is located in the cytoplasm and is combined to the inhibitory unit inhibitory κB (IκB). When IκB is activated (phosphorylated) by

its kinase IκB kinase (IKK), NF-κB could translocate into nucleus to adjust gene transcription, including regulating IL-6 and ICAM-1 [17].

Curcumin is a yellow colored polyphenolic compound derived from *Curcuma longa* and its chemical formula is 1, 7-bis (4-hydroxy-3-methoxyphenyl)-1, 6-hepta-diene-3, 5-Dione. In South and Southeast of Asia, it is used widely. More and more research proves that curcumin could be used to treat cancer, cardiovascular disease, and inflammatory conditions [18].

There have been three articles reporting of the effects of curcumin on acute lung injury induced by intestinal ischaemia reperfusion, however, none of them illustrates the mechanism during the process. NF-κB pathway have been demonstrated by our previous experiments and in the present article, we look forward to the anti-inflammatory and antioxidant effects of curcumin through suppression NF-κB pathway in lung lesion from IIR. The experiment demonstrates that curcumin: I). improved lung histology changes, II). Lessened BALF content, III). Reduced lung MPO but increased SOD levels, and IV). These changes were parallel to the increased levels of lung NF-κB p65, which adjusted the expression of ICAM-1, serum IL-6 [1, 5, 6].

In the research, the model was established by clipped SAM for 1 h and then released SAM for 2 h. Intestinal injury happened and this resulted in intestine epithelial barrier dysfunction.

Effects of curcumin on acute lung injury in intestinal ischemia reperfusion

Bacteria and endotoxin were subsequently release into circulation, which resulted in activation of proinflammatory cytokines and leukocytes recruitment [2]. Distant organs were affected through the proinflammatory cytokines and leukocytes recruitment especially lung tissues. Activated neutrophils generate MPO and MPO could catalytically produce hypochlorous acid and chloride anions. MPO activity is parallel with neutrophil activation and MPO level is a marker of neutrophil recruitment and damage to lung tissues, which reflect the degree of lung lesion [8, 19]. Therefore, lung tissues injury was observed through histology, BALF content and MPO. Antioxidant enzymes for example SOD were consumed and depleted by ROS during IIR [8, 20], so SOD level was measured to evaluate lung tissue from antioxidant aspect [5]. IL-6 is also an important proinflammatory mediator estimating lung injury because neutrophil lung recruitment/ infiltration are correlated with IL-6 expression in IIR [21].

Previous studies showed that ICAM-1 expression could be regulated through NF- κ B pathway [6, 7]. In the present experiment, ICAM-1 expression was measured to assess NF- κ B activity.

In our study, In IIR group, lung tissue were severe damaged in histology and BALF content was increased signally because of neutrophil recruitment/infiltration, which also induced rise of MPO level and decline of SOD. NF- κ B was activated and NF- κ B level was evaluated through Western blot. Compared with sham group, NF- κ B protein increased memorably. IL-6 and ICAM-1 were regulated by NF- κ B, so these indexes were also examined and significances could be easily observed. After treatment with curcumin at doses of 1 and 5 mg/kg, morphological injury and neutrophil infiltration in the lung tissue were improved observably; BALF content was decreased significantly; MPO level of Lung was decreased markedly and SOD level of Lung increased significantly. The level of IL-6, and ICAM-1 changed paralleling with NF- κ B. These results showed that neutrophil recruitment/infiltration were lessened and antioxidant ability was promoted by treatment of curcumin through restraining NF- κ B pathway. However, a dose-dependent manner was not found between low and high doses.

In conclusion, the present study demonstrated that curcumin treatment against IIR could

attenuate lung lesion in rats and curcumin play an antiinflammatory and antioxidant role by inhibiting NF- κ B pathway. MicroRNAs (miRNAs) have emerged as key posttranscriptional regulators of gene expression in the past decade, and they have been shown to be involved in a number of diverse physiological and pathological processes. In the future experiment, we will focus on the relation between NF- κ B and miRNAs.

Disclosure of conflict of interest

None.

Address correspondence to: Dr. Xiaofeng Tian, Department of General Surgery, The Second Hospital of Dalian Medical University, Dalian 116023, China. E-mail: txfdl@dlmedu.edu.cn; Dr. Jihong Yao, Department of Pharmacology, Dalian Medical University, Dalian 116044, China. E-mail: yaojihong65@hotmail.com

References

- [1] Kim K, Li Y, Jin G, Chong W, Liu B, Lu J, Lee K, Demoya M, Velmahos GC, Alam HB. Effect of valproic acid on acute lung injury in a rodent model of intestinal ischemia reperfusion. *Resuscitation* 2012; 2: 243-248.
- [2] Okudan N, Belviranlı M, Gökbel H, Oz M, Kumak A. Protective effects of curcumin supplementation on intestinal ischemia reperfusion injury. *Phytomedicine* 2013; 20: 844-848.
- [3] Fan Z, Jing H, Yao J, Li Y, Hu X, Shao H, Shen G, Pan J, Luo F, Tian X. The protective effects of curcumin on experimental acute liver lesion induced by intestinal ischemia-reperfusion through inhibiting the pathway of NF- κ B in a rat model. *Oxid Med Cell Longev* 2014; 2014: 191624.
- [4] Wang G, Chen Z, Zhang F, Jing H, Xu W, Ning S, Li Z, Liu K, Yao J, Tian X. Blockade of PKC β protects against remote organ injury induced by intestinal ischemia and reperfusion via a p66shc-mediated mitochondrial apoptotic pathway. *Apoptosis* 2014; 19: 1342-1353.
- [5] Tian XF, Yao JH, Zhang XS, Zheng SS, Guo XH, Wang LM, Wang ZZ, Liu KX. Protective effect of carnosol on lung injury induced by intestinal ischemia/reperfusion. *Surg Today* 2010; 40: 858-865.
- [6] Tian XF, Zhang XS, Li YH, Wang ZZ, Zhang F, Wang LM, Yao JH. Proteasome inhibition attenuates lung injury induced by intestinal ischemia reperfusion in rats. *Life Sci* 2006; 79: 2069-2076.
- [7] Tian XF, Yao JH, Li YH, Zhang XS, Feng BA, Yang CM and Zheng SS. Effect of nuclear factor kap-

Effects of curcumin on acute lung injury in intestinal ischemia reperfusion

- pa B on intercellular adhesion molecule-1 expression and neutrophil infiltration in lung injury induced by intestinal ischemia/reperfusion in rats. *World J Gastroenterol* 2006; 12: 388-392.
- [8] Guzel A, Kanter M, Guzel A, Yucel AF, Erboga M. Protective effect of curcumin on acute lung injury induced by intestinal ischaemia/reperfusion. *Toxicol Ind Health* 2013; 29: 633-642.
- [9] Nazari QA, Takada-Takatori Y, Hashimoto T, Imaizumi A, Izumi Y, Akaike A, Kume T. Potential protective effect of highly bioavailable curcumin on an oxidative stress model induced by microinjection of sodium nitroprusside in mice brain. *Food Funct* 2014; 5: 984-989.
- [10] Onder A, Kapan M, Gümüş M, Yüksel H, Böyük A, Alp H, Başarili MK, Firat U. The protective effects of curcumin on intestine and remote organs against mesenteric ischemia/reperfusion injury. *Turk J Gastroenterol* 2012; 23: 141-147.
- [11] Lane JS, Todd KE, Lewis MP, Gloor B, Ashley SW, Reber HA, McFadden DW, Chandler CF. Interleukin-10 reduces the systemic inflammatory response in a murine model of intestinal ischemia/reperfusion. *Surgery* 1997; 122: 288-294.
- [12] Mikawa K, Nishina K, Takao Y, Obara H. ONO-1714, a nitric oxide synthase inhibitor, attenuates endotoxin-induced acute lung injury in rabbits. *Anesth Analg* 2003; 97: 1751-1755.
- [13] Li Y, Yao JH, Hu XW, Fan Z, Huang L, Jing HR, Liu KX, Tian XF. Inhibition of Rho kinase by fasudil hydrochloride attenuates lung injury induced by intestinal ischemia and reperfusion. *Life Sci* 2011; 88: 104-109.
- [14] Cox G. IL-10 enhances resolution of pulmonary inflammation in vivo by promoting apoptosis of neutrophils. *Am J Physiol* 1996; 271: 566-571.
- [15] Fink MP. Reactive oxygen species as mediators of organ dysfunction caused by sepsis, acute respiratory distress syndrome, or hemorrhagic shock: potential benefits of resuscitation with Ringer's ethyl pyruvate solution. *Curr Opin Clin Nutr Metab Care* 2002; 5:167-174.
- [16] Parks DA, Bulkley GB, Granger DN, Hamilton SR, McCord JM. Ischemic injury in the cat small intestine: role of superoxide radicals. *Gastroenterology* 1982; 82: 9-15.
- [17] Yao JH, Zhang XS, Zheng SS, Li YH, Wang LM, Wang ZZ, Chu L, Hu XW, Liu KX, Tian XF. Prophylaxis with carnosol attenuates liver injury induced by intestinal ischemia/reperfusion. *World J Gastroenterol* 2009; 14: 3240-3245.
- [18] Dey A and Lakshmanan J. The role of antioxidants and other agents in alleviating hyperglycemia mediated oxidative stress and injury in liver. *Food Funct* 2013; 4: 1148-1184.
- [19] Barut I, Tarhan OR, Kapucuoglu N, Sutcu R, Akdeniz Y. Lamotrigine reduces intestinal I/R injury in the rat. *Shock* 2007; 28: 202-206.
- [20] Türüt H, Kurutas EB, Bulbuloglu E, Yasim A, Ozkaya M, Onder A, Imrek SS. Zinc aspartate alleviates lung injury induced by intestinal ischemia reperfusion in rats. *J Surg Res* 2009; 151: 62-67.
- [21] Geudens N, Timmermans L, Vanhooren H, Vanaudenaerde BM, Vos R, Van De Wauwer C, Verleden GM, Verbeken E, Lerut T, Van Raemdonck DE. Azithromycin reduces airway inflammation in a murine model of lung ischemia reperfusion injury. *Transpl Int* 2008; 21: 688-695.