

## Case Report

# A case of matrix-producing carcinoma of the breast with micoglandular adenosis and review of literature

Li-Yun Liu<sup>1</sup>, Shu-Hai Sheng<sup>2</sup>, Zhi-Yong Zhang<sup>1</sup>, Jin-Heng Xu<sup>1</sup>

Departments of <sup>1</sup>Pathology, <sup>2</sup>Breast Surgery, Tangshan Gongren Hospital, Tangshan, China

Received May 11, 2015; Accepted June 26, 2015; Epub July 1, 2015; Published July 15, 2015

**Abstract:** Matrix-producing carcinoma (MPC) of the breast is an extremely rare variant of metaplastic breast carcinoma that contains a mixture of epithelial and mesenchymal elements. As overt carcinoma with direct transition to a cartilaginous and/or osseous stromal matrix cells, MPC is of no spindle cells between those two elements. This is the case of a 43 year-old female patient with MPC which coexisted with microglandular adenosis (MGA), atypical MGA (AMGA) and carcinoma in situ arising in MGA (MGACA in situ). MGA is a rare, infiltrative, benign lesion of the breast with an indolent clinical course. Histological evidence of carcinoma arising from MGA has previously been documented. MPC arising in MGA is an extremely rare subtype of breast carcinoma and has been seldom detailed described in the previous studies. This report highlights one such case with cytomorphological and histopathological correlation, along with a review of pertinent literature and differential diagnosis.

**Keywords:** Matrix-producing carcinoma, microglandular adenosis, metaplastic breast carcinoma

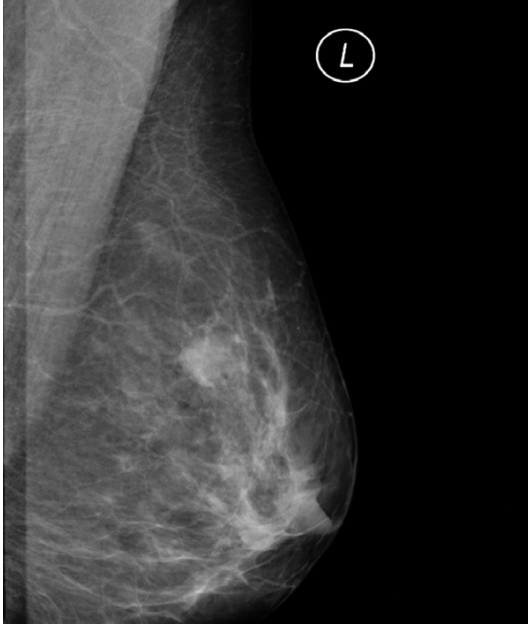## Case presentation

A 43-year-old woman with no significant past medical history presented with complaint of a lump in the left breast for the last three days on Jun, 2011. On breast medical examination, there expressed a painless, freely mobile, hard and palpable lump in the left breast. The right breast and the axilla lymph node were not involved. Laboratory examination revealed that a series of studies of tumor marker were all in normal range and bone isotope scan showed there was no skeletal abnormal lesion. On mammography, a 2.1 cm × 1.5 cm ill-defined mass with irregular margins was identified in the left upper quadrant (**Figure 1**). Breast color Doppler ultrasound indicated the mass of 1.8 cm × 1.49 cm in diameter and a slightly indistinct boundary (**Figure 2**). Excisional biopsy of the breast lesion diagnosed matrix-producing carcinoma (MPC) with microglandular adenosis (MGA), atypical MGA (AMGA) and carcinoma in situ arising in MGA (MGACA in situ). Later, the patient underwent modified radical mastectomy of the left breast with axillary node dissection. The postoperative pathological period was uneventful. At time of initial diagnosis, there

was no axilla lymph node metastasis and distant metastasis.

**Pathological examination:** Grossly, the lumpectomy specimen on cut surface revealed a firm, grey to white, fibrous, unencapsulated nodular tumor with infiltrative borders. The tumor size was 2 cm × 1.5 cm × 1 cm. And there was mucoid and glistening in some regions.

Under the microscope, the tumor consisted of a MPC area and a MGA area. MPC merely composed of cord-like cells scattered in the chondromyxoid matrix. The tumor cells were smaller, spindle-shaped or oval, eosinophilic cytoplasm. There was no obvious atypical nuclei. In addition, focal areas of the matrix ranged from mucoid appearing (**Figure 3A**) to more overtly cartilaginous with hyaline matrix (**Figure 3B**). MGA consisted of small round glands within the normal breast stroma (**Figure 3C**). The glands were lined with a single layer of cuboidal to flat epithelial cells. The areas of atypical MGA (AMGA) consisted of more irregularly shaped glands with less prominent intraluminal secretions and the epithelium exhibited coarse chromatin, and prominent nucleoli. The cytoplasm



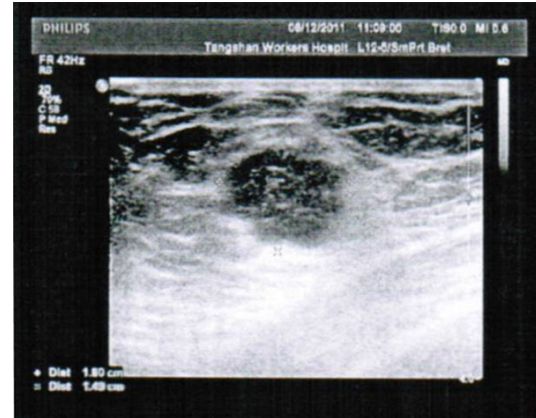
**Figure 1.** Mammographic findings. A 2.1 cm × 1.5 cm ill-defined mass with irregular margins was identified in the left upper quadrant.

was dense, with a higher nuclear-to-cytoplasmic ratio. And carcinoma in situ arising in MGA showed markable cytological atypia, less prominent intraluminal secretions (**Figure 3D**). We did not find out that the invasive components composed invasive carcinoma of no special type (NST). This case showed a spectrum of structure and glandular proliferations ranging from MGA to AMGA to MGACA in situ to MPC (**Figure 3E**).

With immunohistochemical staining, smooth muscle actin (SMA) and p63 was dot-positive in the tumor cells of MPC (**Figure 4A**). The tumor cells were triple-negative for estrogen receptor (ER), progesterone receptor (PR) and Her-2. Interestingly, tumor cells of MPC in the case were negative for S-100 different from that in other previous cases usually being positive. No myoepithelial cells showed positive in MGA, AMGA, MGACA in situ for p63 (**Figure 4B**). The epithelial cells of MGA were represented positive for S-100 (**Figure 4C**). There were negative of desmin, epidermal growth factor receptor (EGFR) and Syn both in MPC and MGA lesions. In addition, keratin 7 was positive in the adenosis and interspersed benign ducts that acted as internal controls.

## Discussions

MPC of the breast is one variant type of metaplastic breast carcinoma which represents less



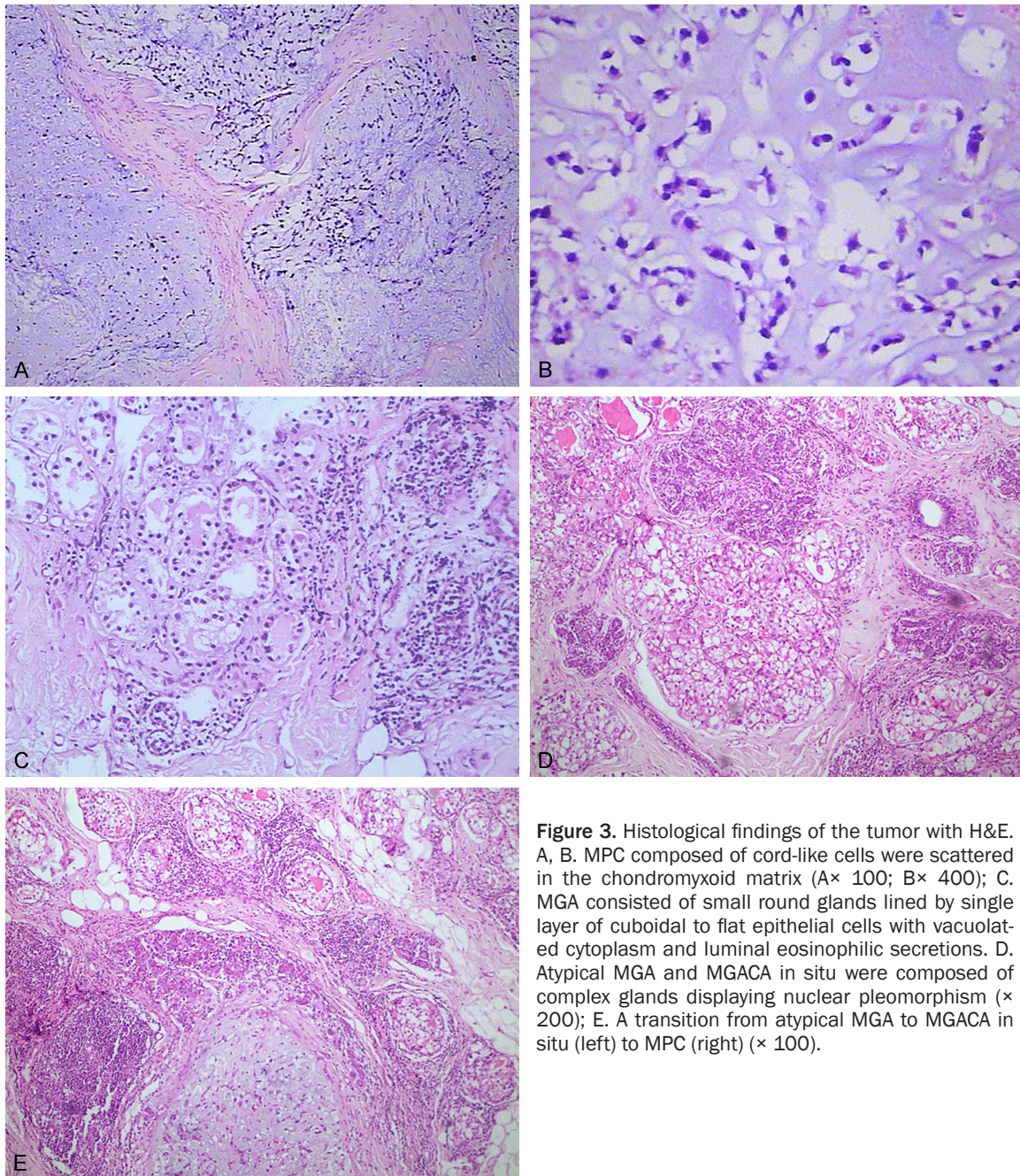
**Figure 2.** Breast color Doppler ultrasound indicated a tumor with dimensions of 1.8 cm × 1.49 cm and a slightly indistinct boundary.

than 1% of all breast cancers [1]. It is characterized by the existence of an overt ductal carcinomatous component with a direct transition to areas with cartilaginous or osseous differentiation, lacking an interspersed spindle cell component [2]. MPC with MGA is an uncommon breast malignant tumor. Since the lack of sufficiently large studies, MPC with MGA is limited to the pathogenesis, progress, best treatment protocols and prognosis. Collaborative studies are therefore recommended to allow for better understanding of this intriguing neoplasm.

Ultra-structural analysis of MPC supports the evidence that the tumor cells are of epithelial and myoepithelial derivation. Myoepithelial cells differentiate along mesenchymal lines and produce a gamut of matricial appearances [3]. p63 has been reported to be useful as diagnostic marker for metaplastic carcinoma. The sensitivity and specificity of p63 for metaplastic carcinoma was 86.7% and 99.4%, respectively [4], which conformed that the tumor cells in MPC might originate from the myoepithelial cells. Positive expressions for myoepithelial markers (e.g. SMA, p63) in this case further suggested that these MPC tumors might constitute as myoepithelial subtypes of a metaplastic carcinoma.

MGA of the breast is an extremely rare, benign lesion. It differs from other types of adenosis with an infiltrative pattern of growth and glands lack of a myoepithelial layer [5]. The glandular cells of MGA in our study were negative for SMA and p63 that also proved the glands were lack of a myoepithelial layer. Although MGA has been considered benign proliferative lesion,



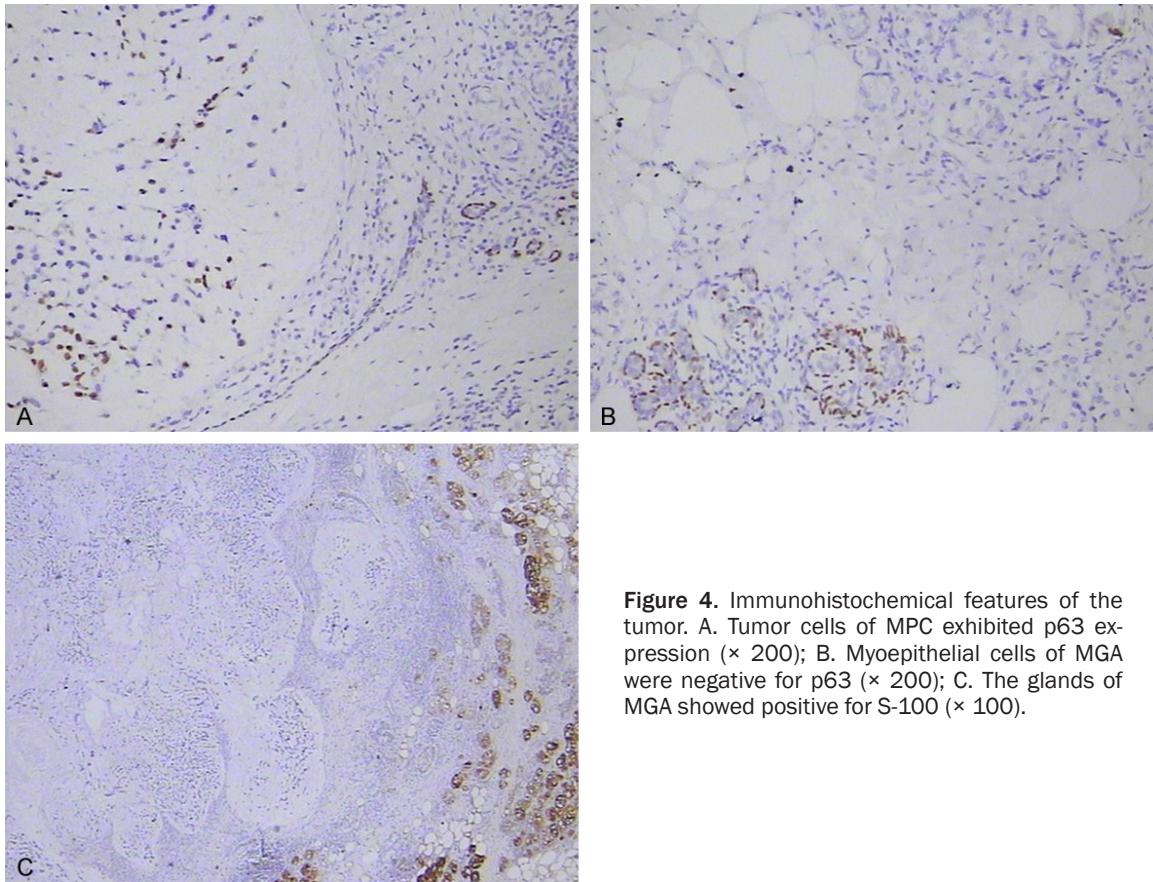


**Figure 3.** Histological findings of the tumor with H&E. A, B. MPC composed of cord-like cells were scattered in the chondromyxoid matrix (A× 100; B× 400); C. MGA consisted of small round glands lined by single layer of cuboidal to flat epithelial cells with vacuolated cytoplasm and luminal eosinophilic secretions. D. Atypical MGA and MGACA in situ were composed of complex glands displaying nuclear pleomorphism (× 200); E. A transition from atypical MGA to MGACA in situ (left) to MPC (right) (× 100).

atypical forms of MGA and invasive carcinomas arisen in the background of MGA still are reported. It was said breast carcinoma has been up to 27% of patients with MGA. There was controversy that the role of microglandular adenosis acts as a potential precursor of invasive breast cancer [6, 7]. Shui's study reported 2 cases of MPC arising in MGA [8], and suggested a close relationship between the two lesions. In this case, the lesion of MPC was

adjacent to the lesions of MGA and atypical MGA and MGACA in situ. There were no invasive elements with NST observed. More interestingly, SMA and p63 was immunohistochemical positive in MPC, while negative in MGA for p63. Tumor cells of MPC were negative for S-100, while the epitheliums of MGA positive. Nevertheless, MPC had similar immunohistochemical profile of MGA, such as triple-negative in the case that was consistent with another





**Figure 4.** Immunohistochemical features of the tumor. A. Tumor cells of MPC exhibited p63 expression ( $\times 200$ ); B. Myoepithelial cells of MGA were negative for p63 ( $\times 200$ ); C. The glands of MGA showed positive for S-100 ( $\times 100$ ).

report [9]. We could make a conclusion that MPC arising from MGA or accompanied with MGA. It is still unclear that a spectrum of structure and glandular proliferations ranging from MGA to AMGA to MGACA in situ to MPC. Thus, a histogenetic link remains to be proven.

Even these have conflicting conclusions regarding the most important prognostic indicators and treatment options. Metaplastic breast carcinoma tends to present in an advanced stage and often recurs locally, but survival is similar to that of adenocarcinomas of comparable stage, and hence treatment should follow similar principles [10]. However, metaplastic carcinoma is aggressive with a poor outcome. Tumor size is an important factor in determining outcome. And patients with a tumor size larger than 5 cm have a worse survival rate [11]. The mesenchymal element involved seemed to be another important factor in determining the outcome [12]. MPC and spindle cell metaplastic cancer of breast are reported to have better prognosis. In this case, the tumor cells in both

the MPC and the MGA were triple-negative in accordance with the study of Gibson GR [13]. It was important in terms of elucidating the etiology of the metaplastic change. In the case, the tumor size was about 2 cm, which indicates a favorable prognosis. The patient refused hormone therapy and postoperative adjuvant chemotherapy was recommended for six cycle and checking regularly. Till now, the patient is alive without recurrence follow-up 39 months.

In the future it will be necessary to study a larger number of patients with MPC of the breast and further elucidate the clinicopathological characteristics of this malignancy.

#### Disclosure of conflict of interest

None.

**Address correspondence to:** Dr. Zhi-Yong Zhang, Department of Pathology, Tangshan Gongren Hospital, 27 Wenhua Road, Lubei District, Tangshan 063000, China. Tel: 86-315-3722441; Fax: 86-315-2844162; E-mail: zhiyongzhang1@hotmail.com

## References

- [1] Mardi K, Sharma J. Matrix-producing mammary carcinoma: A rare breast tumor. *Indian J Pathol* 2008; 51: 263-64.
- [2] Wargtoz E, Norries H. Metaplastic carcinomas of the breast: matrix producing carcinomas. *Histopathol* 2001; 39: 518-83.
- [3] Wargotz ES, Norris HJ. Metaplastic carcinomas of the breast. I. Matrix-producing carcinoma. *Hum Pathol* 1989; 20: 628-35.
- [4] Koker MM, Kleer CG. p63 expression in breast cancer: a highly sensitive and specific marker of metaplastic carcinoma. *Am J Surg Pathol* 2004; 28: 1506-12.
- [5] Salarieh A, Sneige N. Breast carcinoma arising in microglandular adenosis: a review of the literature. *Arch Pathol Lab Med* 2007; 131: 1397-99.
- [6] Koenig C, Dadmanesh F, Bratthauer GL, Tavassoli FA. Carcinoma arising in microglandular adenosis: An immunohistochemical analysis of 20 intraepithelial and invasive neoplasms. *Int J Surg Pathol* 2000; 8: 303-15.
- [7] Afshin S, Nour S. Breast carcinoma arising in microglandular adenosis: a review of the literature. *Arch Pathol Lab Med* 2007; 131: 1397-99.
- [8] Shui R, Bi R, Cheng Y, Lu H, Wang J, Yang W. Matrix-producing carcinoma of the breast in the Chinese population: a clinicopathological study of 13 cases. *Pathol Int* 2011; 61: 415-22.
- [9] Zhong FF, Bi R, Yu BH, Cheng YF, Xu XL, Shui RH, Yang WT. Carcinoma arising in microglandular adenosis of the breast: triple negative phenotype with variable morphology. *Int J Clin Exp Pathol* 2014; 7: 6149-56.
- [10] Gibson GR, Qian D, Ku JK, Lai LL. Metaplastic breast cancer: clinical features and outcomes. *Am Surg* 2005; 71: 725-30.
- [11] Al Sayed AD, El Weshi AN, Tulbah AM, Rahal MM, Ezzat AA. Metaplastic carcinoma of the breast clinical presentation, treatment results and prognostic factors. *Acta Oncol* 2006; 45: 188-95.
- [12] Beatty JD, Atwood M, Tickman R, Reiner M. Metaplastic breast cancer: clinical significance. *Am J Surg* 2006; 191: 657-64.
- [13] Gibson GR, Qian D, Ku JK, Lai LL. Metaplastic breast cancer: clinical features and outcomes. *Am J Surg* 2005; 71: 725-30.