Int J Clin Exp Pathol 2015;8(8):9240-9247
www.ijcep.com /ISSN:1936-2625/IJCEP0010538

Original Article

Overexpression of L1 cell adhesion molecule correlates with aggressive tumor progression of patients with breast cancer and promotes motility of breast cancer cells

Jian Zhang[1,2*], Fei Yang[3*], Yong Ding[4*], Linlin Zhen[2], Xuedong Han[2], Feng Jiao[5], Jinhai Tang[1]

[1]Department of General Surgery, Nanjing Medical University Affiliated Jiangsu Cancer Hospital, Nanjing 210009, China; [2]Department of General Surgery, Huai'an First People's Hospital, Nanjing Medical University, Huai'an, Jiangsu 223300, China; [3]Department of Oncology, Huai'an Second People's Hospital, Huai'an, Jiangsu 223002, China; [4]Department of General Surgery, The People's Hospital of Hong'ze County, Hong'ze, Jiangsu 223100, China; [5]Department of General Surgery, 82 Hospital of PLA, Huai'an, Jiangsu 223001, China. [*]Equal contributors.

Received May 22, 2015; Accepted June 28, 2015; Epub August 1, 2015; Published August 15, 2015

Abstract: Background and purpose: L1 cell adhesion molecule (L1CAM) has been observed to be aberrantly expressed and implicated in progression of several types of human cancers. However, its roles in breast cancer have not been fully elucidated. In this study, we aimed to investigate the clinical significance of L1CAM in human breast cancer and to validate whether it participates in cancer cell migration and invasion. Methods: Immunohistochemical analysis of 100 breast cancer and matched non-cancerous breast tissues was performed to detect the expression and sub-cellular localization of L1CAM protein. Its associations with clinicopathological characteristics of breast cancer patients were statistically analyzed and its phenotypic effects were also evaluated *in vitro*. Results: Of the 100 breast cancer patients, 89 (89.0%) were positive for L1CAM immunostaining localized in the membrane of cancer cells. The immunoreactive scores of L1CAM protein in breast cancer tissues were significantly higher than those in matched non-cancerous breast tissues ($P<0.05$). Chi-Square analysis showed the significant associations between L1CAM overexpression and high tumor stage ($P=0.01$), advanced tumor grade ($P=0.03$), positive lymph node metastasis ($P=0.01$) and tumor recurrence ($P=0.01$) in breast cancer patients. Moreover, we found that RNA interference-mediated knockdown of L1CAM could inhibit the migration and invasion abilities of breast cancer cells *in vitro*. Conclusions: Our results suggest that the overexpression of L1CAM may be related to several established markers of poor prognosis in breast cancer patients. L1CAM might be a potential therapeutic target against metastatic breast cancer.

Keywords: L1 cell adhesion molecule, breast cancer, clinicopathological characteristic, migration, invasion

Introduction

Breast cancer, one of the most common malignancies and the leading cause of cancer-related mortality in women worldwide [1]. Due to high incidence and mortality, a median overall survival period of patients with this cancer remains 2 to 3 years [2]. It has been indicated that the clinical management and outcome of patients with breast cancer may be determined by various clinicopathological characteristics and molecular markers because of its high heterogeneity at the histopathologic and molecular levels [3]. Tumor metastasis, which consists a complex series of events including cell migration, invasion, adhesion and vessel formation, has been confirmed to cause the great majority of breast cancer patients' mortalities [4]. Thus, to clarify the underlying molecular mechanisms of breast cancer metastasis is the key point for the identification of effective therapeutic targets.

L1 cell adhesion molecule (L1CAM), a member of the immunoglobulin superfamily of cell adhesion molecules, is a 200-220 kDa transmembrane glycoprotein composed of 6 Ig-like domains and 5 fibron ectin type III repeats fol-

Table 1. Associations between L1CAM protein and clinicopathological characteristics of patients with breast cancer

Clinicopathological features	No. of cases	L1CAM expression		*P*
		High (n, %)	Low (n, %)	
Age				
<50	40	20 (50.00)	20 (50.00)	NS
≥50	60	31 (51.67)	29 (48.33)	
Tumor size (cm)				
<2.0	55	26 (47.27)	29 (52.73)	NS
≥2.0	45	25 (55.56)	20 (44.44)	
Histological type				
Ductal	70	35 (50.00)	35 (50.00)	
Lobular	10	6 (60.00)	4 (40.00)	NS
Others	20	10 (50.00)	10 (50.00)	
Histological grade				
I	22	6 (27.27)	16 (72.73)	
II	48	23 (47.92)	25 (52.08)	0.03
III	30	22 (73.33)	8 (26.67)	
Tumor stage				
I	10	3 (30.00)	7 (70.00)	
II	55	23 (41.82)	32 (58.18)	0.01
III	35	25 (82.86)	10 (17.14)	
Lymph node metastasis				
Negative	32	5 (15.63)	27 (84.37)	0.01
Positive	68	46 (67.65)	22 (32.35)	
Tumor recurrence				
Negative	40	11 (27.50)	29 (72.50)	0.01
Positive	60	40 (66.67)	20 (33.33)	

'NS' refers to the differences without statistical significance.

lowed by a transmembrane region and a highly conserved cytoplasmic tail [5]. Under the physiological condition, L1CAM is originally found in the nervous system and is expressed in developing neuronal cells, hematopoietic cells, renal epithelial cells, endothelial cells, and intestinal crypt cells [6]. Growing evidence show the abnormal expression pattern of L1CAM in a variety of cancer types, including glioma, neuroblastoma, melanoma, anaplastic thyroid carcinoma, non-small cell lung cancer, gastric cancer, hepatocellular carcinoma, pancreatic cancer, colorectal cancer, ovarian cancer and endometrial cancer [7-17]. Moreover, the presence of L1CAM overexpression has been indicated to be associated with advanced cancer progression and poor patients' prognosis. These findings imply the central role of L1CAM in human carcinogenesis, which prompted a large number of studies on the development and preclinical testing of L1CAM specific antibody for the target therapeutic strategies of cancers.

Several studies have focused on the potential role of L1CAM in breast cancer. For example, Li et al. [18] reported that the soluble form of L1CAM could promote breast cancer cell adhesion to extracellular matrix (ECM) and cell migration; Zhang et al. [19] validated that L1CAM might mediate vascular metastasis of hypoxic breast cancer cells to the lungs. However, its involvement in breast cancer has not been fully elucidated. In the current study, the expression pattern and subcellular localization of L1CAM protein in breast cancer tissues were detected by immunohistochemistry analysis based on a large cohort of clinical samples. Then, the associations between L1CAM protein and various clinicopathological characteristics were statistically evaluated. Furthermore, L1CAM was silenced in breast cancer cells and the effect on cell migration and invasion was examined.

Materials and methods

Patients and tissue samples

Experiments on human tissues was approved by the Research Ethics Committee of Nanjing Medical University Affiliated Jiangsu Cancer Hospital, Huai'an First People's Hospital, Huai'an Second People's Hospital, the People's Hospital of Hong'ze County and the 82 Hospital of PLA, P. R. China. Written informed consent was obtained from all of the patients enrolled in this study. All tissue specimens were handled and made anonymous according to the ethical and legal standards.

A total of 100 breast cancer and matched non-cancerous breast tissue specimens obtained

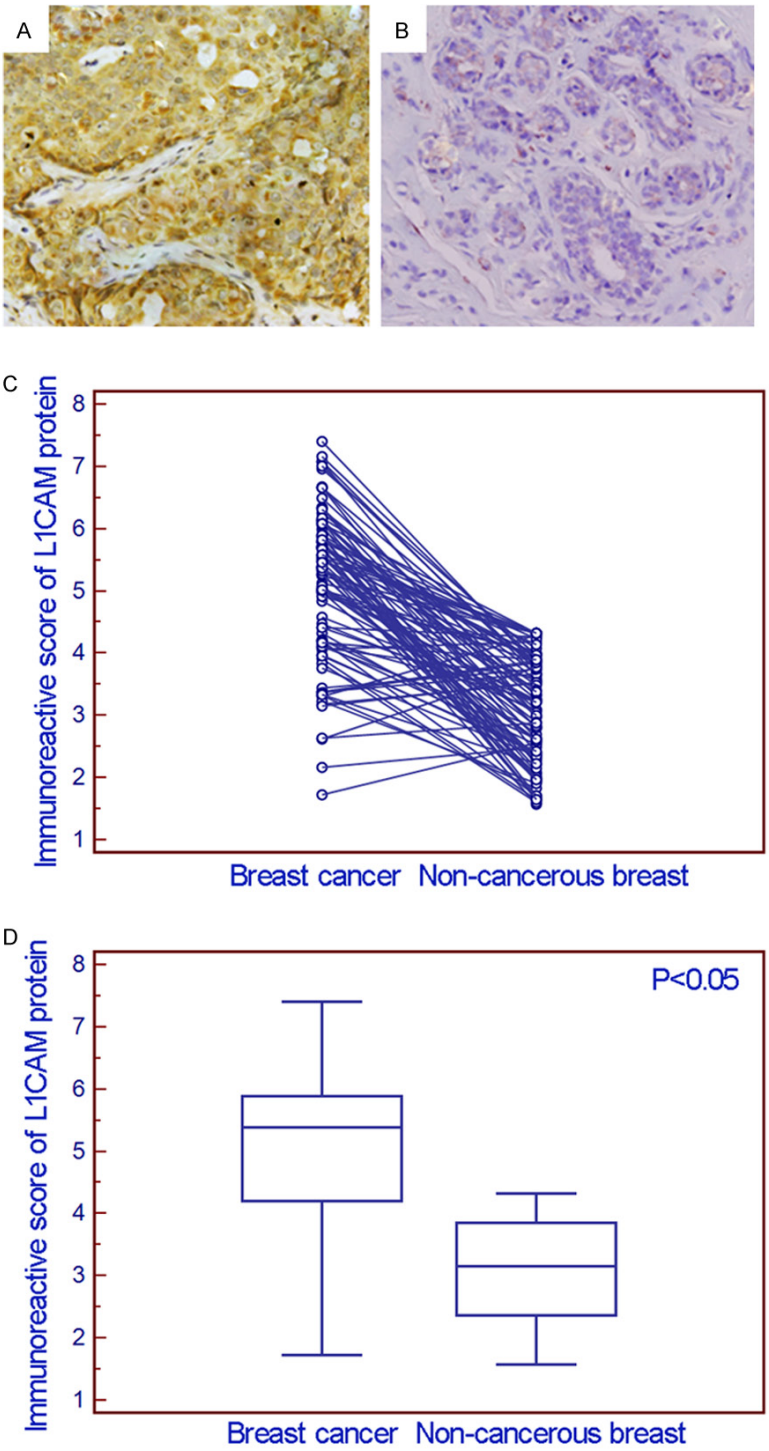

Figure 1. Overexpression of L1CAM protein in human breast cancer tissues. A. Positive L1CAM immunostaining was localized in the membrane of breast cancer cells; B. Negative or weak membrane staining of L1CAM was shown in non-cancerous breast tissues; C. There were 88 of 100 (88.0%) cases of breast cancer overexpressed L1CAM compared with the matched non-cancerous breast tissues; D. Statistical analysis showed that the L1CAM expression level in breast cancer tissues was higher than that in the matched non-cancerous breast tissues, with mean IRS at 5.12 ± 1.19 vs. 3.08 ± 0.84 ($P<0.05$).

from patients who underwent surgery between 2008 and 2012 at Department of General Surgery, Nanjing Medical University Affiliated Jiangsu Cancer Hospital and Huai'an First People's Hospital were enrolled in this study. All these tissue specimens were formalin-fixed and paraffin-embedded for histopathologic diagnosis and immunohistochemical study. Histological examination was performed by two pathologists, who were both unaware of the clinical data, on paraffin-embedded sections after hematoxylin-eosin staining. The tumor-node-metastasis (TNM) system of tumor stage and histological grade were performed according to the World Health Organization guidelines. The clinicopathological characteristics, including patients' age, tumor size, histological type, tumor stage, histological grade, lymph node status and tumor recurrence status, were summarized in **Table 1**.

Immunohistochemistry

Immunohistochemistry of 100 breast cancer and matched non-cancerous breast tissues was performed to detect the expression and sub-cellular localization of L1CAM protein. Briefly, the sections were dewaxed in xylene and rehydrated in graded ethanols, and immersed in 3% methanolic peroxide for 10 min to block the endogenous peroxidase activity. Then, the sections were incubated with the primary antibody for L1CAM (a goat polyclonal L1CAM antibody, sc-31032, Santa Cruz Biotechnology, CA, USA) for 60 min at room tempera-

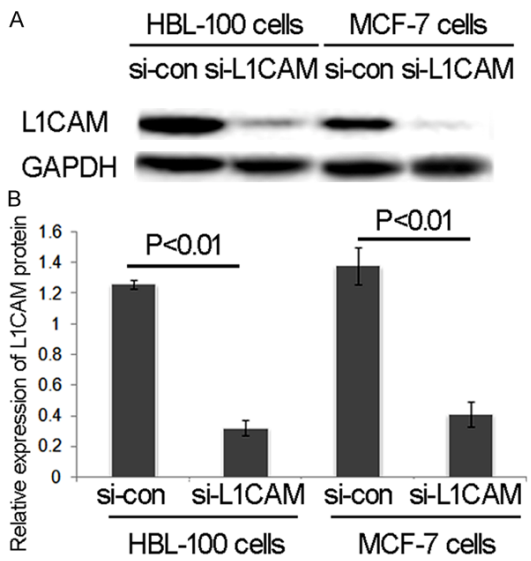

Figure 2. RNA interference-mediated knockdown of L1CAM protein in breast cancer cells in vitro. A. L1CAM protein levels in nontargeting control siRNA (si-con) and L1CAM-targeting siRNA (si-L1CAM) transfected HBL-100 and MCF-7 cells cells were detected by Western blot. B. LKB1 knockdown efficiency was quantified using densitometry. The L1CAM siRNA used in this study could reduce the level of L1CAM protein expression by >70% in both HBL-100 and MCF-7 cells.

ture. After that, the immunoperoxidase staining was accomplished using the Supersensitve Detection Kit with DAB (Zymed Labs, San Francisco, CA) as substrates, and counterstained with hematoxylin before coverslipping and reading by light microscopy. Negative controls were performed by omitting the primary antibodies. The breast cancer tissue specimens with the overexpression of L1CAM protein confirmed by western blot were used as positive controls. The specificity of the L1CAM antibody was reported in previous studies [20].

To evaluate the results of immunohistochemistry analysis, all sections were independently conducted by two pathologists, who were both blinded for clinical outcome data. The scores of the two pathologists were compared and any discrepant scores were trained through re-examining the staining by both pathologists to achieve a consensus score. All sections were scored in a semi-quantitative manner and the immunoreactivity scores (IRS) were calculated based on the number of immunoreactive tumor cells and the intensity of immunostaining as reported in the previous studies [21, 22]. The percentage scoring of immunoreactive tumor cells was as follows: 0 (0%), 1 (1-10%), 2 (11-50%) and 3 (>50%). The staining intensity was visually scored and stratified as follows: 0 (negative), 1 (weak), 2 (moderate) and 3 (strong). A final IRS was obtained for each case by multiplying the percentage and the intensity scores.

Cell culture

Two human breast cancer cell lines: HBL-100 and MCF-7 were purchased from the Cell Bank of Type Culture Collection of Chinese Academy of Sciences (Shanghai, China) and maintained in Dulbecco's modified Eagle's medium (DMEM) (GibCo BRL, Grand Island, NY) supplemented with 10% heat-inactivated fetal bovine serum (FBS, GibCo BRL, Grand Island, NY), 2 mM L-glutamine, and 100 U/ml penicillin–streptomycin mixture (GibCo BRL, Grand Island, NY) at 37°C and 5% CO_2.

Small interfering RNA transfection

HBL-100 and MCF-7 cells were seeded at a density of 2×10^5 cells per well in 6-well plates and were transfected the following day with either L1CAM-targeting siRNA (si-L1CAM, 5'-AGGGAUGGUGUCCACUUCAAATT-3') or nontargeting control siRNA (si-con, 5'-TTCTCCGA-ACGTGTCACGT-3') to a final concentration of 30 nM using Lipofectamine 2000 (Life Technologies, Carlsbad, CA, USA).

Western blot analysis

Western blot analysis was performed to detect the expression level of L1CAM protein in breast cancer cells transfected with either L1CAM-targeting siRNA (si-L1CAM) or nontargeting control siRNA (si-con). Briefly, 20 μg of total protein were mixed with loading buffer containing sodium dodecyl sulfate (SDS), boiled for 5 min, and then resolved by 7.5% SDS polyacrylamide gel electrophoresis. After blocking with 5% non-fat milk, the membranes were probed with goat anti-L1CAM polyclonal antibody (#sc-31032, Santa Cruz Biotechnology, CA, USA). GADPH antibody (Santa Cruz Biotechnology, CA, USA) was used as an internal reference. After that, the blots were incubated with peroxidase-conjugated anti-goat IgG (Santa Cruz Biotechnology, CA, USA) for 1 h at room temperature at a 1:1000 dilution. Immunobands were detected using ECL plus Western Blotting Detection System (GE Healthcare, Buckinghamshire, England).

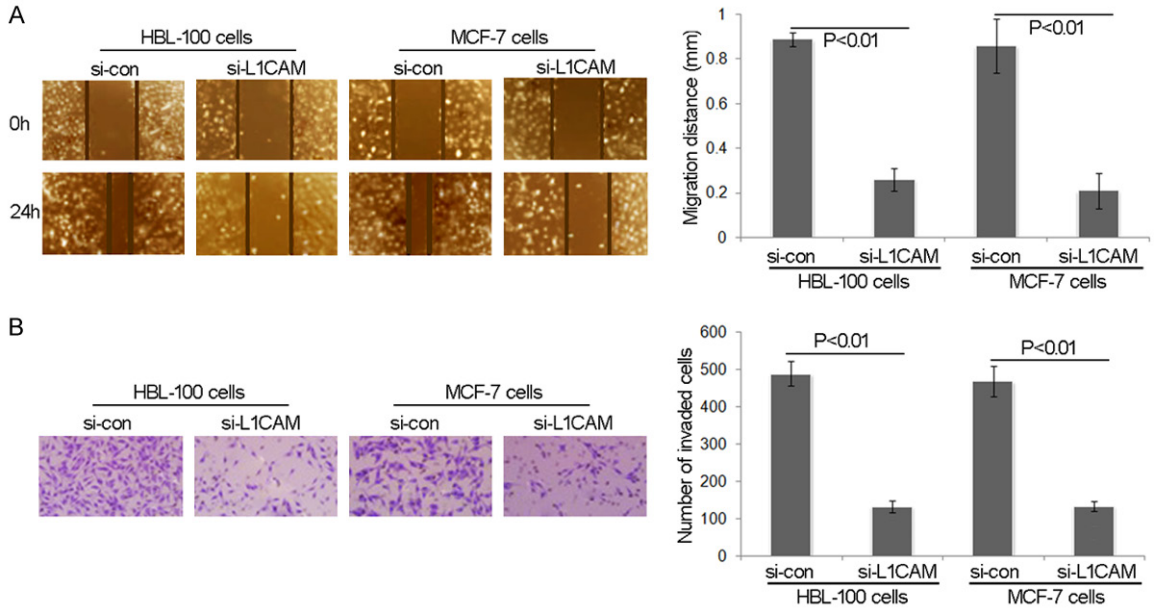

Figure 3. Knockdown of L1CAM expression inhibits cellular motility of breast cancer cells *in vitro*. L1CAM knockdown HBL-100 and MCF-7 cells both showed an approximately 2.5-fold decrease in migration (A) and a 2-fold decrease in invasion (B), compared with L1CAM-overexpressing cells.

Wound healing assay

Wound healing assay was performed to evaluate the effect of L1CAM on breast cancer cell migration ability *in vitro*. Briefly, cells were seeded to nearly complete confluence in a monolayer in 6-well plates. Forty-eight hours following the transfection with either L1CAM-targeting siRNA (si-L1CAM) or nontargeting control siRNA (si-con), cells were serum starved for 12 h. Then, the monolayer was scratched with a 10 μL pipette tip. After that, cells were washed with PBS and cultured in 5% FBS-DMEM at 5% CO_2 and 37°C. The wounded areas were monitored by inverted Leica phase-contrast microscope (Leica DFC 300 FX) and the assays were performed in triplicate.

Cell invasion assay

Cell invasion assays were conducted using transwell chambers (8 μm pore; BD Biosciences, Franklin Lakes, NJ, USA). Briefly, cells were seeded in a 6-well plate and transfected with either L1CAM-targeting siRNA (si-L1CAM) or nontargeting control siRNA (si-con). Forty-eight hours post-transfection, cells were replated at a density of 2.5×10^4 cells per invasion chamber (BD Biosciences, Franklin Lakes, NJ, USA) in serum-free media. After that, serum-containing media was used as a chemoattractant and placed outside of the chamber. Twenty-four hours later, noninvading cells were removed from inside the chamber. Cells on the exterior of the chamber were fixed, stained, visualized and photographed. The assays were performed in triplicate.

Statistical analysis

Data analyses were carried out by the software of SPSS version13.0 for Windows (SPSS Inc, IL, USA). Data were expressed as means ± standard deviation (S.D.) for continuous variables. χ^2 tests were used to assess the associations between L1CAM expression and clinicopathological characteristics. Student's t-test or one-way ANOVA were used to evaluate differences in protein expression, cell migration and invasion. Differences were considered statistically significant when *P* was less than 0.05.

Results

Overexpression of L1CAM protein in human breast cancer tissues

Of the 100 breast cancer patients, 89 (89.0%) were positive for L1CAM immunostaining localized in the membrane of cancer cells (**Figure 1A**), while there was no detectable L1CAM immunoreactivity in 11 cases (11.0%). Non-

cancerous breast tissues showed negative or weak membrane staining of L1CAM (**Figure 1B**). There were 88 of 100 (88.0%) cases of breast cancer overexpressed L1CAM compared with the matched non-cancerous breast tissues (**Figure 1C**). Statistical analysis showed that the L1CAM expression level in breast cancer tissues was higher than that in the matched non-cancerous breast tissues, with mean IRS at 5.12 ± 1.19 vs. 3.08 ± 0.84 ($P<0.05$, **Figure 1D**).

In addition, breast cancer patients with L1CAM levels less than the median IRS value of 5.06 were assigned to the low expression Group (n=49), whereas those with L1CAM levels more than the median IRS value of 5.06 were assigned to the high expression group (n=51).

Overexpression of L1CAM protein associates with aggressive progression of patients with breast cancer

Table 1 summarized the associations between serum L1CAM levels with clinicopathological parameters of patients with breast cancer. Chi-Square analysis showed the significant associations between L1CAM overexpression and high tumor stage (P=0.01, **Table 1**), advanced tumor grade (P=0.03, **Table 1**), positive lymph node metastasis (P=0.01, **Table 1**) and tumor recurrence (P=0.01, **Table 1**) in breast cancer patients. However, no statistically significant associations of L1CAM protein with patients' age, tumor size and histological type of breast cancer were found (all $P>0.05$, **Table 1**).

Knockdown of L1CAM expression inhibits cellular motility of breast cancer cells in vitro

To determine whether the overexpression of L1CAM is required to maintain the cellular motility of HBL-100 and MCF-7 cells, we used the siRNA targeting L1CAM mRNA to silence its expression. As shown in **Figure 2**, the L1CAM siRNA used in this study could reduce the level of L1CAM protein expression by >70% in both HBL-100 and MCF-7 cells. As shown in **Figure 3**, L1CAM knock-down HBL-100 and MCF-7 cells both showed an approximately 2.5-fold decrease in migration and a 2-fold decrease in invasion, compared with L1CAM-overexpressing cells, indicating that L1CAM knock-down could significantly inhibit the migration and invasion of breast cancer cells *in vitro*.

Discussion

Since breast cancer is prone to invade into adjacent regions and to metastasize to lymph nodes and distant organs, it is extremely necessary to identify the related molecules involved into tumor migration and invasion. In the current study, our data demonstrated and functionally characterized L1CAM as an important player in breast cancer progression. We first observed the strongly positive immunostaining of L1CAM protein in cellular membrane of cancer cells in the primary breast cancer tissues, and then found a positive correlation between L1CAM levels and aggressive progression of breast cancer patients. After that, our data also addressed the role of L1CAM in cellular motility of breast cancer cells *in vitro*. To the best of our knowledge, this is the first study to evaluate the clinical significance of L1CAM expression based on a large series of 100 breast cancer patients.

Growing evidence shows that L1CAM expression is increased in various types of cancer, predominantly at the invasive front of tumors and in metastases, suggesting its involvement in advanced tumor progression. Functionally, the overexpression of L1CAM often leads to the increased motility, the enhanced growth rate and the promoted cell transformation and tumorigenicity of malignant cells. For example, Ben et al. [14] reported that the downregulation of L1CAM could inhibit proliferation, invasion and arrest cell cycle progression in pancreatic cancer cells *in vitro*; Kim et al. [10] indicated that L1CAM was highly expressed in the samples taken from patients with anaplastic thyroid carcinomas, and might play an important role in determining tumor behavior and chemosensitivity in cell lines derived from anaplastic thyroid carcinomas; Ito et al. [12] found that L1CAM downregulation by siRNA could significantly decrease cell proliferation, migration, and invasion in gastric cancer cell lines through the ERK pathway. In line with these findings on other malignancies, the current study also demonstrated the oncogenic role of L1CAM in breast cancer and found that the knock-down of L1CAM had the similar suppressive effects on migration and invasion of HBL-100 and MCF-7 cell lines. Moreover, recent studies have revealed that the aberrant expression of L1CAM in clinical tumor samples often conferred the capacity to promote tumor progression. For

example, Wang et al. [23] reported that the expression of L1CAM in gastric cancer was significantly associated with lymph node and distant metastasis, and poor prognosis, implying that L1CAM could be a useful marker to predict tumor progression and prognosis; Bosse et al. [17] identified L1CAM expression as a strong independent predictor for distant recurrence and overall survival in stage I endometrial cancer; Hai et al. [11] recognized L1CAM as an independent prognostic marker in resected non-small cell lung cancer patients, with overexpression strongly associated with worse prognosis. Agree with these previous findings, our data here also indicated the significant associations between L1CAM expression and unfavorable clinicopathological characteristics of breast cancer patients. The expression levels of L1CAM protein in breast cancer tissues with high tumor stage, advanced tumor grade, positive lymph node metastasis and tumor recurrence were all dramatically higher than those with low tumor stage and tumor grade, and without lymph node metastasis and tumor recurrence. Since tumor stage, histological grade, lymph node status and tumor recurrence status have been extensively used as prognostic markers for breast cancer patients, we hypothesized that L1CAM might influence breast cancer prognosis and probability of response to systemic therapies, which are required further validation based on a large cohort of clinical samples.

In conclusion, our results suggest that the overexpression of L1CAM may be related to several established markers of poor prognosis in breast cancer patients. L1CAM might be a potential therapeutic target against metastatic breast cancer.

Disclosure of conflict of interest

None.

Address correspondence to: Dr. Jinhai Tang, Department of General Surgery, Nanjing Medical University Affiliated Jiangsu Cancer Hospital, Nanjing 210009, China. Dr. Feng Jiao, Department of General Surgery, 82 Hospital of PLA, Huai'an, Jiangsu 223001, China. Tel: (86) 25-83283305; Fax: (86) 25-83283597; E-mail: doczhangjian@163.com; 1248179129@qq.com

References

[1] Johnson-Thompson MC, Guthrie J. Ongoing research to identify environmental risk factors in breast carcinoma. Cancer 2000; 88: 1224-1229.

[2] Jemal A, Bray F, CenterMM, Ferlay J, Ward E, FormanD. Global cancer statistics. CA Cancer J Clin 2011; 61: 69-90.

[3] Ginsburg OM, Love RR. Breast cancer: a neglected disease for the majority of affected women worldwide. Breast J 2011; 17: 289-295.

[4] Weigelt B, Peterse JL, van't Veer LJ. Breast cancer metastasis: markers and models. Nat Rev Cancer 2005; 5: 591-602.

[5] Lund K, Dembinski JL, Solberg N, Urbanucci A, Mills IG, Krauss S. Slug-Dependent Upregulation of L1CAM Is Responsible for the Increased Invasion Potential of Pancreatic Cancer Cells following Long-Term 5-FU Treatment. PLoS One 2015; 10: e0123684.

[6] Doberstein K, Milde-Langosch K, Bretz NP, Schirmer U, Harari A, Witzel I, Ben-Arie A, Hubalek M, Müller-Holzner E, Reinold S, Zeimet AG, Altevogt P, Fogel M. L1CAM is expressed in triple-negative breast cancers and is inversely correlated with androgen receptor. BMC Cancer 2014; 14: 958.

[7] Mohanan V, Temburni MK, Kappes JC, Galileo DS. L1CAM stimulates glioma cell motility and proliferation through the fibroblast growth factor receptor. Clin Exp Metastasis 2013; 30: 507-520.

[8] Itoh K, Fujisaki K, Watanabe M. Human L1CAM carrying the missense mutations of the fibronectin-like type III domains is localized in the endoplasmic reticulum and degraded by polyubiquitylation. J Neurosci Res 2011; 89: 1637-1645.

[9] Yi YS, Baek KS, Cho JY. L1 cell adhesion molecule induces melanoma cell motility by activation of mitogen-activated protein kinase pathways. Pharmazie 2014; 69: 461-467.

[10] Kim KS, Min JK, Liang ZL, Lee K, Lee JU, Bae KH, Lee MH, Lee SE, Ryu MJ, Kim SJ, Kim YK, Choi MJ, Jo YS, Kim JM, Shong M. Aberrant l1 cell adhesion molecule affects tumor behavior and chemosensitivity in anaplastic thyroid carcinoma. Clin Cancer Res 2012; 18: 3071-3078.

[11] Hai J, Zhu CQ, Bandarchi B, Wang YH, Navab R, Shepherd FA, Jurisica I, Tsao MS. L1 cell adhesion molecule promotes tumorigenicity and metastatic potential in non-small cell lung cancer. Clin Cancer Res 2012; 18: 1914-1924.

[12] Ito T, Yamada S, Tanaka C, Ito S, Murai T, Kobayashi D, Fujii T, Nakayama G, Sugimoto H, Koike M, Nomoto S, Fujiwara M, Kodera Y. Overexpression of L1CAM is associated with tumor progression and prognosis via ERK signaling in gastric cancer. Ann Surg Oncol 2014; 21: 560-568.

[13] Guo X, Xiong L, Zou L, Sun T, Zhang J, Li H, Peng R, Zhao J. L1 cell adhesion molecule overexpression in hepatocellular carcinoma associates with advanced tumor progression and poor patient survival. Diagn Pathol 2012; 7: 96.
[14] Ben Q, An W, Fei J, Xu M, Li G, Li Z, Yuan Y. Downregulation of L1CAM inhibits proliferation, invasion and arrests cell cycle progression in pancreatic cancer cells in vitro. Exp Ther Med 2014; 7: 785-790.
[15] Kajiwara Y, Ueno H, Hashiguchi Y, Shinto E, Shimazaki H, Mochizuki H, Hase K. Expression of l1 cell adhesion molecule and morphologic features at the invasive front of colorectal cancer. Am J Clin Pathol 2011; 136: 138-144.
[16] Bondong S, Kiefel H, Hielscher T, Zeimet AG, Zeillinger R, Pils D, Schuster E, Castillo-Tong DC, Cadron I, Vergote I, Braicu I, Sehouli J, Mahner S, Fogel M, Altevogt P. Prognostic significance of L1CAM in ovarian cancer and its role in constitutive NF-κB activation. Ann Oncol 2012; 23: 1795-1802.
[17] Suh DH, Kim MA, Kim HS, Chung HH, Park NH, Song YS, Kang SB. L1 cell adhesion molecule expression is associated with pelvic lymph node metastasis and advanced stage in diabetic patients with endometrial cancer: a matched case control study. J Cancer Prev 2014; 19: 231-239.
[18] Li Y, Galileo DS. Soluble L1CAM promotes breast cancer cell adhesion and migration in vitro, but not invasion. Cancer Cell Int 2010; 10: 34.
[19] Zhang H, Wong CC, Wei H, Gilkes DM, Korangath P, Chaturvedi P, Schito L, Chen J, Krishnamachary B, Winnard PT Jr, Raman V, Zhen L, Mitzner WA, Sukumar S, Semenza GL. HIF-1-dependent expression of angiopoietin-like 4 and L1CAM mediates vascular metastasis of hypoxic breast cancer cells to the lungs. Oncogene 2012; 31: 1757-1770.
[20] Tagliavacca L, Colombo F, Racchetti G, Meldolesi J. L1CAM and its cell-surface mutants: new mechanisms and effects relevant to the physiology and pathology of neural cells. J Neurochem 2013; 124: 397-409.
[21] Doberstein K, Harter PN, Haberkorn U, Bretz NP, Arnold B, Carretero R, Moldenhauer G, Mittelbronn M, Altevogt P. Antibody therapy to human L1CAM in a transgenic mouse model blocks local tumor growth but induces EMT. Int J Cancer 2015; 136: E326-339.
[22] Dhennin-Duthille I, Gautier M, Faouzi M, Guilbert A, Brevet M, Vaudry D, Ahidouch A, Sevestre H, Ouadid-Ahidouch H. High expression of transient receptor potential channels in human breast cancer epithelial cells and tissues: correlation with pathological parameters. Cell Physiol Biochem 2011; 28: 813-822.
[23] Wang YY, Li L, Zhao ZS, Wang YX, Ye ZY, Tao HQ. L1 and epithelial cell adhesion molecules associated with gastric cancer progression and prognosis in examination of specimens from 601 patients. J Exp Clin Cancer Res 2013; 32: 66.