

Case Report

A case report on intermediate-grade malignant meningeal melanocytoma with elevated cell proliferation index

Jian Sun¹, Chengjun Wang¹, Qingming Shu², Jie Liu¹, Gengsheng Mao¹

Departments of ¹Neurosurgery, ²Pathology, Chinese People's Armed Police Force General Hospital, Beijing 100039, China

Received July 14, 2015; Accepted August 23, 2015; Epub September 1, 2015; Published September 15, 2015

Abstract: Meningeal melanocytoma is a kind of extremely rare pigmented tumor of the central nervous system, which often occurs in the groove around the base of the brain and spinal pia mater. Age of onset is 40 to 50 years old, mostly presenting a benign course of disease and the prognosis is good. Case reports of partial invasion or metastasis from lesions are even rarer. This report described a case of 56-year-old meningeal melanoma patient with partial skull and muscle invasion at the lantooccipital transition zone. Intraoperative histological examination showed moderate malignancy and Ki-67 index was 10%.

Keywords: Meningeal melanocytoma, neurosurgery, tumor

Introduction

Meningeal melanocytoma is a kind of extremely rare pigmented tumor of the central nervous system, which often occurs in the groove around the base of the brain and spinal pia mater, taking neurological symptoms or hydrocephalus caused by tumor compression as its clinical manifestations. Age of onset is 40 to 50 years old, mostly presenting a benign course of disease and the prognosis is good. Case reports of partial invasion or metastasis from lesions are even rarer. MIB-1/Ki-67 labeling index is used as one of markers in recent years to predict disease progression of malignant lesions [1]. The index Ki-67 of meningeal melanoma reported is often less than 3%. MIB-1/Ki-67 index of a few patients with intermediate-grade malignant meningeal melanocytoma was found increased [2]. Therefore, rising of MIB-1/Ki-67 index may help clinicians to determine infiltrativeness, vicious transformation and risk of recurrence of melanoma. This report described a case of 56-year-old meningeal melanoma patient with partial skull and muscle invasion at the lantooccipital transition zone. As for the patient, tumor recurred at the place

where surgical removal had been conducted more than a year later. Intraoperative histological examination showed moderate malignancy and Ki-67 index was 10%.

Case report

A 56-year-old Chinese Han male was hospitalized for "over a year after surgical removal of melanoma, intermittent headache lasted for more than half a year and worsened in February". The intermittent headache was a swelling pain, and mainly occurred around back-occipital. There was no symptom of nausea, vomiting, loss of consciousness, limbs twitch or incontinence. This study was conducted in accordance with the declaration of Helsinki. This study was conducted with approval from the Ethics Committee of Chinese People's Armed Police Force General Hospital. Written informed consent was obtained from the participant.

Magnetic resonance image (MRI) of cervical spine showed that clumps of short T1 at the rear the foramen magnum were mixed with T2 signal lesions (**Figure 1A**). After enhancing the signal, visibility was significantly enhanced and

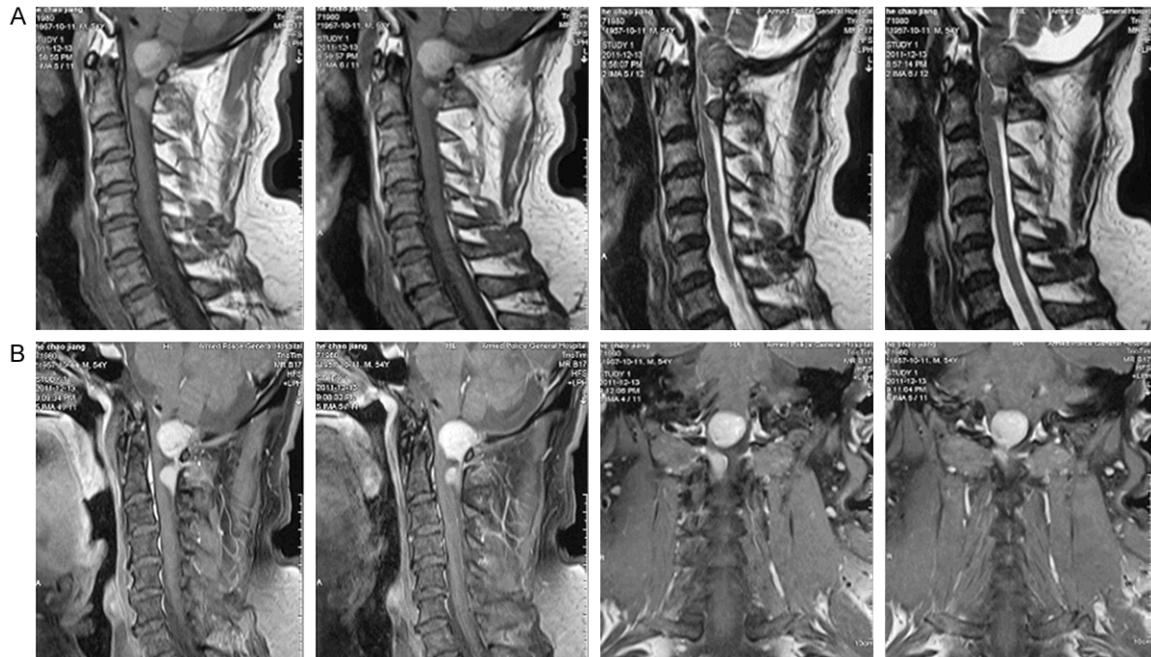


Figure 1. A. Magnetic resonance image (MRI) of cervical spine showed that clumps of short T1 at the rear the foramen magnum were mixed with T2 signal lesions; B. After enhancing the signal, visibility was significantly enhanced and punctuate lesions are visible without seeing enhancement area.

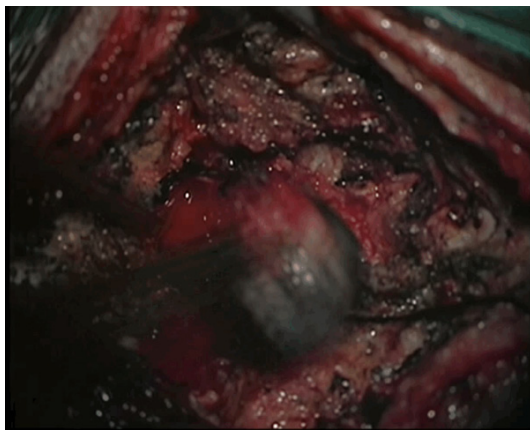


Figure 2. Tumors located between planchnic layers of endorhachis are black, quasi-circular, toughly with poor ability of blood supplying (Magnification $\times 40$).

punctuate lesions are visible without seeing enhancement area (**Figure 1B**).

The patient underwent a sub-occipital tumor resection operation via the midline part and another decompression operation in December of 2011. During the operation, melanotic black endorhachis was observed, and two tumors were found at occipital junction and acinic C2 respectively. The two black lesions were

quasi-circular and tough with poor ability of blood supplying, measuring $2 \times 2 \times 2 \text{ cm}^3$ and $1 \times 1 \times 1 \text{ cm}^3$ respectively, located in the space between planchnic layers of endorhachis (**Figure 2**). Considering the relatively high risk of total removal of the tumors due to their location and possibility of worsening, partial resection was adopted.

Microscopic examination showed that the tumor tissue was mainly composed of spindle cells arranged in a spiral shape. Abundant cytoplasm was found with uneven melanin granules inside, nuclear oval of which was circular and contained vacuoles, prominent nucleoli and rare mitotic. Melanoma can be seen gathering among tumor cells (**Figure 3**). Immunohistochemical staining revealed that Ki-67 staining index was approximately 10% (**Figure 4**). The final pathological diagnosis was an intermediate-grade meningeal melanocytoma.

In the reexamination within a year after the first operation, no symptom was found conspicuously worsened and postoperative MRI showed that the sizes of the tumors were not significantly enlarged (**Figure 5**). However, the patient had the symptom of headache again in October of 2013 and MRI showed bigger tumors and

A rare case of moderate-malignant meningeal melanoma

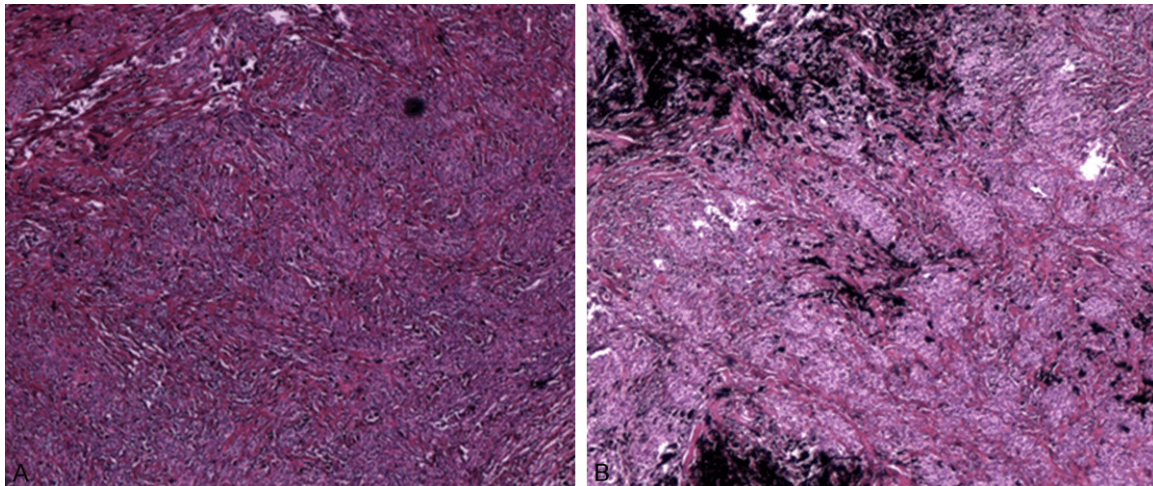


Figure 3. Chemical examination on immune tissue showed markers of melanoma in which A was based on the first operation and B was based on the second operation (Magnification $\times 40$).

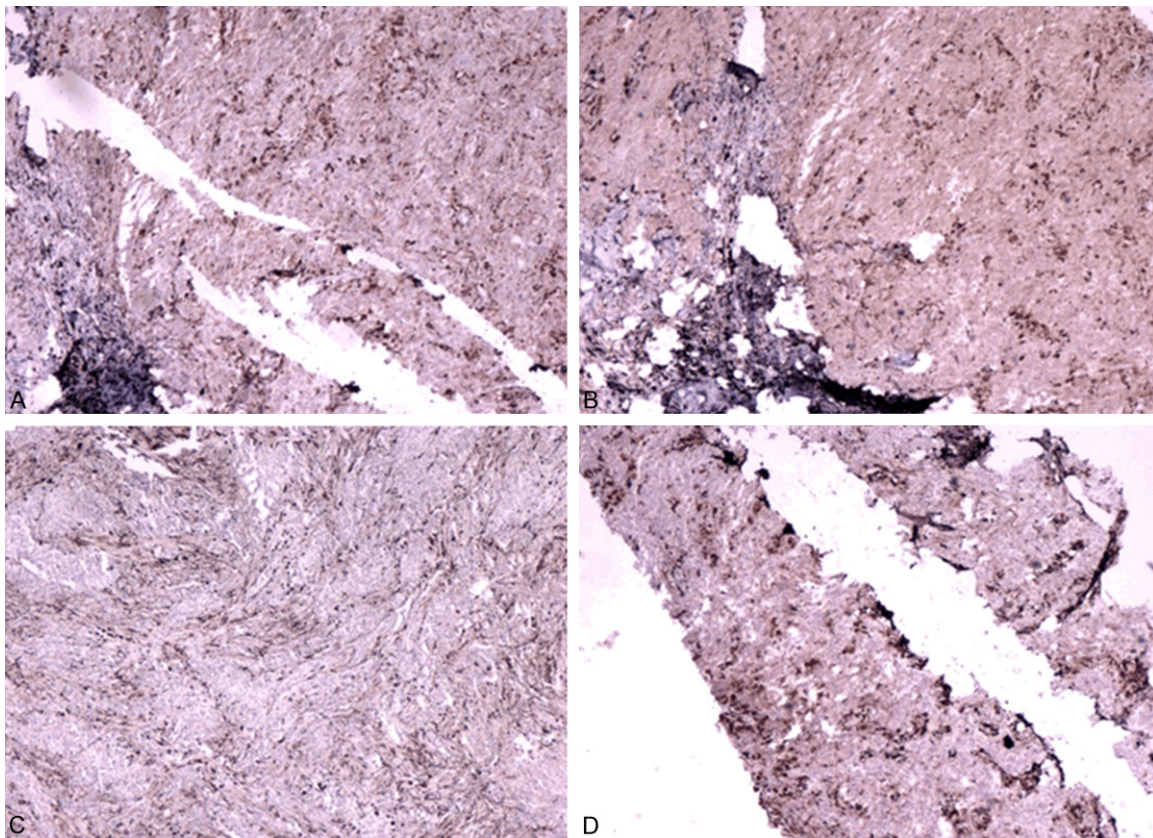


Figure 4. HMB-45 (A), S-100 (B), vimentin (C) were expressed positive and proliferative activity index of Ki-67 (D) was 10% (Magnification $\times 40$).

more deformed spinal cord compared with those in imaging prior to first operation. Thus, second surgery was carried on, during which the whole dura, the skull and parts of the muscle were found blackened. Tumors on the

meninges were removed under the microscope, but skull and muscles were not dealt with. Symptomatic treatment was adopted and the reexamination three months later showed that original lesions had been removed and the

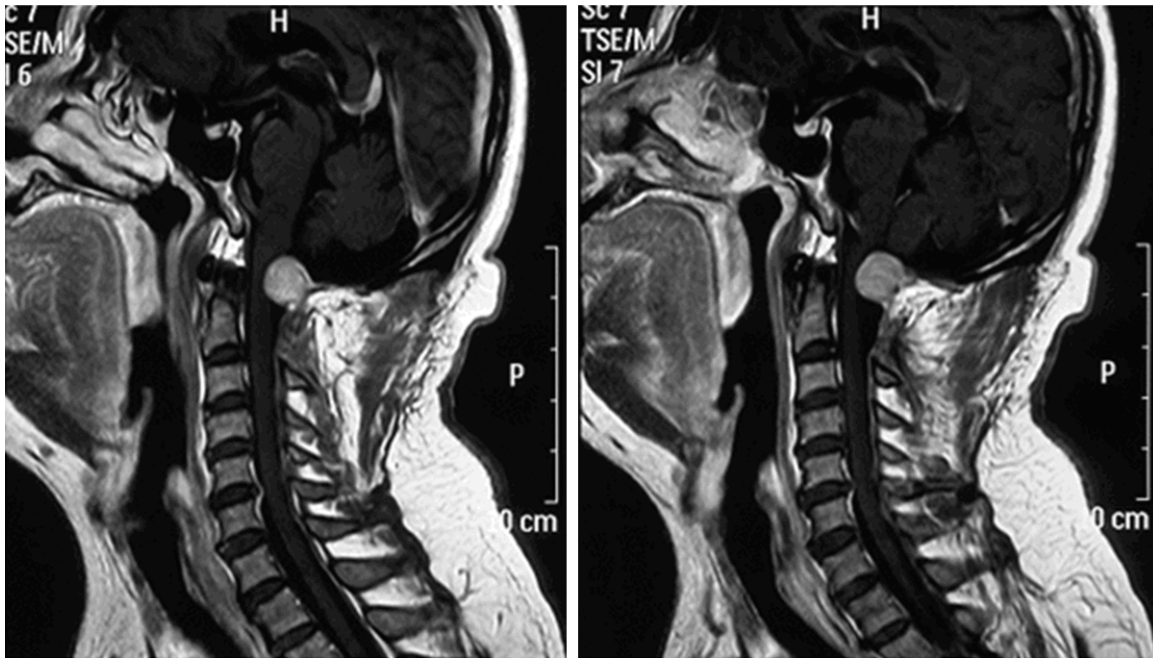

Figure 5. In the reexamination within a year after the first operation, no symptom was found conspicuously worsened and postoperative MRI showed that the sizes of the tumors were not significantly enlarged.

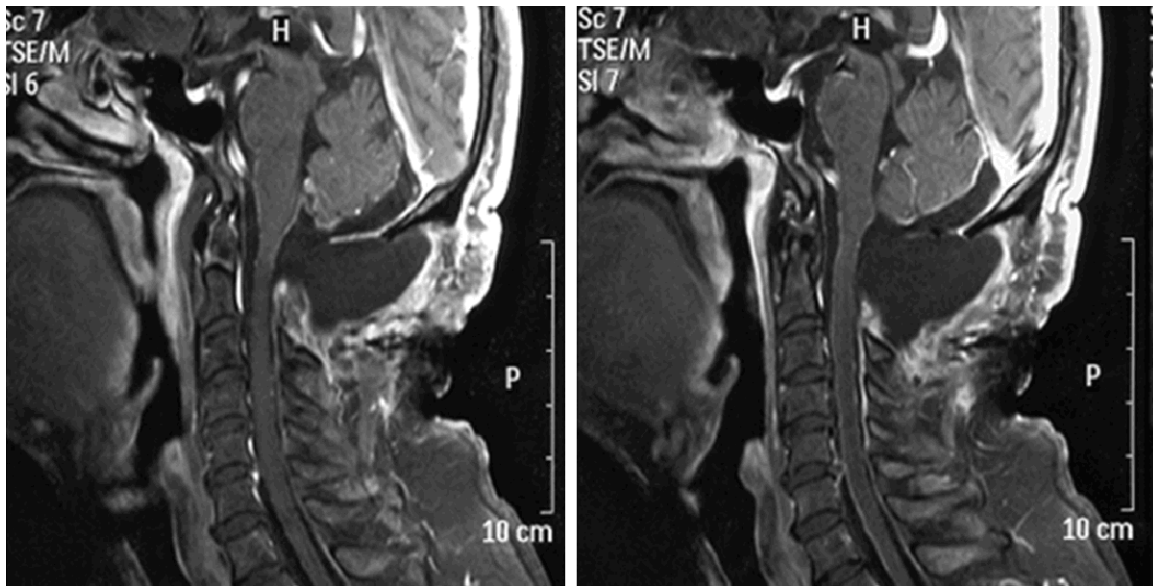


Figure 6. Symptomatic treatment was adopted and the reexamination three months later showed that original lesions had been removed and the patient was recovering in good condition without recurrence.

patient was recovering in good condition without recurrence (**Figure 6**).

Discussion

Pathogenesis of meningeal melanoma is unclear as yet. It is a kind of very rare brain tumor

with a proportion of only 0.06%-0.1% of all types [3]. Generally, leptomeningeal lesions mainly derive from melanoma cells, while melanocytes derive from the neural crest, and are often scattered among cells of the groove between the base of the brain, back of medulla and pia mater cells of the upper cervical cord,

thus the tumor prevailingly occurs at the bottom of the skull and in the spinal canal [4]. Primary purpose of defining meningeal melanoma is to distinguish meningeal tumor-derived melanocytes from Schwann cells or meningeal fibroblasts. Meningeal melanoma is usually a slowly-growing tumor, benignly growing with tumor tissue of complete capsule. Mass effect is the main cause of the neurological symptoms. Reported by documents, since 1987, according to the pathological diagnosis, there are just over 30 cases of primary intracranial meningeal melanoma diagnosed according to pathology [3]. Meningeal melanoma of this patient occurs at the atlantooccipital junction and partially invades skull and muscle. These pathological features indicated characteristic of intermediate-grade meningeal melanocytoma, making the case an extremely rare one.

Generally, meningeal melanocytoma presents round, oval or slightly sub-leaf shape, or high density shadow under computed tomographic (CT) scan, strengthened shadow appeared under strengthened scan, and shadow of high density occurred with tumor bleeding. While in MRI, meningeal melanocytoma usually presents high T1 signal and short low T2 signal. Characteristics of MRI signals are closely related with content of melanin, that is to say, the more melanin, the shorter relaxation times of T1 and T2 [5]. Because of lacking specific imaging performance, imaging examination often misdiagnoses meningeal melanoma as meningioma or glioma. Although imaging examination cannot make a final diagnosis, it can help determine condition of the disease. In addition, due to obvious difference of biological behavior, treatment and prognosis of these tumors, pathological diagnosis is extremely necessary.

With the gross observation, the majority of meningeal melanomas present dark brown to black due to abundant presentation of melanin pigment. Visible tumors under the microscope are consisted of fusiform, plump spindle cells and epithelioid cells in shape of plump oval or polygonal and nuclear round, oval or vacuoles shapes with prominent nucleoli but rare mitotic figures, tumor necrosis and hemorrhage. Melanoma markers HMB-45 is visible in immunohistochemical examination, and S-100, vimentin are highly expressed [6]. Proliferative

activity index Ki-67 is often expressed as less than 3%. MIB-1/Ki-67 labeling index is used as one of the markers to predict malignant progression of lesions in recent years. MIB-1/Ki-67 index was found increased in a minority of patients with moderate meningeal malignant melanoma cells. Therefore, rising of MIB-1/Ki-67 index may help clinicians to determine invasiveness, malignant transformation and risk of recurrence of melanoma, so as to help to develop rational treatment strategies. In this patient, the Ki-67 index was approximately 10%, ranking interposed between benign and malignant tumor as intermediate-grade malignant tumor.

Complete removal of tumors may be an effective way to cure meningeal melanoma. Nevertheless, clinical patients are often not suitable for full-cut surgery, such as patients with excessive angiogenesis, excessive tumor volume or poor-located tumors. These patients are not appropriate to undergo gross total resection due to its high risk, and must therefore undergo only partial resection [7]. The influences of postoperative radiotherapy to residual and recurrent meningeal melanoma are still unclear. Chow et al. [8] conducted a literature review and showed that the long-term survival of cases who adopted tumor subtotal resection was irrelevant to the presence of radiotherapy after the surgery, suggesting that postoperative radiotherapy should be individualized. Radiotherapy should be considered by patients who had residual symptoms, disease progression or recurrence but was not suitable for further resection [9]. Due to the existence of recurrence risk, close follow-up is necessary after surgery [10]. During the first surgery of this patient, the skull was found infiltrated, and the lesions were in the transition atlantooccipital region, which meant high risk of whole removal. As a result, it was dealt with partial resection, removing partial occipital bone and decompressing it. The results of the pathological examination were consistent with meningeal melanoma. The prognosis of patients with meningeal melanoma was relatively good, most of whom survived a few years after diagnosis. However, a few patients (especially those with subtotal resection) with meningeal melanoma were reported of malignant transformation, proliferation of local recurrence or leptomeningeal.

In summary, this is a rare case of moderate-malignant meningeal melanoma with increased cell proliferation index and infiltration of partial skull and muscle. There is a risk of recurrence after surgery, thus regular reexaminations are needed. This case may be of great significance of enlightenment for different histological behavior, diagnosis and treatment of meningeal melanoma.

Disclosure of conflict of interest

None.

Address correspondence to: Dr. Gengsheng Mao, Department of Neurosurgery, Chinese People's Armed Police Force General Hospital, 69 Yongdinglu, Haidian District, Beijing 100039, China. E-mail: gengshengmao@163.com

References

- [1] Quatresooz P, Piérard-Franchimont C, Piérard GE. Highlighting the immunohistochemical profile of melanocytomas: review. *Oncol Rep* 2008; 19: 1367-1372.
- [2] Navas M, Pascual JM, Fraga J, Pedrosa M, Shakur S, Carrasco R, Martínez P, Manzanares R, de Sola RG. Intracranial intermediate-grade meningeal melanocytoma with increased cellular proliferative index: an illustrative case associated with a nevus of Ota. *J Neurooncol* 2009; 95: 105-115.
- [3] Fan MC, Wang JF, Fu WW, Liu K, Li LD, Sun P. Primary meningeal melanocytoma located in foramen magnum: a case report and review of the literatures. *Chin Med Sci J* 2012; 27: 115-120.
- [4] Rades D, Schild SE, Tatagiba M, Molina HA, Alberti W. Therapy of meningeal melanocytomas. *Cancer* 2004; 100: 2442-2447.
- [5] Offiah CJ, Laitt RD. Case report: Intracranial meningeal melanocytoma: a cause of high signal on T1- and low signal on T2-weighted MRI. *Clin Radiol* 2006; 61: 294-298.
- [6] Kan P, Shelton C, Townsend J, Jensen R. Primary Malignant Cerebellopontine Angle Melanoma Presenting as a Presumed Meningioma: Case Report and Review of the Literature. *Skull Base* 2003; 13: 159-166.
- [7] Kim OH, Kim SJ, Choo HJ, Lee SJ, Lee IS, Kim JY, Kim H. Spinal meningeal melanocytoma with benign histology showing leptomeningeal spread: case report. *Korean J Radiol* 2013; 14: 470-476.
- [8] Chow M, Clarke DB, Maloney WJ, Sangalang V. Meningeal melanocytoma of the planum sphenoidale. Case report and review of the literature. *J Neurosurg* 2001; 94: 841-845.
- [9] Horn EM, Nakaji P, Coons SW, Dickman CA. Surgical treatment for intramedullary spinal cord melanocytomas. *J Neurosurg Spine* 2008; 9: 48-54.
- [10] Jaiswal S, Vij M, Tungria A, Jaiswal AK, Srivastava AK, Behari S. Primary melanocytic tumors of the central nervous system: a neuro-radiological and clinicopathological study of five cases and brief review of literature. *Neurol India* 2011; 59: 413-419.