

Case Report

IgG4-related paranasal sinus and intra-orbital disease diagnosed by endoscopic transnasal biopsy

Kuang-Hsuan Shen¹, Bo-Nien Chen^{2,3}, Tsong-Chi Chang⁴, Shiu-an-Li Wey⁵

¹Department of Otolaryngology, MacKay Memorial Hospital, Taipei, Taiwan; ²Department of Otolaryngology-Head and Neck Surgery, Hsinchu Mackay Memorial Hospital, Hsinchu, Taiwan; ³Mackay Junior College of Medicine, Nursing, and Management, New Taipei, Taiwan; ⁴Department of Ophthalmology, Hsinchu Mackay Memorial Hospital, Hsinchu, Taiwan; ⁵Department of Pathology, Hsinchu Mackay Memorial Hospital, Hsinchu, Taiwan

Received September 15, 2016; Accepted September 28, 2016; Epub November 1, 2016; Published November 15, 2016

Abstract: ImmunoglobulinG4-related disease (IgG4-RD) is a novel systemic fibroinflammatory disorder. Here, we report a 49-year-old man who presented with nasal obstruction, exophthalmos, and diplopia for more than 3 years. Progressive left extraocular movement limitation and left visual acuity impairment were observed for 1 week. Computed tomography revealed a moderately enhanced and ill-defined lesion involving bilateral retro-orbital fat; bilateral intraorbital extraocular muscles; Lt orbital nerve; and bilateral paranasal sinus. IgG4-related sino-orbital disease was suspected with the serum IgG4 concentration was up to 1250 mg/dL. The patient subsequently underwent left endoscopic orbital surgical decompression and tissue biopsy. The histopathological sections of the patient revealed lymphoplasmacytic infiltration and fibrosis of >100 IgG4 cells/HPF and an IgG4+/IgG+ cell ratio of >40%. Thus, IgG4-related sino-orbital disease was diagnosed on the basis of comprehensive criteria for IgG4-RD. Prednisolone was postoperatively administered, and the patient symptoms improved following surgery and glucocorticoid treatment.

Keywords: IgG4-related disease, sino-orbital disease, endoscopic biopsy, corticosteroid

Introduction

Immunoglobulin G4-related disease (IgG4-RD) is a novel clinical entity characterized by an elevated serum IgG4 concentration and tumefaction or tissue infiltration by IgG4+ plasma cells [1].

The disease was not recognized as a systemic condition until 2003, when extrapancreatic manifestations were identified in patients with autoimmune pancreatitis [2]. Definitive diagnosis typically necessitates a biopsy, an insightful interpretation of the pathology, and a rigorous clinicopathological correlation [3].

IgG4-RD, a benign disease, involves lymphoplasmacytic infiltration at various sites and typically affects the pancreas, bile ducts, lacrimal and salivary glands, skin, kidneys, and retroperitoneum, particularly in middle-aged and elderly patients [4].

Conventional therapy includes glucocorticoids (prednisolone, 0.6-1.0 mg/kg daily for 2-4

weeks); conventional steroid-sparing agents, such as azathioprine, mycophenolate mofetil, and methotrexate; and B-cell depletion therapy (rituximab) [3].

However, IgG4-related paranasal sinus and intra-orbital disease has rarely been reported. Here, we report a case involving a patient with IgG4-related sino-orbital disease who underwent left endoscopic orbital decompression with biopsy and received glucocorticoids as the additional treatment.

Case report

A 49-year-old man experienced nasal obstruction, exophthalmos, and diplopia for more than 3 years. Because of left extraocular movement (EOM) limitation with left eyelid swelling, his diplopia worsened in the previous week and was accompanied by low-grade fever; therefore, he visited our hospital (**Figure 1A**). Several blood investigations were conducted, including a complete blood cell count; thyroid pro-

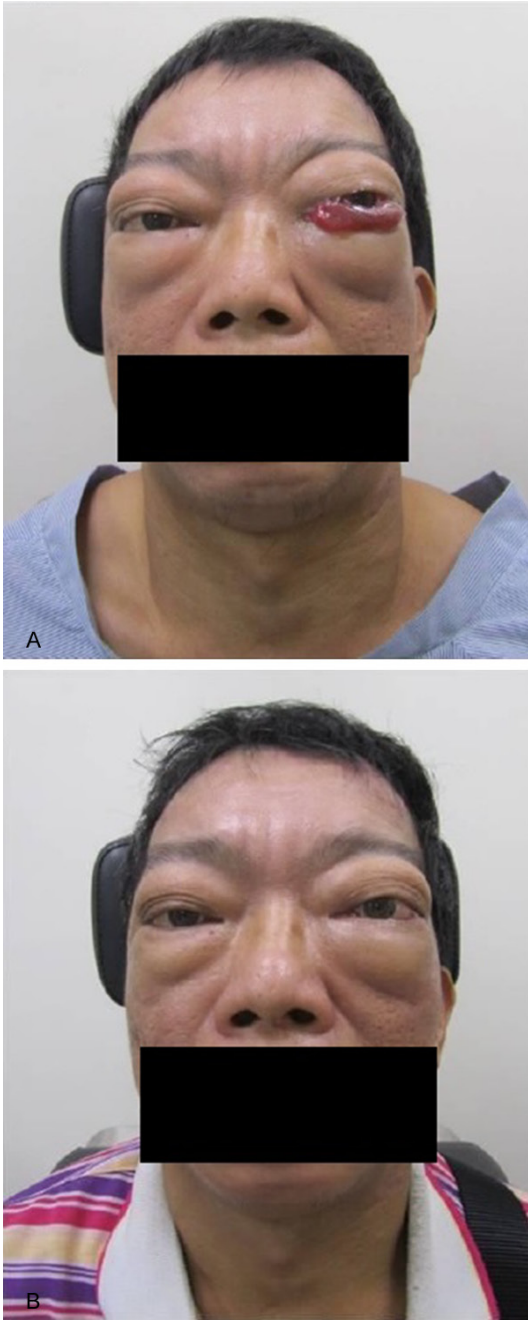


Figure 1. A: The patient's pre-operation picture show exophthalmos and progressive left EOM limitation. B: The patient's exophthalmos and EOM limitation much improved after Lt orbital decompression and corticosteroid one week later.

filing (free thyroxine, thyroid-stimulating hormone, and triiodothyronine); electrolyte, creatinine, and blood urea nitrogen levels; and the erythrocyte sedimentation rate (ESR) and IgG4 concentration. All the results were within the reference range, except aserum IgG4 concen-

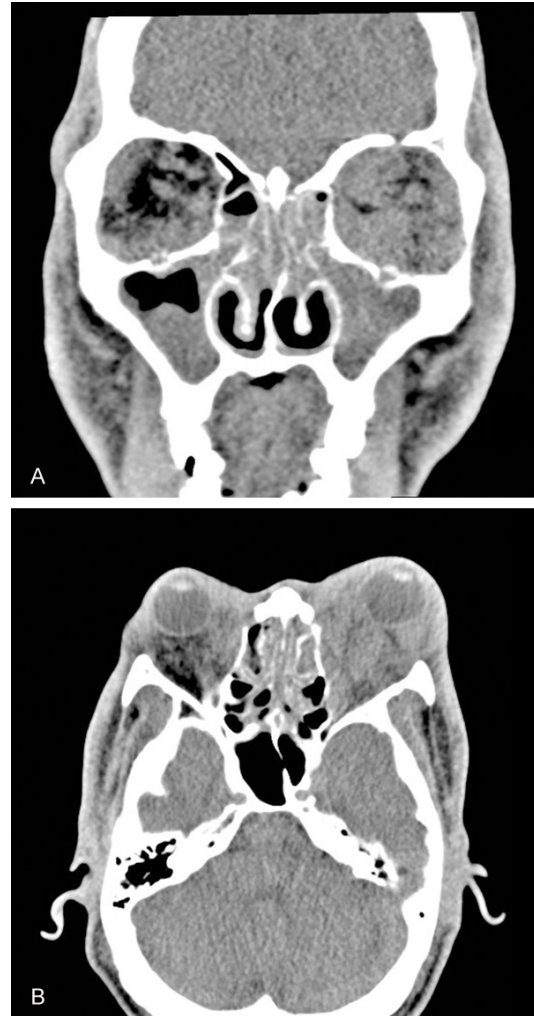

Figure 2. A: Computed tomography showing enhancement involving bilateral ethmoid, maxillary, and sphenoid sinus. B: Computed tomography revealed a moderately enhanced and ill-defined lesion involving bilateral retro-orbital fat; bilateral intra-orbital extraocular muscles; Lt orbital nerve.

tration was up to 1250 (mg/dL) and ESR (16 mm/h).

An ophthalmological examination revealed the highest correct visual acuity of 0.9 (oculus dexter) and 0.6 (oculus sinister) and an *intraocular pressure* of 16/20 mmHg.

CT confirmed an enhanced and ill-defined lesion involving bilateral retro-orbital fat; orbital EO muscles; Lt orbital nerve; and bilateral ethmoid, maxillary, and sphenoid sinus (**Figure 2A, 2B**). On the basis of these findings, IgG4-related sino-orbital disease was suspected. Therefore, the patient underwent left endoscopic orbital

IgG4-related sino-orbital disease

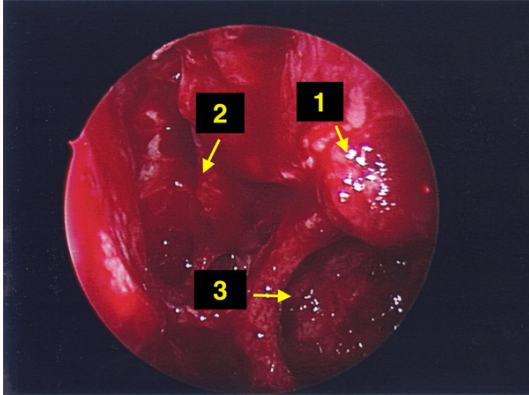


Figure 3. We performed left endoscopic orbital surgical decompression and tissue biopsy of Lt lamina papyracea (1. Lt orbital content tissue; 2. Lt posterior ethmoid sinus; 3. Lt maxillary sinus ostium).

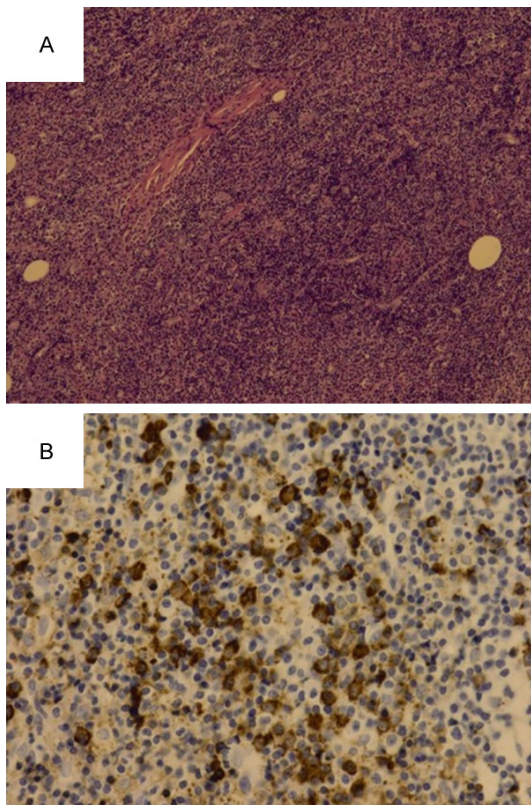


Figure 4. A: The histopathological findings show lymphoplasmacytic infiltration and fibrosis (H&E) ($\times 100$). B: Immunohistochemistry findings show the infiltration of IgG4-positive lymphoplasmacytic cells (IgG4) ($\times 400$).

decompression and tissue biopsy for further management and diagnosed (**Figure 3**).

The histopathological sections of his sino-orbital tissues revealed lymphoplasmacytic infiltra-

tion and fibrosis (**Figure 4A**), and an immunohistochemical analysis showed the infiltration of IgG4-positive lymphoplasmacytic cells (>100 IgG4+ plasma cells/high power field [HPF]) and an IgG4+/IgG+ cell ratio of $>40\%$ (**Figure 4B**).

Accompanied with the serum IgG4 concentration was up to 1250 mg/dL. Thus, IgG4-related sino-orbital disease was diagnosed on the basis of comprehensive criteria for IgG4-RD [1].

The EOM and visual acuity markedly improved following endoscopic orbital decompression surgery (**Figure 1B**). The patient was subsequently prescribed prednisolone, 30 mg daily for 4 weeks and subsequently tapering to 15 mg daily for 2 months. Interval CT 4 months following the initiation of steroids revealed complete resolution. We also conducted a series of examinations, including chest CT, abdominal CT, and serum biochemistry, and did not observe other organ manifestation.

Discussion

IgG4-RD is a novel systemic fibroinflammatory condition [5]. According to a previous review, IgG4-RD is a protean condition that mimics many malignant, infectious, and inflammatory disorders [3].

IgG4-related sino-orbital disease may cause progressive exophthalmos and orbital area swelling and further affect the EOM and visual acuity. Differentiating this disease from thyroid ophthalmopathy, orbital cellulitis, sinusitis with sino-orbital complications, or other congenital ptosis diseases is crucial.

In our case, the exophthalmos and chemosis indicated the spread of an inflammatory process in the anterior of the orbit. The EOM was limited, and the vision was weakened because of the pressure on the optic nerve. A conservative treatment does not rapidly reduce the symptoms; therefore, surgery was obligatory in our case.

IgG4-RD is typically considered a rare disease, and its accurate epidemiology has not been completely clarified. Moreover, despite recent advances in the identification of the underlying immunological processes, the pathophysiology of IgG4-RD is incompletely understood. The diagnostic workup of IgG4-RD is complex and typically requires a combination of clinical examination and imaging, histological, and serological analyses [6].

IgG4-related sino-orbital disease

According to comprehensive criteria for IgG4-RD, its diagnosis is definitive in patients with the following characteristics: (1) organ enlargement, mass or nodular lesions, or organ dysfunction; (2) a serum IgG4 concentration of >135 mg/dL; and (3) histopathological findings of >10 IgG4 cells/HPF and an IgG4+/IgG+ cell ratio of >40%. Our patient fulfilled all these criteria, and IgG4-related sino-orbital disease was subsequently diagnosed [2].

According to a recently published consensus statement on the treatment of IgG4-RD, most IgG4-RD experts still consider glucocorticoids as the first-line therapy for active, untreated disease. Remission induction is commonly initiated with 30-40 mg/day prednisone or a weight-adjusted dose at 0.6 mg/kg of body weight per day, which can be varied according to the disease activity and severity. A slow tapering of the glucocorticoid dose should be initiated 2-4 weeks after the therapy induction and continued for 3-6 months [6].

Because glucocorticoid therapy is effective in treating IgG4-RD, it may be considered the first treatment option. However, therapeutic diagnosis with a glucocorticoid dosage is not recommended when differentiation from infectious disease is difficult [6].

Therefore, endoscopic orbital decompression surgery combined with glucocorticoid administration may be an effective therapeutic option for patients diagnosed with IgG4-related sino-orbital disease presenting with orbital nerve compression, such as the present case, considering the initial side effects of corticosteroid dosages.

IgG4-RD is relatively novel, and its prognosis has not been adequately described. Additional studies on its long-term prognosis are warranted.

Conclusion

In otolaryngology, organ-specific criteria have been established for diagnosing IgG4RD in the salivary glands but not in the sino-orbital region. We diagnosed the present case on the basis of comprehensive criteria for IgG4-RD. The most crucial diagnostic distinction is among malignancies, infections, and inflammatory disorders.

IgG4-related sino-orbital disease is rare; the combination of surgery decompression and tissue biopsy with corticosteroid treating this disease yielded a marked response in our case.

Accurate diagnosis through routine histopathology is difficult; hence, immunohistochemistry combined with clinical presentations are required for proper diagnosis and appropriate management.

Awareness of IgG4-RD can facilitate prompt diagnosis and appropriate management of the disease.

Disclosure of conflict of interest

None.

Address correspondence to: Dr. Bo-Nien Chen, Department of Otolaryngology-Head and Neck Surgery, Hsinchu MacKay Memorial Hospital, No. 690, Sec. 2, Guangfu Rd., East Dist., Hsinchu 30071, Taiwan. E-mail: chenbonien@yahoo.com.tw

References

- [1] Umehara H, Okazaki K, Masaki Y, Kawano M, Yamamoto M, Saeki T, Matsui S, Yoshino T, Nakamura S, Kawa S, Hamano H, Kamisawa T, Shimosegawa T, Shimatsu A, Nakamura S, Ito T, Notohara K, Sumida T, Tanaka Y, Mimori T, Chiba T, Mishima M, Hibi T, Tsubouchi H, Inui K and Ohara H. Comprehensive diagnostic criteria for IgG4-related disease (IgG4-RD), 2011. *Mod Rheumatol* 2012; 22: 21-30.
- [2] Kamisawa T, Funata N, Hayashi Y, Eishi Y, Koike M, Tsuruta K, Okamoto A, Egawa N and Nakajima H. A new clinicopathological entity of IgG4-related autoimmune disease. *J Gastroenterol* 2003; 38: 982-984.
- [3] Kamisawa T, Zen Y, Pillai S and Stone JH. IgG4-related disease. *Lancet* 2015; 385: 1460-1471.
- [4] Deshpande V, Zen Y, Chan JK, Yi EE, Sato Y, Yoshino T, Kloppel G, Heathcote JG, Khosroshahi A, Ferry JA, Aalberse RC, Bloch DB, Brugge WR, Bateman AC, Carruthers MN, Chari ST, Cheuk W, Cornell LD, Fernandez-Del Castillo C, Forcione DG, Hamilos DL, Kamisawa T, Kasashima S, Kawa S, Kawano M, Lauwers GY, Masaki Y, Nakanuma Y, Notohara K, Okazaki K, Ryu JK, Saeki T, Sahani DV, Smyrk TC, Stone JR, Takahira M, Webster GJ, Yamamoto M, Zamboni G, Umehara H and Stone JH. Consensus statement on the pathology of IgG4-related disease. *Mod Pathol* 2012; 25: 1181-1192.

IgG4-related sino-orbital disease

- [5] Vaglio A and Zwerina J. IgG4-related disease. N Engl J Med 2012; 366: 1646; author reply 1646-1647.
- [6] Lang D, Zwerina J and Pieringer H. IgG4-related disease: current challenges and future prospects. Ther Clin Risk Manag 2016; 12: 189-199.