

## Original Article

# Expression of GRIM-19 in differentiated thyroid cancer and its clinical significance

Guohua Shen<sup>1\*</sup>, Huawei Cai<sup>1\*</sup>, Yu Ma<sup>2</sup>, Zhen Zhao<sup>1</sup>

Departments of <sup>1</sup>Nuclear Medicine, <sup>2</sup>Thyroid and Breast Surgery, West China Hospital of Sichuan University, Chengdu, Sichuan, P. R. China. \*Equal contributors.

Received September 18, 2016; Accepted September 27, 2016; Epub November 1, 2016; Published November 15, 2016

**Abstract:** We aim to detect the location and expression levels of retinoic-interferon-induced mortality 19 (GRIM-19) in differentiated thyroid cancer (DTC) tissues and adjacent normal thyroid tissues and evaluate the correlation between the expression level of GRIM-19 and clinicopathologic characteristics. Herein, GRIM-19 expression was measured immunohistochemically in 48 DTC samples and corresponding non-tumorous tissues, and proteins extracted from 18 thyroid cancer samples and corresponding normal tissues were subjected to western blot analysis. Expression of GRIM-19 in tumor tissues was significantly lower than in normal tissues ( $P < 0.05$ ). Similar results were obtained by western blot analysis. The expression level of GRIM-19 in tumor tissues was significantly associated with the DTC staging ( $P < 0.05$ ), lymph node metastasis ( $P < 0.05$ ), and risk assessment ( $P < 0.05$ ). Furthermore, the BRAF<sup>V600E</sup> mutation expression levels in GRIM-19 positive patients were significantly lower than those of GRIM-19 negative patients ( $P < 0.05$ ). Taken together, GRIM-19 expression is suppressed in thyroid cancer, which might be correlated with the invasiveness and metastasis of thyroid cancer.

**Keywords:** Thyroid cancer, GRIM-19, immunohistochemistry, western blot

## Introduction

Thyroid cancer, although a rare disease, is one of the most common endocrine malignancies as well as head and neck cancers. Over the last decade, the number of thyroid cancer cases has been increasing worldwide, with an average annual increase of 4.5% [1, 2]. To wholly account for the sharp incidence trends, a number of factors have been cited, including, most prominently, the improvement and enhancement of diagnostic practices as well as increased environmental or hormonal exposures [3, 4].

Differentiated thyroid cancer (DTC), accounting for the vast majority (>90%) of all thyroid cancers, mainly includes papillary and follicular cancer [5]. After near-total or total thyroidectomy and/or radioactive iodine remnant ablation, most of the DTC patients had improvement in overall survival and quality of life [6]. However, anaplastic thyroid carcinoma and poorly differentiated thyroid carcinoma, as a small subset of thyroid tumors, are associated with poor

prognosis, accounting for a significant portion of the morbidity and mortality related to thyroid cancer [7]. With the development of molecular medicine, new treatment options such as immunotherapy and gene therapy provide huge potential to prolong survival time for these patients. However, as thyroid cancer is a multi-stage, multi-molecular disease with accumulated abnormalities, the underlying genetic mechanisms are not completely understood. Therefore, the study of the molecular and genetic mechanisms of thyroid cancer is warranted.

Retinoic-interferon-induced mortality 19 (GRIM-19) is a typical member of the GRIM apoptosis-related gene family, which represents a novel type of tumor suppressors that could potentially serve as candidates for biological markers and new targets for drug development [8]. The GRIM-19 proteins with 144 amino acid residues are expressed both in normal and in tumor tissues. GRIM-19 over-expression, or ectopic expression, significantly induces cell apoptosis. In addition, a moderate level of GRIM-19 sensitizes cells to IFN- $\beta$ /RA-induced apoptosis [8].

## GRIM-19 and differentiated thyroid cancer

As a potential tumor suppressor, GRIM-19 expression has been reported to decrease in tumors of the lung, prostate, kidney, and breast [9, 12]. Furthermore, the suppressive function of GRIM-19 was recently evaluated in thyroid cancer cells and Hurthle cell thyroid carcinomas [13, 14]. However, the role of GRIM-19 in differentiated thyroid cancer (DTC) is still unknown; thus, in this study we aimed (1) to detect the location and expression levels of GRIM-19 in thyroid cancer tissue and adjacent normal thyroid tissues; and (2) to evaluate the associations of GRIM-19 expression with clinicopathologic characteristics and serum features.

### Materials and methods

#### *Patient and tissue samples*

The preoperative serum samples were obtained from 48 thyroid cancer patients (40 females and 8 males) at the West China Hospital of Sichuan University between April 2012 and May 2013. Thyroid cancer samples were obtained from the same 48 patients who underwent surgical resection of thyroid cancer. At the same time, the matched non-tumorous tissues (normal tissues adjacent to malignant lesions) were also obtained. After resection, all tissues samples were divided into two parts, with one fixed with 4% formaldehyde and the other stored at -80°C for further analysis. In addition, all tissue specimens were confirmed by pathological examination, and none of the cases had received any anti-tumor therapy, radiotherapy, or chemotherapy before surgery.

Tumor stages and grades were classified according to the AJCC (American Joint Committee on Cancer) and UICC (Union for International Cancer Control) Cancer Staging Manual for DTC. The risk assessment was obtained based on the ATA management guidelines. The median age of the patients was 42 years (ranging from 18 to 78 years). Other histopathological characteristics were independently evaluated by two pathologists who were blinded to the other clinical data of patients.

All patients included in this study signed a written informed consent document approved by the ethics committee of the hospital before they underwent surgery. The study was approved by the Ethics Committee of the West China Hospital of Sichuan University.

#### *Immunohistochemical analysis and evaluation method*

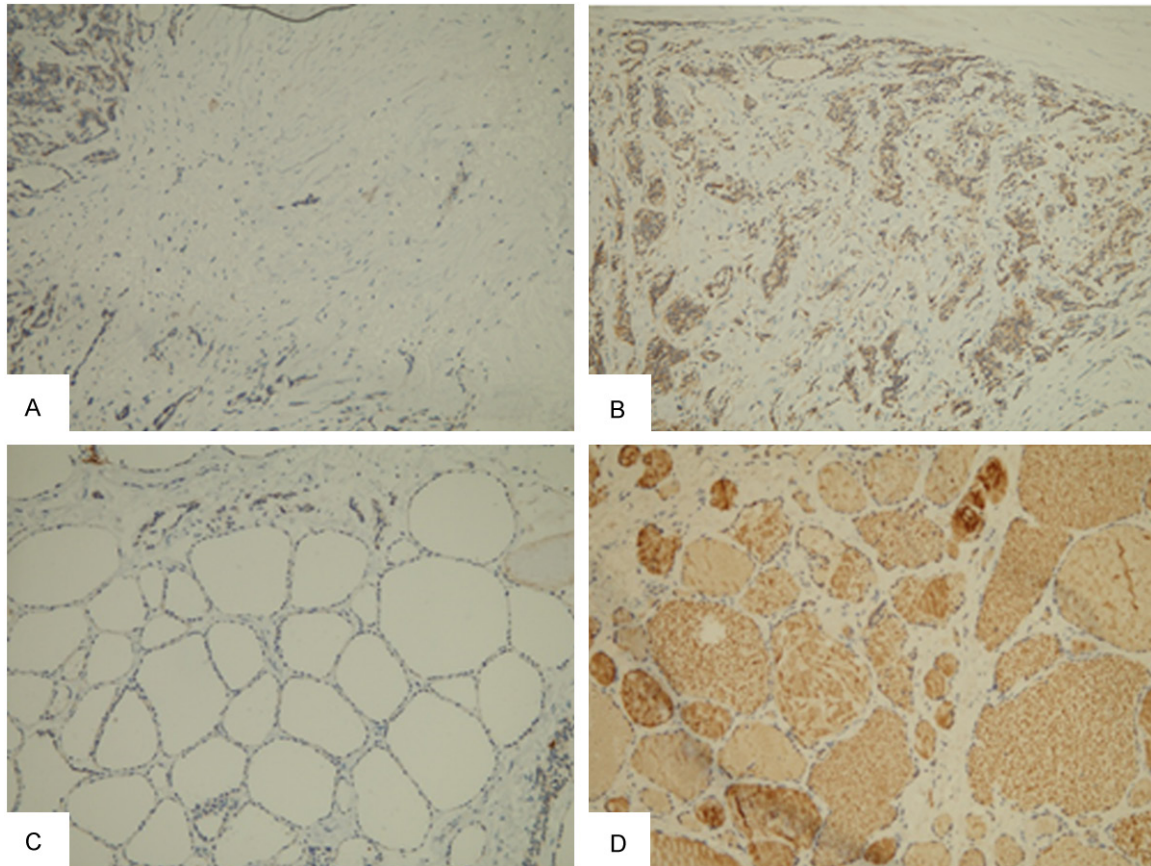
Immunohistochemistry (IHC) was performed as previously described [15]. The specimens were fixed in 4% formaldehyde, dehydrated, embedded, and cut into 3 µm serial sections. Endogenous peroxidase activity was blocked by 3% hydrogen peroxide in methanol for 30 min. After being washed twice with phosphate buffer solution (PBS), the sections were incubated with the primary antibody, rabbit anti-human GRIM-19 antibody (ABclonal, Boston, USA) overnight at 4°C. The following day, the sections were washed three times in PBS and incubated with the corresponding secondary antibody (ABclonal, Boston, USA) for 30 min at 37°C, followed by application of diaminobenzidine chromogen for 5 min and then dehydration, xylene clearing, and gum mounting. Finally, the immunohistochemical sections were analyzed using a microscope with a digital camera.

IHC staining was evaluated independently by 2 pathologists who were blinded to the clinical information. The staining scores were obtained by consensus. As previously stated, the score was determined by staining intensity and the proportion of stained cells [9]. The former was scored as the average intensity of staining in positive cells (0, none; 1, weak; 2, intermediate; and 3, strong), and the latter, representing the percentage of cells positively stained in each section, was categorized as follows: 0, ≤10%; 1, 11-25%; 2, 26-50%; and 3, >50%. If the total score obtained by adding both scores was higher than 2, the GRIM-19 expression was considered positive; otherwise expression was considered negative.

#### *Western blot analysis*

The tissue samples were lysed using RIPA buffer (50 mM Tris, pH 7.5; 150 mM NaCl; 0.5% sodium deoxycholate; 1% Triton X-100; and 0.1% sodium dodecyl sulfate), and the protein concentrations were measured by the BCA Protein Assay Kit (CWBI, Beijing, China). For each sample, an equal amount of protein (50 mg) was separated by 15% SDS-PAGE and then transferred onto PVDF membranes (Immobilon-P; Millipore). After being blocked with 5% nonfat milk in TBST (100 mM Tris base, 150 mM NaCl, and 0.05% Tween-20) for 1 h at room temperature, the membranes were incubated

## GRIM-19 and differentiated thyroid cancer



**Figure 1.** IHC analysis of GRIM-19 expression (original magnification,  $\times 200$ ). The expression of GRIM-19 in tumor tissues (A: score 2; B: score 6) and adjacent normal tissues (C: score 2; D: score 9).

overnight at  $4^{\circ}\text{C}$  with rabbit anti-human GRIM-19 polyclonal antibody (ABclonal, Boston, USA) and  $\beta$ -actin monoclonal antibody (ABclonal, Boston, USA) as a control. Then, the membrane was washed 5 times with TBST for 5 min each and incubated for 1 h in TBST with HRP-conjugated secondary antibody (ABclonal, Boston, USA), followed by washing for 5 times with TBST for 5 min each. Protein bands were visualized by enhanced chemiluminescence using the ECL Western blotting detection reagents (CW BIO, Beijing, China).

### DNA extraction and BRAF analysis

Genomic DNA was isolated from formalin-fixed paraffin-embedded tissue samples using the Qiagen TIANamp genomic DNA kit (Qiagen), according to the manufacturer's instructions. The quantity of the extracted DNA was measured with a NanoDrop ND-1000 Spectrophotometer. The BRAF<sup>V600E</sup> mutation primers were designed based on the BRAF sequence, with 5'-TGCTTGCTCTGATAGGAAAATG-3' for the forward primer, and 5'-AGCCTCAATTCTTACC-11783

ATCCA-3' for the reverse primer. The thermal cycling protocol for the polymerase chain reaction (PCR) involved an initial denaturation step at  $95^{\circ}\text{C}$  for 5 min, followed by 30 cycles of ( $95^{\circ}\text{C}$  for 30 sec,  $60^{\circ}\text{C}$  for 30 sec, and  $72^{\circ}\text{C}$  for 30 sec), and finally  $72^{\circ}\text{C}$  for 5 min. The PCR products (191 bp) were subjected to automatic sequencing using an ABI PRISM 3500 (Applied Biosystems). All mutated cases were confirmed twice with independent PCR assays.

### Statistical analysis

SPSS version 11.0 software was used for all statistical analyses. All data were expressed as the mean  $\pm$  SD. Frequency tables were analyzed using the  $\chi^2$  test, and the t-test was used to analyze differences between the 2 groups. A value of  $P < 0.05$  was considered significant.

## Results

### Clinicopathologic features

Among the 48 thyroid cancer cases, 13 patients were categorized as stage I, 17 as stage II, 12  
Int J Clin Exp Pathol 2016;9(11):11781-11787

## GRIM-19 and differentiated thyroid cancer

**Table 1.** Correlation between GRIM-19 expression and clinicopathologic features in differentiated thyroid carcinoma

Characteristics	n	GRIM-19			$\chi^2$	P
		Negative	Positive	Positive rate		
Age						
Male	8	4	4	50.0%	0.067	0.796
Female	40	18	22	55.0%		
Age						
<45	28	12	16	57.1%	0.24	0.624
≥45	20	10	10	50%		
Histological type						
Papillary	44	20	24	54.5%	0.031	0.861
Follicular	4	2	2	50.0%		
DTC stages						
I+II	30	10	20	66.7%	5.035	<0.05
III+IV	18	12	6	33.3%		
Risk assessment						
Low + Intermediate	32	9	23	68.7%	12.126	<0.01
High	16	13	3	18.8%		
Capsular invasion						
Yes	34	16	18	52.9%	0.071	0.791
No	14	6	8	57.1%		
Lymph node metastasis						
Yes	19	13	6	31.6%	6.463	0.012
No	29	9	20	69.0%		

**Table 2.** Correlation between GRIM-19 expression and BRAF<sup>V600E</sup> mutation in papillary differentiated thyroid carcinoma (n=44)

GRIM-19	n	BRAF <sup>V600E</sup> Mutation*
Negative	20	9/20
Positive	24	2/24

\*P<0.05.

as stage III, and 6 as stage IV. For the risk assessment, 16 patients were categorized as high risk, 12 patients were intermediate risk, and 20 patients were low risk. In addition, 30 patients had metastatic lymph nodes and 34 patients had capsular invasion.

As shown in IHC, GRIM-19 expression in normal thyroid tissues was positive in 43 patients (89.6%); while in tumor tissue, positive expression was detected in 26 patients (54.1%) (**Figure 1**). The absence of GRIM-19 expression was observed more frequently in cancers than in matched non-tumorous tissues (P<0.05).

### Associations of GRIM-19 expression with clinicopathologic features

We further investigated whether gender, age, histological type, stage, risk assessment, capsular invasion, or lymph nodal metastasis were associated with the expression of GRIM-19 (as shown in **Table 1**). We found that the expression level of GRIM-19 in DTC stages I-II was significantly higher than that of stages III-IV (66.7% vs. 33.3%; P<0.05). In addition, DTC patients with lymph node metastases showed a lower positive rate of GRIM-19 expression compared to those without nodal metastases (31.6% vs. 69.0%, P=0.012). The absence of GRIM-19 expression was significantly more frequent in patients with high risk features compared to those with low or intermediate risk (18.8% vs. 68.7%, P<0.01). There was no significant difference between groups based on other clinicopathologic features.

There was no significant difference between groups based on other clinicopathologic features.

### Associations of GRIM-19 expression with the BRAF<sup>V600E</sup> mutation

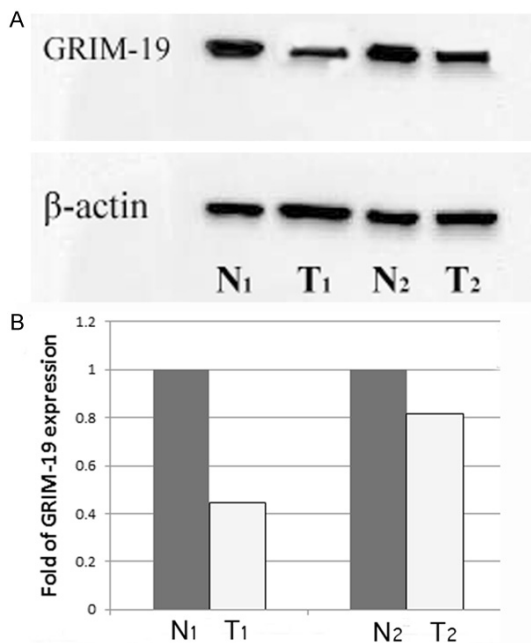
We further investigated whether the BRAF<sup>V600E</sup> mutation was associated with the expression of GRIM-19 in papillary thyroid cancer. The results are shown in **Table 2**. We found that the BRAF<sup>V600E</sup> mutation expression levels in GRIM-19 positive patients were significantly lower than those of GRIM-19 negative patients (P<0.05).

### GRIM-19 expression in thyroid cancer

Proteins extracted from 18 thyroid cancer samples and the corresponding normal tissues were subjected to Western blot analysis. Representative results are shown in **Figure 2**.



## GRIM-19 and differentiated thyroid cancer



**Figure 2.** Representative results of Western blot analysis. A. Expression of GRIM-19 in thyroid carcinoma (T) and corresponding nontumorous tissues (N).  $\beta$ -actin demonstrates the same amount of protein in the gel. B. Relative intensity of each reactive GRIM-19 band normalized to  $\beta$ -actin, used as a loading control.

We found that the GRIM-19 expression level of tumor tissues was lower than that of normal tissues, which was in agreement with the IHC studies.

### Discussion

As a novel cell death-regulatory gene induced by a combination of interferon- $\beta$  and retinoic acid [16], the role of GRIM-19 in tumor tissues has been extensively evaluated. Fan et al. found that GRIM-19 expression in lung cancer is significantly lower compared to its expression during lung inflammation. Similarly, GRIM-19 expression is reported to be lost or severely reduced in breast cancer [9], renal cell carcinoma [11, 17], cervical cancers [18], and hepatocellular carcinoma (HCC) [15]. In the present study, the results based on IHC and Western blot analysis show that the level of GRIM-19 expression in DTC tumor tissues is significantly lower than in normal tissues, which is in concordance with previous studies. Furthermore, GRIM-19 might play an important role in suppressing oncogenesis of DTC, and it is necessary to further explore its relevant mechanisms in thyroid cancer, such as the relationship

between the expression of STAT3 and that of GRIM-19, the inhibition of v-Src-induced oncogenic transformation, and metastatic behavior [19, 20].

We also found that DTC patients with high stages, high risk, and lymph node metastases had lower GRIM-19 expression than those with low stages, low or intermediate risk, and non-nodal metastases -- indicating a significant correlation between down-regulation of GRIM-19 and aggressive clinicopathologic features of DTC. Our results are in good agreement with the previous reports. For example, the study of Zhou et al. showed that down-regulation of GRIM-19 correlated with aggressive features of breast cancer, such as lymph node metastases, and thus, an advanced TNM stage [9]. In addition, GRIM-19 expression also exhibited a relationship with the clinical stage of lung cancer [10] and with histological grading in HCC [15]. Moreover, the overexpression or up-regulation of GRIM-19 has been demonstrated to suppress tumor growth, invasion, and metastasis both in vitro and in vivo [21, 22]. Taken together, these findings indicate that GRIM-19 might play a role in DTC development and will likely contribute to the future development of GRIM-19-based gene therapy approaches.

B-type Raf kinase (BRAF), as the most common genetic alteration in thyroid cancer, is a key component in cell proliferation, differentiation, and apoptosis [23]. BRAF plays an important role in the mitogen-activated protein kinase (MAPK) pathway, which is related to the initiation and progression of thyroid cancer [24]. It was reported that the BRAF<sup>V600E</sup> mutation is associated with thyroid cancer through up-regulation of cell division and proliferation, leading to tumor genesis [25, 26]. Furthermore, several studies confirmed that the BRAF<sup>V600E</sup> mutation is significantly associated with tumor multifocality, extra-thyroidal extension, lymph node metastasis and advanced TNM stage, vascular invasion, and, finally, recurrence/persistence, which might result in poor clinical outcomes of papillary thyroid carcinoma [27-29]. GRIM-19 participates in multiple pathways for exerting growth control and/or cell death, and GRIM-19 also significantly associates with the tumor staging, lymph node metastasis, differentiation status, and risk assessment [10, 15, 18]. Compared with patients with positive expression of GRIM-19, those with negative expression of GRIM-19 showed a much higher rate of

having the BRAF<sup>V600E</sup> mutation, which indicated that negative expression of GRIM-19, similar to the BRAF<sup>V600E</sup> mutation, might mean a poor prognosis. However, both the correlation of GRIM-19 with BRAF<sup>V600E</sup> and the prognostic value of GRIM-19 need further research.

Several potential weaknesses of the current study are presented as follows: first, we only analyzed the expression of GRIM-19 in DTC tumor tissues and the corresponding normal tissues, without further exploring the relevant proteins STAT3 or p-STAT3, which might lead to a non-comprehensive understanding of the role of GRIM-19 in DTC development; and second, the sample size of our study is relatively small, which might present potential limitations with respect to the interpretation of our results.

In conclusion, our findings suggest that the GRIM-19 expression level was significantly lower in thyroid cancer tissues compared to that in non-tumorous tissues, and a significant correlation was revealed between the expression level in tumor tissues and the clinicopathologic features. However, the mechanism of GRIM-19 and its relevant proteins in DTC development needs to be further evaluated.

### Acknowledgements

This work was supported by the National Natural Science Foundation of China (Grant Nos. 81201118 and 81301250).

### Disclosure of conflict of interest

None.

**Address correspondence to:** Dr. Zhen Zhao, Department of Nuclear Medicine, West China Hospital of Sichuan University, 37 Guoxue Alley, Chengdu 610041, China. Tel: +86-13408418720; Fax: +86-28-85422155; E-mail: zhaozhen1982@126.com

### References

- [1] Siegel RL, Miller KD, Jemal A. Cancer statistics, 2015. *CA Cancer J Clin* 2015; 65: 5-29.
- [2] Morris LG, Sikora AG, Tosteson TD, Davies L. The increasing incidence of thyroid cancer: the influence of access to care. *Thyroid* 2013; 23: 885-891.
- [3] Reitzel LR, Nguyen N, Li N, Xu L, Regan SD, Sturgis EM. Trends in thyroid cancer incidence in Texas from 1995 to 2008 by socioeconomic status and race/ethnicity. *Thyroid* 2014; 24: 556-567.
- [4] Li N, Du XL, Reitzel LR, Xu L, Sturgis EM. Impact of enhanced detection on the increase in thyroid cancer incidence in the United States: review of incidence trends by socioeconomic status within the surveillance, epidemiology, and end results registry, 1980-2008. *Thyroid* 2013; 23: 103-110.
- [5] Sherman SI. Thyroid carcinoma. *Lancet* 2003; 361: 501-511.
- [6] Haugen BR, Alexander EK, Bible KC, Doherty G, Mandel SJ, Nikiforov YE, Pacini F, Randolph G, Sawka A, Schlumberger M, Schuff KG, Sherman SI, Sosa JA, Steward D, Tuttle RM, Wartofsky L. 2015 American Thyroid Association Management Guidelines for Adult Patients with Thyroid Nodules and Differentiated Thyroid Cancer. *Thyroid* 2016; 26: 1-133.
- [7] Patel KN, Shaha AR. Poorly differentiated and anaplastic thyroid cancer. *Cancer Control* 2006; 13: 119-128.
- [8] Angell JE, Lindner DJ, Shapiro PS, Hofmann ER, Kalvakolanu DV. Identification of GRIM-19, a novel cell death-regulatory gene induced by the interferon-beta and retinoic acid combination, using a genetic approach. *J Biol Chem* 2000; 275: 33416-33426.
- [9] Zhou T, Chao L, Rong G, Wang C, Ma R, Wang X. Down-regulation of GRIM-19 is associated with STAT3 overexpression in breast carcinomas. *Hum Pathol* 2013; 44: 1773-1779.
- [10] Fan XY, Jiang ZF, Cai L, Liu RY. Expression and clinical significance of GRIM-19 in lung cancer. *Med Oncol* 2012; 29: 3183-3189.
- [11] He X, Cao X. Identification of alternatively spliced GRIM-19 mRNA in kidney cancer tissues. *J Hum Genet* 2010; 55: 507-511.
- [12] Liu YB, Shen WG, Ge H, Gai XD, Lu LL, Zhao XJ. Expressions of survivin and GRIM-19 in prostate cancer. *Natl J Androl* 2011; 17: 21-26.
- [13] Maximo V, Botelho T, Capela J, Soares P, Lima J, Taveira A, Amaro T, Barbosa AP, Preto A, Harach HR, Williams D, Sobrinho-Simoes M. Somatic and germline mutation in GRIM-19, a dual function gene involved in mitochondrial metabolism and cell death, is linked to mitochondrion-rich (Hurthle cell) tumours of the thyroid. *Br J Cancer* 2005; 92: 1892-1898.
- [14] Wang GM, Ren ZX, Wang PS, Su C, Zhang WX, Liu ZG, Zhang L, Zhao XJ, Chen G. Plasmid-based Stat3-specific siRNA and GRIM-19 inhibit the growth of thyroid cancer cells in vitro and in vivo. *Oncol Rep* 2014; 32: 573-580.
- [15] Li F, Ren W, Zhao Y, Fu Z, Ji Y, Zhu Y, Qin C. Downregulation of GRIM-19 is associated with hyperactivation of p-STAT3 in hepatocellular carcinoma. *Med Oncol* 2012; 29: 3046-3054.
- [16] Huang G, Lu H, Hao A, Ng DC, Ponniah S, Guo K, Lufei C, Zeng Q, Cao X. GRIM-19, a cell

## GRIM-19 and differentiated thyroid cancer

- death regulatory protein, is essential for assembly and function of mitochondrial complex I. *Mol Cell Biol* 2004; 24: 8447-8456.
- [17] Alchanati I, Nallar SC, Sun P, Gao L, Hu J, Stein A, Yakirevich E, Konforty D, Alroy I, Zhao X, Reddy SP, Resnick MB, Kalvakolanu DV. A proteomic analysis reveals the loss of expression of the cell death regulatory gene GRIM-19 in human renal cell carcinomas. *Oncogene* 2006; 25: 7138-7147.
- [18] Zhou Y, Li M, Wei Y, Feng D, Peng C, Weng H, Ma Y, Bao L, Nallar S, Kalakonda S, Xiao W, Kalvakolanu DV, Ling B. Down-regulation of GRIM-19 expression is associated with hyperactivation of STAT3-induced gene expression and tumor growth in human cervical cancers. *J Interferon Cytokine Res* 2009; 29: 695-703.
- [19] Moreira S, Correia M, Soares P, Maximo V. GRIM-19 function in cancer development. *Mitochondrion* 2011; 11: 693-699.
- [20] Kalakonda S, Nallar SC, Gong P, Lindner DJ, Goldblum SE, Reddy SP, Kalvakolanu DV. Tumor suppressive protein gene associated with retinoid-interferon-induced mortality (GRIM)-19 inhibits src-induced oncogenic transformation at multiple levels. *Am J Pathol* 2007; 171: 1352-1368.
- [21] Wang T, Yan XB, Zhao JJ, Ye J, Jiang ZF, Wu DR, Xiao WH, Liu RY. Gene associated with retinoid-interferon-induced mortality-19 suppresses growth of lung adenocarcinoma tumor in vitro and in vivo. *Lung Cancer* 2011; 72: 287-293.
- [22] Huang Y, Yang M, Yang H, Zeng Z. Upregulation of the GRIM-19 gene suppresses invasion and metastasis of human gastric cancer SGC-7901 cell line. *Exp Cell Res* 2010; 316: 2061-2070.
- [23] Kim SW, Lee JI, Kim JW, Ki CS, Oh YL, Choi YL, Shin JH, Kim HK, Jang HW, Chung JH. BRAF<sup>V600E</sup> mutation analysis in fine-needle aspiration cytology specimens for evaluation of thyroid nodule: a large series in a BRAF<sup>V600E</sup>-prevalent population. *J Clin Endocrinol Metab* 2010; 95: 3693-3700.
- [24] Zou M, Baitei EY, Alzahrani AS, BinHumaid FS, Alkhafaji D, Al-Rijjal RA, Meyer BF, Shi Y. Concomitant RAS, RET/PTC, or BRAF mutations in advanced stage of papillary thyroid carcinoma. *Thyroid* 2014; 24: 1256-1266.
- [25] Peyssonnaud C, Eychene A. The Raf/MEK/ERK pathway: new concepts of activation. *Biol Cell* 2001; 93: 53-62.
- [26] Hilger RA, Scheulen ME, Strumberg D. The Ras-Raf-MEK-ERK pathway in the treatment of cancer. *Onkologie* 2002; 25: 511-518.
- [27] Li F, Chen G, Sheng C, Gusdon AM, Huang Y, Lv Z, Xu H, Xing M, Qu S. BRAF<sup>V600E</sup> mutation in papillary thyroid microcarcinoma: a meta-analysis. *Endocr Relat Cancer* 2015; 22: 159-168.
- [28] Zhang Q, Liu SZ, Zhang Q, Guan YX, Chen QJ, Zhu QY. Meta-Analyses of Association Between BRAF<sup>V600E</sup> Mutation and Clinicopathological Features of Papillary Thyroid Carcinoma. *Cell Physiol Biochem* 2016; 38: 763-776.
- [29] Nikiforova MN, Kimura ET, Gandhi M, Biddinger PW, Knauf JA, Basolo F, Zhu Z, Giannini R, Salvatore G, Fusco A, Santoro M, Fagin JA, Nikiforov YE. BRAF mutations in thyroid tumors are restricted to papillary carcinomas and anaplastic or poorly differentiated carcinomas arising from papillary carcinomas. *J Clin Endocrinol Metab* 2003; 88: 5399-5404.