

Original Article

The role of IL-11 and IL-11Ra in angiogenesis of breast cancer

Mengyao Cui¹, Qingfu Zhang², Xueshan Qiu², Feng Jin¹

Departments of ¹Breast Surgery, ²Pathology, The First Affiliated Hospital of China Medical University, Shenyang, People's Republic of China

Received September 23, 2016; Accepted September 29, 2016; Epub November 1, 2016; Published November 15, 2016

Abstract: Interleukin (IL)-11 is a member of the IL-6 family of cytokines. Recently, IL-11 signaling has been shown to play a crucial role in gastrointestinal carcinoma. However, the role of IL-11 in breast cancer progression is unclear. The aim of this study was to investigate the clinicopathological significance of IL-11 and IL-11Ra in breast cancer and their relationship to angiogenesis. The clinicopathological features of 124 patients with breast cancer were analyzed. Immunohistochemistry was used to measure IL-11 and IL-11Ra expressions and microvessel density (MVD) in tumor tissues. The association of IL-11 and IL-11Ra co-expression with MVD was assessed. In this cohort, IL-11 expression was associated with low Her-2 expression (86.1%) and high Ki-67 expression levels (62.0%). ($P = 0.043, 0.038$, respectively). Meanwhile, IL-11Ra expression was associated with high ER levels (67.9%), high PR levels (60.7%), and low Her-2 expression (76.8%) ($P = 0.006, 0.004$, and 0.013 , respectively). The average MVD of the IL-11 and IL-11Ra positive group was 9.32 per field of view, and the average MVD of the negative group was 6.83 per field of view. MVD in the positive group was significantly higher than that in the negative group ($P < 0.05$). This study helped elucidate the role of IL-11 in angiogenesis of breast cancer.

Keywords: Interleukin-11, interleukin-11 receptor, immunohistochemistry, breast cancer, angiogenesis

Introduction

Breast cancer is one of the most frequently diagnosed cancers and a leading cause of cancer-related deaths among women. Angiogenesis, the formation of new blood vessels, is required for tumor growth, progression, and aggressiveness [1, 2]. The vascular network is essential for cancer cell to gain nutrients for growth and to eliminate metabolic products. Especially when some tumors' size is in millimeter range, stimulation of new blood vessels-also known as angiogenesis- is necessary [3]. Numerous studies have reported a correlation between increased angiogenesis and poor prognosis in various cancers [3]. Thus, inhibiting angiogenesis is a promising strategy for cancer treatment.

Interleukin (IL)-11 is one of the IL-6 family, which includes nine cytokines [4] IL-11 interacts with a specific non-catalytic transmembrane receptor. More recently, both IL-11 and IL-6 have been linked to the development of

epithelial cancers [5, 6]. The IL-6 family is defined by their shared use of glycoprotein-130 beta-subunit (GP130, also known as CD130 or IL6ST) which is a transmembrane protein [7]. Recent reports have suggested a complex multifarious role for IL-11 in various cancers, including breast cancer. Several studies have shown that under hypoxic conditions the tumorigenicity of PC-3 prostate cancer cells have been enhanced by IL-11, which suggests that IL-11 may promote angiogenesis [8]. This study assessed the clinicopathological significance of IL-11 and its receptor IL-11Ra in breast cancer and their relationship to angiogenesis.

Materials and methods

Patients and ethics statement

The patients in the present study had histologically confirmed breast cancer and underwent operations at the Department of Breast Surgery of the First Hospital of China Medical University in 2015. A total of 124 formalin-fixed, paraffin-

Pathology of the angiogenesis of breast cancer

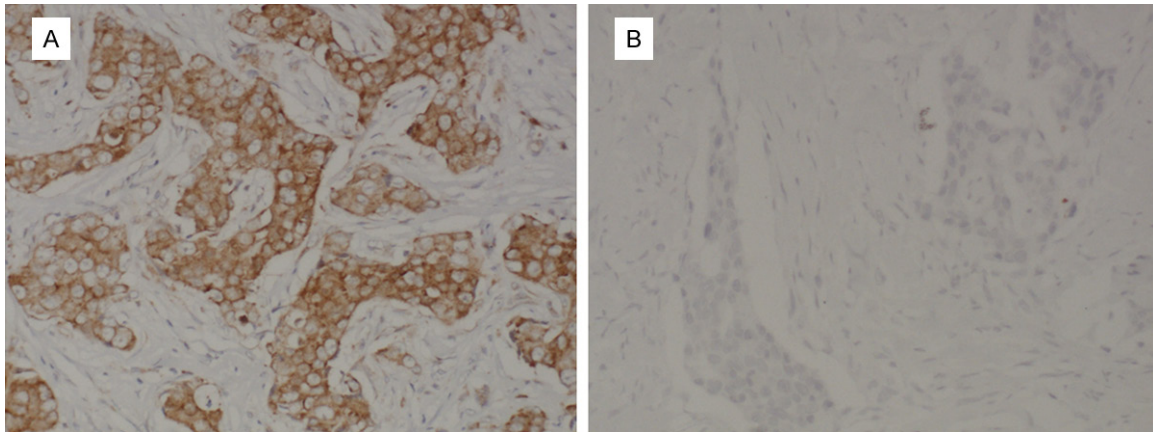


Figure 1. Representative IHC staining of IL-11 expression in clinical specimens. A. Positive expression of IL-11; B. Negative expression of IL-11. Representative images are shown at $\times 400$ magnification.

embedded primary tumor tissues were available for this study. None of the patients received preoperative radiotherapy, chemotherapy or immunotherapy. The clinical data, including age, tumor features, histological classification, TNM stage, and lymph node metastasis, were recorded.

The Human Research Ethical Committee of the China Medical University Affiliated Stomatological Hospital approved the use of these tissue samples for the study. All patients included in the study agreed that their tumor samples could be used during their initial diagnosis, and written consent was obtained from all participants.

Immunohistochemistry (IHC)

The specimens were fixed in 10% formalin solution and then embedded in paraffin. Serial sections were cut and prepared for hematoxylin and eosin (H&E) staining and IHC. The sections were incubated with a rabbit polyclonal IL-11 antibody (1:100 dilution, Novus, USA), a rabbit monoclonal IL-11Ra antibody (1:1000 dilution, Abcam, USA) or a mouse monoclonal CD31 antibody (1:100 dilution, Cell Signaling, USA) overnight at 4°C, followed by incubation at 37°C for 30 min with a secondary antibody against rabbit and mouse immunoglobulins (Maixin Co., Fuzhou, China). Then, the sections were stained with DAB for 5 min. Positive staining of the cytoplasm and cell membrane was yellow-brown. The number of IL-11-positive or IL-11Ra-positive cells was counted in 10 ran-

dom optic fields using a light microscope equipped with a 50 \times objective. Small blood vessels were visualized by CD31 staining of the endothelial cells. For determination of the MVD, the highest neovascularization areas (hot spots) were identified by scanning whole tumor sections at low power, followed by counting individual microvessels at 400 \times magnification. The highest single field value within each hot spot was recorded. Endothelial cells or endothelial cell clusters positive for CD34, CD31, or von Willebrand Factor (vWF) that were separate from the adjacent clusters were considered single countable microvessels [9].

Statistical analysis

Data were analyzed using SPSS 23.0. The association between IL-11 or IL-11Ra expression and clinicopathological features of the patients was determined using the χ^2 test. The t-test was used to compare the MVD between patients in the IL-11 and IL-11Ra double-positive group and those in the negative group. A *P*-value of <0.05 was considered statistically significant.

Results

IL-11 and IL-11Ra expression in breast cancer

Using IHC, we assessed the IL-11 and IL-11Ra protein expressions in human tumor tissues from 124 breast cancer patients. IHC examination showed that IL-11 was predominantly located in the cytoplasm of breast cancer cells (**Figure 1A**), and IL-11Ra, as a transmembrane

Pathology of the angiogenesis of breast cancer

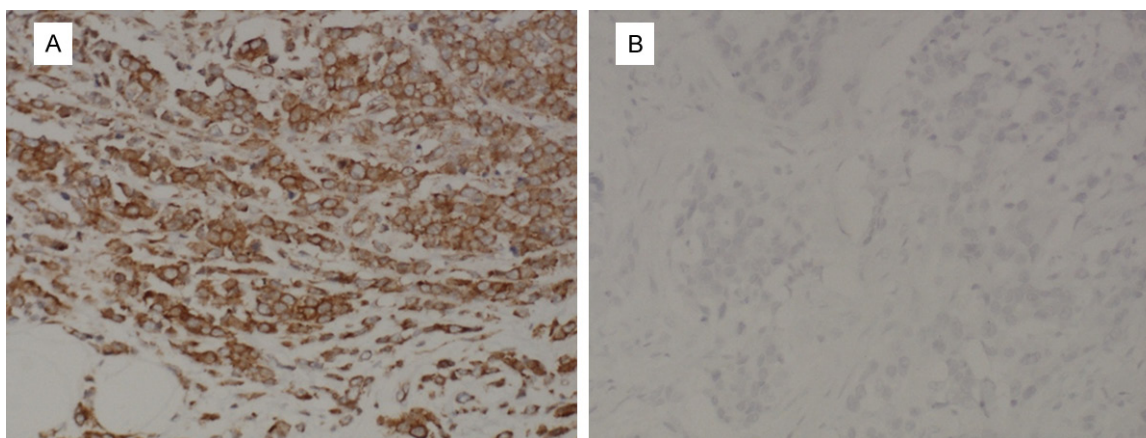


Figure 2. Representative IHC staining of IL-11Ra expression in clinical specimens. A. Positive expression of IL-11Ra; B. Negative expression of IL-11Ra. Representative images are shown at $\times 400$ magnification.

Table 1. Correlations of IL-11 and IL-11Ra expressions with MVD and clinicopathological status in samples from 124 patients with breast cancer

Clinicopathological features	Number of patients	IL-11		P value	IL-11Ra		P value
		(+) N = 79	(-) n = 45		(+) N = 56	(-) n = 68	
Age				0.285			0.213
<50	61	36 (45.6%)	25 (55.6%)		31 (55.4%)	30 (44.1%)	
≥ 50	63	43 (54.4%)	20 (44.4%)		25 (44.6%)	38 (55.9%)	
ER+	98	63 (79.7%)	35 (77.8%)	0.798	38 (67.9%)	60 (88.2%)	0.006**
-	26	16 (20.3%)	10 (22.2)		18 (39.3%)	8 (11.8%)	
PR+	91	58 (73.4%)	33 (73.3%)	0.992	34 (60.7%)	57 (83.8%)	0.004**
-	33	21 (26.6%)	12 (26.7)		22 (39.3%)	11 (16.2%)	
Her-2+	18	11 (13.9%)	7 (15.6%)	0.043*	13 (23.2%)	5 (7.4%)	0.013*
-	106	68 (86.1%)	38 (84.4%)		43 (76.8%)	63 (92.6%)	
Ki-67+	85	49 (62.0%)	36 (80.0%)	0.038*	42 (75.0%)	43 (63.2%)	0.160
-	39	30 (38.0%)	9 (20.0%)		14 (25.0%)	25 (36.8%)	
LN+	41	25 (31.6%)	16 (35.6%)	0.656	20 (35.7%)	21 (30.9%)	0.569
-	83	54 (68.4%)	29 (64.4%)		36 (64.3%)	47 (69.1%)	
Size of the tumor				0.222			0.320
<2 cm	36	22 (27.8%)	14 (31.1%)		12 (21.4%)	24 (35.3%)	
2 cm-5 cm	71	49 (62.0%)	22 (48.9%)		36 (63.3%)	35 (51.5%)	
>5 cm	17	8 (10.1%)	9 (20.0%)		8 (14.3%)	9 (13.2%)	

* $P < 0.05$, ** $P < 0.01$.

receptor, was located on the cytomembrane of breast cancer cells (**Figure 2A**).

Among 124 cases of breast cancer, 79 (63.7%) cases (**Figure 1A**) showed expression of IL-11, and negative expression of IL-11 was found in 45 (36.3%) cases (**Figure 1B**). Positive expression of IL-11Ra was found in 56 (45.2%) cases (**Figure 2A**), and negative expression of IL-11Ra was found in 68 (54.8%) cases (**Figure 2B**).

Correlation of IL-11 and IL-11Ra expression with clinicopathological features in patients with breast cancer

The clinical profiles of breast cancer patients in this study are shown in **Table 1**. Statistical analysis indicated a significant correlation between IL-11 expression and Her-2 ($P = 0.043$) or Ki-67 expression ($P = 0.038$), showing that IL-11 expression was associated with low Her-2 expres-

Pathology of the angiogenesis of breast cancer

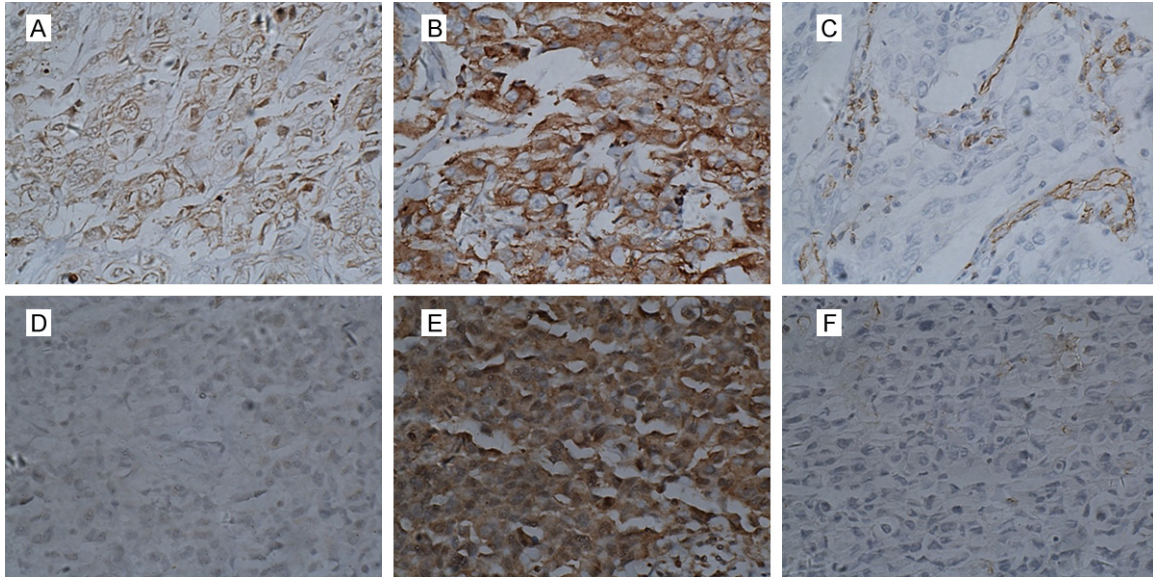


Figure 3. MVD in breast cancer tissues. A-C: Double positive case. D-F: Not double positive case. A: Positive expression of IL-11; B: Positive expression of IL-11Ra; C: The average MVD of the IL-11 and IL-11Ra positive expression group was 9.32 per field of view; D: Negative expression of IL-11; E: Negative expression of IL-11Ra; F: The average MVD of the negative expression group was 6.83 per field of view. Representative images are shown at $\times 400$ magnifications.

sion (86.1%) and high Ki-67 expression levels (62.0%). However, no significant association was observed between IL-11 expression and age, lymph node metastasis, size of the tumor, and ER or PR expression. Meanwhile, the expression of IL-11Ra was associated with ER expression ($P = 0.006$), PR expression ($P = 0.004$), and Her-2 expression ($P = 0.013$). IL-11Ra expression was associated with high ER expression levels (67.9%), high PR expression levels (60.7%), and low Her-2 expression (76.8%).

Correlation of IL-11 expression with MVD in patients with breast cancer

To investigate the correlation between IL-11 and IL-11Ra expressions and tumor angiogenesis, we performed IHC staining for IL-11 expression using anti-IL-11 antibodies, IL-11Ra expression using anti-IL-11Ra antibodies and MVD using anti-CD31 antibodies in 124 primary invasive ductal breast carcinoma samples. MVD was used as a marker of angiogenesis because it was reported to be an independent and highly significant prognostic factor [9-11].

We divided the 124 patients into two groups. The positive group expressed both IL-11 and IL-11Ra, while patients in the negative group

did not meet this standard. The average MVD of the positive group (**Figure 3A**) was 9.32 per field of view, and the average MVD of the negative group (**Figure 3B**) was 6.83 per field of view. The difference was analyzed with an independent t test. MVD in the double positive group was significantly higher than that in the negative group ($P < 0.05$).

Discussion

IL-11 is a pleiotropic cytokine that was initially described in 1990 as a bone marrow stroma-derived hematopoietic cytokine [12]. IL-11 is expressed by all kinds of tissues, such as the gut, brain, spinal cord neurons, and testes, and thus may have a physiological function in these organs [13]. Recent studies have suggested that IL-11 may participate in several unrelated aspects of cancer biology [14], including the promoting angiogenesis [15], survival under the condition of hypoxia [8], apoptosis [16] and chemoresistance [17], as well as metastasis [18]. MVD is commonly used to evaluate tumor angiogenesis [19-21]. We measured CD31 in endothelial cells to determine the MVD. Elucidating the association of IL-11 and its receptor with MVD may contribute to understanding the clinicopathological significance of IL-11 expression in breast cancer.

Pathology of the angiogenesis of breast cancer

In this study, IL-11 and IL-11Ra expressions were detected in breast cancer tissues using IHC analyses. Our results showed that IL-11 was predominantly located in the cytoplasm of breast cancer cells, and IL-11Ra, a transmembrane receptor, was located on the cytomembrane of breast cancer cells. IL-11 expression was significantly correlated with Her-2 expression and Ki-67 expression in cancer patients, and IL-11Ra expression was significantly correlated with ER expression, PR expression, and Her-2 expression. In addition, IL-11 and IL-11Ra co-expression was inversely correlated with the MVD of breast cancer tumors. These results indicate that IL-11 is involved in angiogenesis of breast cancer patients.

One limitation of our study is that only a small number of patients were examined; thus, it was difficult to assess the significance of this study. We hope to analyze a greater number of patients in the future. Further researches are required to elucidate the specific mechanisms by which IL-11 contributes to angiogenesis.

In conclusion, IL-11 is closely associated with angiogenesis. Analysis of the clinicopathological significance of IL-11 expression in breast cancer and its relationship to angiogenesis may provide a theoretical basis for antiangiogenic therapy.

Acknowledgements

This work was supported by Project of scientific technology and social development, Liaoning Province (No. 2009225008 and 201225002) and Natural Science Foundation of Liaoning of China (No. 81201886 and 81472599).

Disclosure of conflict of interest

None.

Address correspondence to: Dr. Feng Jin, Department of Breast Surgery, The First Affiliated Hospital of China Medical University, Shenyang 110001, People's Republic of China. Tel: +86-13998890665; E-mail: jinfeng66cn@hotmail.com

References

[1] Egos JM and Kerbel RS. Antiangiogenic therapy: impact on invasion, disease progression, and metastasis. *Nat Rev Clin Oncol* 2011; 8: 210-221.

- [2] Hanahan D and Weinberg RA. Hallmarks of cancer: the next generation. *Cell* 2011; 144: 646-674.
- [3] Folkman J. Tumor Angiogenesis: Therapeutic Implications. *N Engl J Med* 1971; 285: 1182-1186.
- [4] Ernst M and Putoczki TL. Molecular pathways: IL11 as a tumor-promoting cytokine-translational implications for cancers. *Clin Cancer Res* 2014; 20: 5579-5588.
- [5] Nakayama T, Yoshizaki A, Izumida S, Suehiro T, Miura S, Uemura T, Yakata Y, Shichijo K, Yamashita S and Sekin I. Expression of interleukin-11 (IL-11) and IL-11 receptor alpha in human gastric carcinoma and IL-11 upregulates the invasive activity of human gastric carcinoma cells. *Int J Oncol* 2007; 30: 825-833.
- [6] Matsuo K, Oka M, Murase K, Soda H, Isomoto H, Takeshima F, Mizuta Y, Murata I and Kohno S. Expression of interleukin 6 and its receptor in human gastric and colorectal cancers. *J Int Med Res* 2003; 31: 69-75.
- [7] Taga T. The signal transducer gp130 is shared by interleukin-6 family of haematopoietic and neurotrophic cytokines. *Ann Med* 1997; 29: 63-72.
- [8] Onnis B, Fer N, Rapisarda A, Perez VS and Melillo G. Autocrine production of IL-11 mediates tumorigenicity in hypoxic cancer cells. *J Clin Invest* 2013; 123: 1615-1629.
- [9] Uzzan B, Nicolas P, Cucherat M and Perret GY. Microvessel density as a prognostic factor in women with breast cancer: a systematic review of the literature and meta-analysis. *Cancer Res* 2004; 64: 2941-2955.
- [10] Kato T, Steers G, Campo L, Roberts H, Leek RD, Turley H, Kimura T, Kameoka S, Nishikawa T, Kobayashi M, Harris AL, Gatter KC and Pezzella F. Prognostic significance of microvessel density and other variables in Japanese and British patients with primary invasive breast cancer. *Br J Cancer* 2007; 97: 1277-1286.
- [11] Weidner N, Semple JP, Welch WR and Folkman J. Tumor angiogenesis and metastasis—correlation in invasive breast carcinoma. *N Engl J Med* 1991; 324: 1-8.
- [12] Paul SR, Bennett F, Calvetti JA, Kelleher K, Wood CR, O'Hara RM Jr, Leary AC, Sibley B, Clark SC, Williams DA, et al. Molecular cloning of a cDNA encoding interleukin 11, a stromal cell-derived lymphopoietic and hematopoietic cytokine. *Proc Natl Acad Sci U S A* 1990; 87: 7512-7516.
- [13] Du X and Williams DA. Interleukin-11: review of molecular, cell biology, and clinical use. *Blood* 1997; 89: 3897-3908.
- [14] Johnstone CN, Chand A, Putoczki TL and Ernst M. Emerging roles for IL-11 signaling in cancer development and progression: Focus on breast

Pathology of the angiogenesis of breast cancer

- cancer. *Cytokine Growth Factor Rev* 2015; 26: 489-498.
- [15] Marusyk A, Tabassum DP, Altmann PM, Almendro V, Michor F and Polyak K. Non-cell-autonomous driving of tumour growth supports sub-clonal heterogeneity. *Nature* 2014; 514: 54-58.
- [16] Putoczki TL, Thiem S, Loving A, Busuttill RA, Wilson NJ, Ziegler PK, Nguyen PM, Preaudet A, Farid R, Edwards KM, Boglev Y, Luwor RB, Jarnicki A, Horst D, Boussioutas A, Heath JK, Sieber OM, Pleines I, Kile BT, Nash A, Greten FR, McKenzie BS and Ernst M. Interleukin-11 is the dominant IL-6 family cytokine during gastrointestinal tumorigenesis and can be targeted therapeutically. *Cancer Cell* 2013; 24: 257-271.
- [17] Bockhorn J, Dalton R, Nwachukwu C, Huang S, Prat A, Yee K, Chang YF, Huo D, Wen Y, Swanson KE, Qiu T, Lu J, Park SY, Dolan ME, Perou CM, Olopade OI, Clarke MF, Greene GL and Liu H. MicroRNA-30c inhibits human breast tumour chemotherapy resistance by regulating TWF1 and IL-11. *Nat Commun* 2013; 4: 1393.
- [18] Girasole G, Passeri G, Jilka RL and Manolagas SC. Interleukin-11: a new cytokine critical for osteoclast development. *J Clin Invest* 1994; 93: 1516-1524.
- [19] Calcinotto A, Ponzoni M, Ria R, Grioni M, Cattaneo E, Villa I, Sabrina Bertilaccio MT, Chesi M, Rubinacci A, Tonon G, Bergsagel PL, Vacca A and Bellone M. Modifications of the mouse bone marrow microenvironment favor angiogenesis and correlate with disease progression from asymptomatic to symptomatic multiple myeloma. *Oncoimmunology* 2015; 4: e1008850.
- [20] Kather JN, Marx A, Reyes-Aldasoro CC, Schad LR, Zollner FG and Weis CA. Continuous representation of tumor microvessel density and detection of angiogenic hotspots in histological whole-slide images. *Oncotarget* 2015; 6: 19163-19176.
- [21] Lin L, Chen YS, Yao YD, Chen JQ, Chen JN, Huang SY, Zeng YJ, Yao HR, Zeng SH, Fu YS and Song EW. CCL18 from tumor-associated macrophages promotes angiogenesis in breast cancer. *Oncotarget* 2015; 6: 34758-34773.