

## Case Report

# Tuberculosis infection: an easily ignored factor to cause persistent fever in patients with acute myeloid leukemia

Jiejing Qian, Chunji Jin, Lei Wang, Jie Jin, Haitao Meng

Department of Hematology, The First Affiliated Hospital, College of Medicine, Zhejiang University, Zhejiang, China

Received October 4, 2015; Accepted November 22, 2015; Epub February 1, 2016; Published February 15, 2016

**Abstract:** For patients with acute myeloid leukemia (AML), fever and pneumonia are more common symptoms in early diagnosis than in period of remission. Here we reported an AML patient who suffered from persistent fever and pneumonia even with complete remission, but didn't respond to antibiotics including anti fungal agents. Since sputum or blood cultures were negative and nothing was observed by endobroncheal ultrasonography (EBUS), this persistent fever and pneumonia came to be a confusing problem. Finally, tuberculous pneumonia was ascertained by computerized tomography-guided lung biopsy.

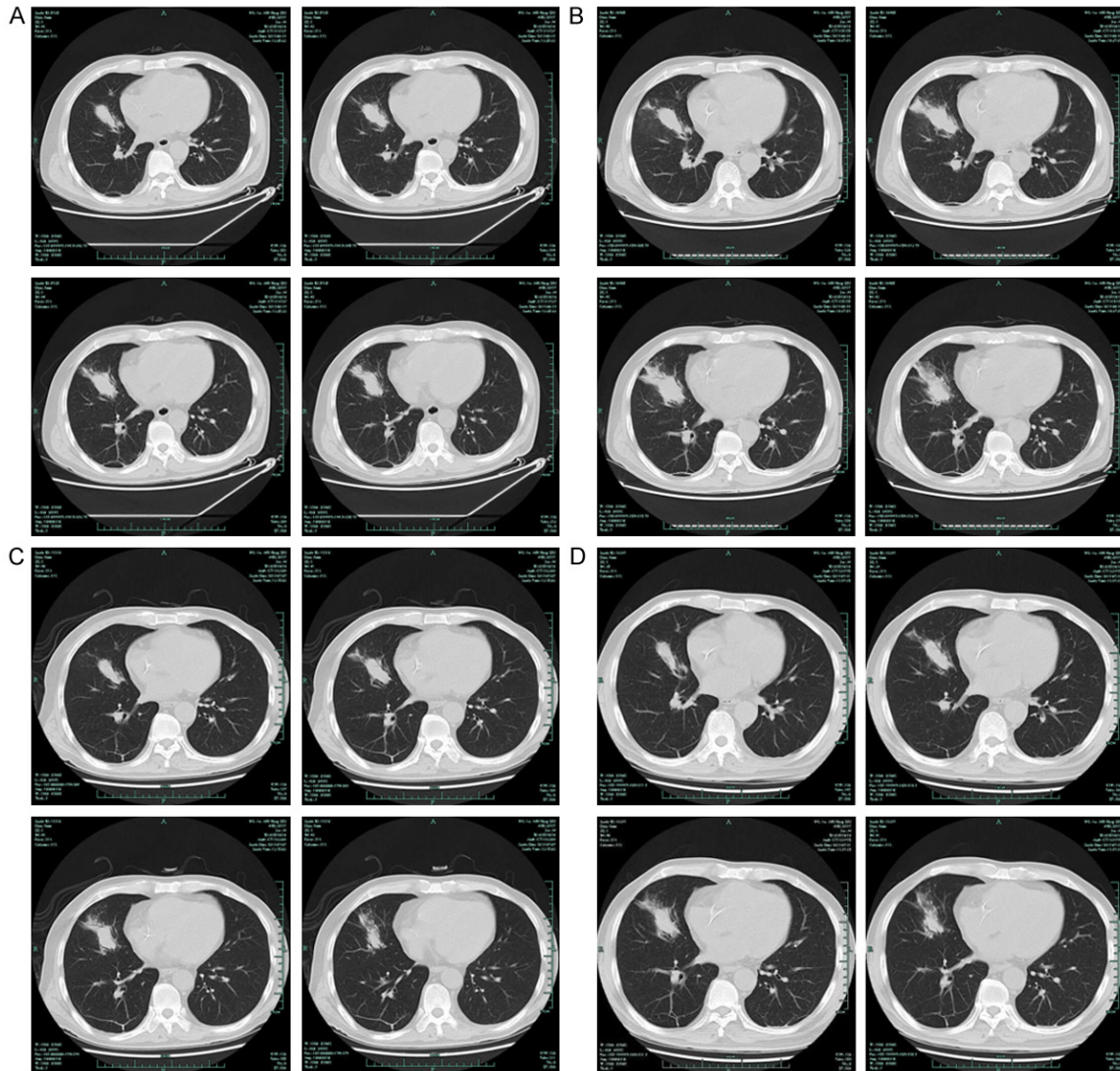
**Keywords:** Hematological disorder, tuberculosis, computerized tomography (CT)

### Introduction

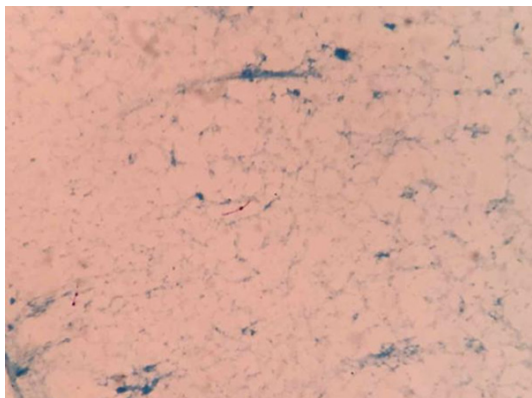
On June 9, 2015, a 52-year-old man was admitted to our department with complaints of persisted severe fatigue and fever followed by feeling of chest tightness. The patient showed high fever (above 39°C) with slight cough, but no appreciable night sweat or weight loss. CBC showed that white blood cell (WBC) was  $3.4 \times 10^9/L$  with 5% of blast cell, and hemoglobin 58 g/L, platelet count  $26 \times 10^9/L$ . CT scan revealed pneumonia in the right lung (**Figure 1A**). Furthermore, CT guided lung biopsy was not tolerable due to severe thrombocytopenia. Actually, sputum or blood cultures were performed several times but all turned to be negative. With no pathogen confirmed, the experimental administration with voriconazole and imipenem was adopted. Bone marrow aspiration revealed 30 percent of blast cells. By immunostaining, acute myeloid leukemia was diagnosed. Subsequently, the patient received one cycle of standard induction chemotherapy (IA regimen). The patient's body temperature once dropped to about 38°C during chemotherapy, and then went up to 39°C when granulocyte count was sharply decreased with *Staphylococcus epidermidis* found in blood. After drug sensitivity test, vancomycin was administered. Simultaneously, granulocyte colony stim-

ulating factor (G-CSF) was administrated as a supportive therapy and CT scan was repeated (**Figure 1B**) which showed pneumonia turned to be worse because of wider infected area. Since fever and fatigue were all complaints from this patient, we doubted whether *Staphylococcus epidermidis* is the only pathogen which caused lung infection. Based on the outcome of multidisciplinary discussions, we decided that tigecycline and cefoperazone/sulbactam were substituted for imipenem which could induce the emergence of multiple resistant bacteria. Vancomycin and voriconazole were withdrawn. Subsequently, the body temperature of the patient did return to normal, but this only lasted five days before it went up to 39°C and higher. CT scan was performed again to find a slight improvement in the condition of pneumonia (**Figure 1C**), which might be attributable to the growth of leukocyte and platelet with complete bone marrow remission. The patient had no manifestation of new symptoms except for high fever. Further examination had been therefore performed. The outcome of endobroncheal ultrasonography (EBUS) was negative. Finally, the confirmed reason for fever and pulmonary infection was found to be associated with tuberculosis (**Figure 2**) by CT guided lung biopsy. Before CT guided lung biopsy was conducted,

## An easily ignored factor to cause persistent fever in patients with AML

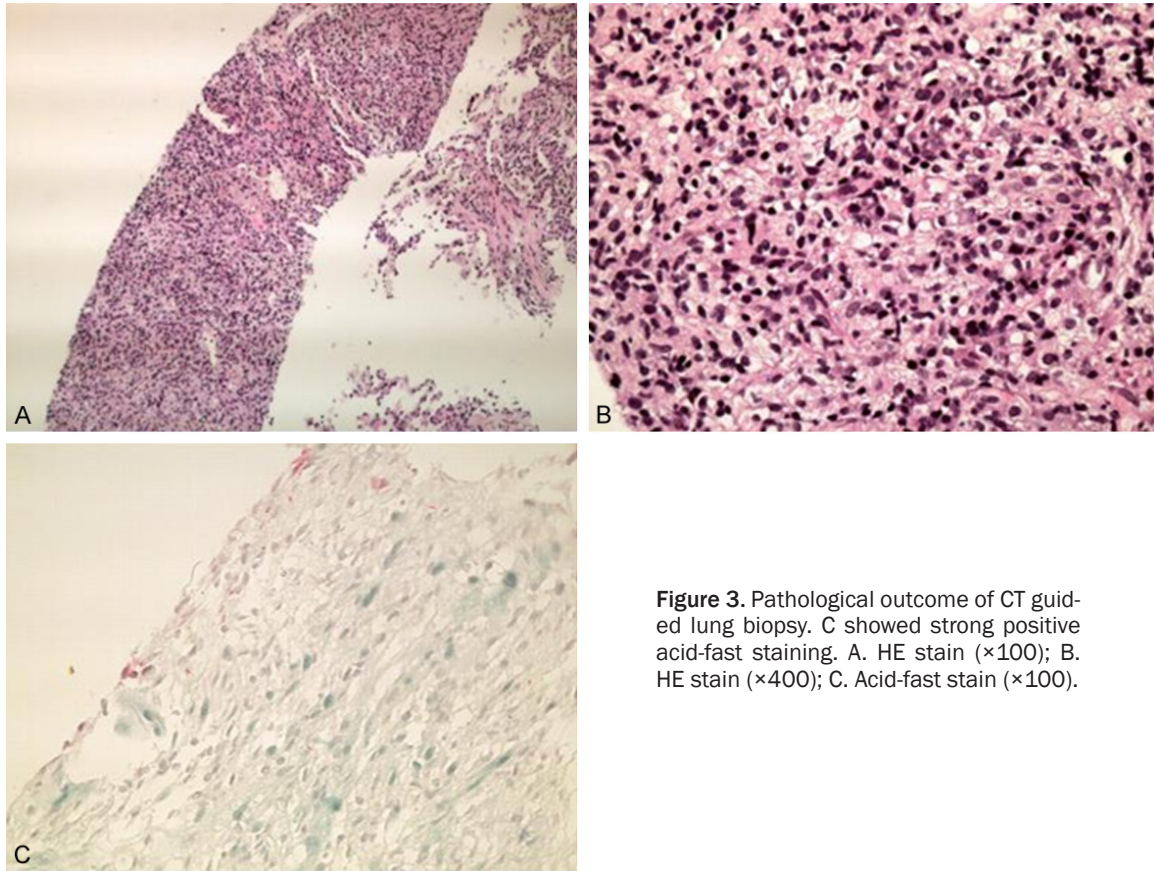


**Figure 1.** Pulmonary CT scan: high density shadow of right middle pulmonary mass, no lymph node enlargement of both hilus of lung and mediastinum.



**Figure 2.** CT guided lung biopsy: the acid-fast staining was positive.

we examined the lung CT scan again (**Figure 1D**), found that the infection was similar to that detected by CT scan in **Figure 1C**. Pathological outcome confirmed this (**Figure 3**). Unfortunately, after about 2 weeks' anti-tuberculosis therapy combined with rifapentine, isoniazid, butyl alcohol and pyrazinamide, the temperature still could not be controlled. Then we deduced that it might be a resistant type tuberculosis that worked. Later, the bronchoscopy was examined, and the Polymerase Chain Reaction (PCR) outcome confirmed that no resistance was involved in tuberculosis infection. About 3 weeks' therapy, the patient's temperature returned to normal.



**Figure 3.** Pathological outcome of CT guided lung biopsy. C showed strong positive acid-fast staining. A. HE stain ( $\times 100$ ); B. HE stain ( $\times 400$ ); C. Acid-fast stain ( $\times 100$ ).

## Discussion

Tuberculosis (TB) remains a global concern despite substantial investment in TB-related health services over the past two decades. Patients with sputum-negative pulmonary TB (PTB) and extrapulmonary TB (EPTB) are difficult to diagnose and may be missed at all points of care [1]. Atypical clinical signs and symptoms in adults with TB make the diagnosis more difficult. For patients with hematologic malignancies, the most common pathogens associated with infection due to agranulocytosis and immune inhibition were bacteria and fungus rather than mycobacterium tuberculosis. Seldom definitely diagnosed as it were, tuberculous infections (TIs) are one of severe and life-threatening complications in patients with malignant hematological disorders. TI predominantly affects males with chronic myeloproliferative disorders, myelodysplasia, and AML [2]. Chen et al. and Mishra et al. reported that patients with AML rather than other types of hematologic malignancies had a higher rate of tuberculous infections due to mycobacteri-

um tuberculosis [3, 4]. Most patients with hematological malignancies and pulmonary tuberculosis showed mediastinal lymphadenopathy, pleural effusions and fibrocalcified lesions [3]. Extrapulmonary presentation of TB disease is common in patients with hematological malignancies, ranging from 16% to 78% [4-6].

In our case, the male patient with AML and an atypical pneumonia had no chance to confirm the cause of pneumonia. The patient also had no typical symptoms except for persisted high fever in the entire treatment course. In theory, PTB is classified into primary and post-primary patterns, each showing characteristic radiological features. By radiology, primary PTB manifests as four major symptoms: parenchymal disease, lymphadenopathy, pleural effusion, and miliary disease or any combination thereof [7]. The most common radiographic manifestation of post-primary PTB is characterized by focal or patchily heterogeneous, poorly defined masses involving the apical and posterior segments of the upper lobes and the superior seg-

## An easily ignored factor to cause persistent fever in patients with AML

ments of the lower lobes [8-10]. Cavitation, the radiological hallmark of PTB is radiographically evident in 20-45% of patients. In our case, CT scan revealed high-density shadow of the right middle pulmonary mass but no lymph node enlargement of both hilus of lung and mediastinum. We have difficulty in diagnosing pulmonary tuberculosis based on these imaging. Actually, we would have preferred to consider fungus rather than tubercle bacillus as the cause of pneumonia, even if we saw the shadow of lung with cavity. Fortunately, after chemotherapy and severe bone marrow suppression, the infection showed no further progression. And the infection was diagnosed and confirmed by biopsy and bronchoscopy because the platelet count was recovered.

So what we should learn from this case is to think of the possibility of tuberculosis despite the atypical pneumonia and clinical indication and to perform enough sputum culture to find as more as tubercle bacillus. It is hard to diagnose the AML patients due to presence of severe thrombopenia. CT guided lung biopsy should be performed once the patient's conditions allow for diagnosis.

### Disclosure of conflict of interest

None.

**Address correspondence to:** Dr. Haitao Meng, Department of Hematology, The First Affiliated Hospital, College of Medicine, Zhejiang University, 79 Qing-Chun Road, Hangzhou 310003, Zhejiang Province, China. Tel: +861386502760; E-mail: menghaitao\_m@sina.com

### References

- [1] Skoura E, Zumla A, Bomanji J. Imaging in tuberculosis. *Int J Infect Dis* 2015; 32: 87-93.
- [2] Al-Anazi KA, Al-Jasser AM, Evans DA. Infections caused by mycobacterium tuberculosis in patients with hematological disorders and in recipients of hematopoietic stem cell transplant, a twelve year retrospective study. *Ann Clin Microbiol Antimicrob* 2007; 6: 16.
- [3] Chen CY, Sheng WH, Cheng A, Tsay W, Huang SY, Tang JL, Chen YC, Wang JY, Tien HF, Chang SC. Clinical characteristics and outcomes of Mycobacterium tuberculosis disease in adult patients with hematological malignancies. *BMC Infect Dis* 2011; 11: 324.
- [4] Mishra P, Kumar R, Mahapatra M, Sharma S, Dixit A, Chatterjee T, Choudhry DR, Saxena R, Choudhry VP. Tuberculosis in acute leukemia: a clinico-hematological profile. *Hematology* 2006; 11: 335-340.
- [5] Libshitz HI, Pannu HK, Elting LS, Cooksley CD. Tuberculosis in cancer patients: an update. *J Thorac Imaging* 1997; 12: 41-46.
- [6] Andreu J, Cáceres J, Pallisa E, Martinez-Rodriguez M. Radiological manifestations of pulmonary tuberculosis, *Eur J Radiol* 2004; 51: 139-149.
- [7] Khan B, Ahmed P, Ullah K, Hussain CA, Hussain I, Raza S. Frequency of tuberculosis in haematological malignancies and stem cell transplant recipients. *J Coll Physicians Surg Pak* 2005; 15: 30-33.
- [8] Jones HA, Clark RJ, Rhodes CG, Schofield JB, Krausz T, Haslett C. In vivo measurement of neutrophil activity in experimental lung inflammation. *Am J Respir Crit Care Med* 1994; 149: 1635-9.
- [9] Leung AN. Pulmonary tuberculosis: the essentials. *Radiology* 1999; 210: 307-22.
- [10] Krysl J, Korzeniewska-Kosela M, Muller NL, FitzGerald JM. Radiologic features of pulmonary tuberculosis: an assessment of 188 cases. *Can Assoc Radiol J* 1994; 45: 101-7.