

Original Article

Biomarkers for early diagnosis of aseptic loosening after total hip replacement

Faqlang Tang^{1,2}, Xiaozhou Liu^{1,3}, Hui Jiang^{1,3}, Hong Wu², Shiping Hu², Jianzhang Zheng², Huiling Guo², Laipeng Yan², Chuncai Xu², Yunshuo Lin², Jianli Lin⁴, Jianning Zhao^{1,3}

¹Southern Medical University, Guangzhou 510515, People's Republic of China; ²1st Department of Orthopedics, Fujian Provincial Hospital, Fuzhou 350001, People's Republic of China; ³Department of Orthopedics, Jinling Hospital, Nanjing 210008, People's Republic of China; ⁴Department of Endocrinology, Key Laboratory of Endocrinology, Fujian Provincial Hospital, Fuzhou 350001, People's Republic of China

Received October 15, 2015; Accepted November 28, 2015; Epub February 1, 2016; Published February 15, 2016

Abstract: Numbers of patients are suffering from aseptic loosening after total hip replacement, which can need further revision surgery. Particle-induced osteolysis has been considered as a major cause of aseptic loosening after hip joint replacement. This is a prospective study, and there are 82 patients of unilateral osseous arthritis and 10 normal physical examination people in our hospital for this study. The participants were divided into four groups, including control group, No arthroplasty group, joint replacement group and loosened THA group. The osteoclasts cell morphology and osteoclast activity were observed by using the microscopy. The mRNA levels of MCP-1, TNF and RANKL were detected by using the Quantitative reverse transcriptase-polymerase chain reaction (RT-PCR). The results indicated that the bone erosion rates of the joint replacement respectively reached 12.9% and 31.6% after cultured 14 d and 21 d, compare with control, which was remarkably increased ($P<0.05$). The bone erosion rates of loosened THA also reached 43.4% and 88.4%, respectively, after cultured 14 d and 21 d, compare with control, which remarkably increased ($P<0.01$). The loosened THA group of expression level of MCP-1 gene were much higher than joint replacement. Expression level of RANKL gene of loosened THA group was higher 7.4 times than joint replacement. In conclusion, the osteoclast morphology and activity in the peripheral blood and expression levels of MCP-1 can be used for early diagnosis of aseptic loosening after total hip replacement.

Keywords: Biomarkers, aseptic loosening, total hip replacement, osteoclast

Introduction

In recent years, there are more and more end stage arthritis patients treated with joint replacement [1]. And total hip replacement had achieved remarkable achievements in worldwide range [1, 2]. Total hip replacement is an effective surgical intervention for end-stage joint diseases such as osteoarthritis and inflammatory rheumatoid. However part of patients treated with total hip replacement, are still suffering from torment by complications which can need further revision surgery, it also is significantly reduce patients of quality of life [3]. Aseptic loosening of the total hip replacement has been considered to resulting from aseptic inflammatory reactions and mechanical stress. Implanted materials such as debris of high density Polyethylene, metals, bone

cement, wear debris resulted in inflammatory reactions. However, the precise biological mechanisms have not been clarified elucidated [4-6]. Particle-induced osteolysis has been considered as a major cause of aseptic loosening after hip joint replacement.

Currently, clinic diagnostics of aseptic loosening of the total hip replacement is that a circle bright zone around of implants is found by X-rays, but it appear after a long time to joint pain [7]. Emergence of bright zone may be caused by the osteolysis that is osteoclast absorbed and dissolved bone of directly contact with implants [8, 9]. And, osteoclasts were activated by wear debris such as metal ions; polyethylene particles guide the series of bone dissolution reaction, eventually cause prosthesis loosening [10].

Early diagnostic biomarkers of aseptic loosening

If this aseptic loosening can be detected before the symptoms appear, then we can take measures to correct the continued exacerbation of aseptic loosening, and avoid subsequent revision surgery [11]. Consequently, there are new methods aimed at improving diagnostic accuracy and speed of detection for aseptic loosening after total hip replacement. For this purpose, we hope find some effective means to detect the signs of aseptic loosening. The biological indicators can help patient discover loose implants, allowing us to take measures to correct the ongoing osteolysis.

As is known to everyone, multinucleated giant cells do not exist in normal peripheral blood, then the blood of mononuclear cells or macrophages could not become osteoclasts except early proliferative immature monocyte-macrophage (osteoclast precursor cells, OCP) [12]. Osteolysis phenomenon appeared; the OCP of circulating blood volume and the local osteoclasts of numbers significantly increased, and the activity of osteoclasts also were gradually increasing result in resulting in osteolysis [13]. If we could detect osteoclast morphology and activity in the peripheral blood, joint replacement patients may be considered to have started early loosening occurs [14-16]. It may be important factors of aseptic loosening failure that macrophages and fibroblasts have gathered around the prosthesis organization [17, 18]. Expression of nuclear factor- κ B (RANK)/RANK ligand (RANKL) and formation of inflammatory cytokine TNF alpha (TNF α) may promote osteoclast formation and bone resorption [19]. Loosened THA patients had higher levels of chemokines IP-10, MCP-1, and MIG than primary THA patients in the synovial fluid [19, 20]. In order to confirm this hypothesis, the factor of biologic response, such as expression of RANKL, TNF α and MCP-1 were detected. The number and activity of osteolysis in peripheral blood could be as biomarker, it is vital significance for early diagnosis of aseptic loosening.

Materials and methods

Collection of patients' clinical information

A prospective study, there are 82 patients of unilateral osseous arthritis and 10 normal physical examination people in our hospital for this study. The participants were divided into four groups, including control group (normal physical examination people), No arthroplasty group (similar strength of orthopedic surgery,

but no prosthesis implantation of artificial joints), joint replacement group (accepted unilateral osteoarthritis unilateral total hip arthroplasty, selects the type of bone cement prosthesis handle and acetabular cup. All surgery performed by the same group of doctors) and loosened THA group (accepted unilateral osteoarthritis unilateral total hip arthroplasty and diagnosed as loosened).

Cell culture

Extracted approximately 10~20 ml peripheral blood from all participants and placed to anti-coagulant tube, mixed with the same amount of α -MEM which contains 10% fetal bovine serum, M-CSF (macrophage colony stimulating factor) and RANKL (NF- κ B activator receptor ligands). Then sucked up 9 ml mixed liquid, carefully covered on 5 ml human lymphocyte separation liquid level, low temperature (under 20°C), 3000 r/min centrifuge for 30 minutes. After centrifugation, Dark yellow liquid surface layer containing lymphocytes and monocytes were collected, Added to a 96-well plate (24 holes placed pretreated coverslips, wells containing the remaining dentin slices), each well was added 5×10^5 cells and incubated at 37°C for 90 min, then washed away the non-adherent cells.

The TRAP (tartrate resistant acid phosphatase staining) and observation of cell morphology

The same as above, after cultured 7 d, 14 d and 21 d, respectively take out the dyeing, then sealed piece by neutral gum, then read number of multinucleated cells using phase contrast microscopy, calculated occupancy of osteoclasts which were considered as multinucleated cells of containing more than three nucleus and acid acid phosphatase positive.

Osteoclasts activity

After cells were cultured on dentin slices 7 d, 14 d and 21 d, quantitatively measured dentin slices of area and volume of the absorption under inverted microscope to evaluate osteoclast activity.

Quantitative reverse transcriptase-polymerase chain reaction (RT-PCR)

Total RNA of joint replacement group and loosened THA group of blood was isolated by the

Early diagnostic biomarkers of aseptic loosening

Table 1. Nucleotide sequences of primers used to determine agents responsible for loosening of the acetabular components of total hip prostheses

Targets	Forward primer (5'→3')	Reverse primer (5'→3')
TNFα	CATCTTCTCAAATTCGAGTGACA	CCCAACATGGAACAGATGAGGGT
MCP-1	CTCCGCATTTACGCCTAGACA	CTTGACTAGGCGATACGTAC
RANKL	GACATCCCCTCTGGTTCCC	AATACTTGGTGCTTCTCTCC
GAPDH	TCGACAGTCAGCCGCATCTTCTTT	TTCCAGCCTCAGTTGCTAAACCA

Table 2. Clinical characteristics

Characteristics	Control	No arthroplasty	Joint replacement	Loosened THA
Numbers	10	30	26	26
Age (years)	58.2±10.3 ^a	57.9±8.4	59.3±9.5	59.4±10.5
Sex (M/F)	5/5	17/13	16/10	14/12
BMI (Kg/m ²)	27.6±6.1	26.9±6.9	27.1±6.5	27.3±7.5

^amean ± SD; M male; F female.

Table 3. Osteoclasts rate of participant

Groups	Osteoclasts rate (%)		
	7 d	14 d	21 d
Normal persons	0	0	0
No arthroplasty	0	0	0
Joint replacement	3.4±0.5	17.7±5.6	32.1±9.3
Loosened THA	23.4±5.3	82.5±14.7	92.8±20.6

use of RNAi so Plus Kit (Takara, Japan). Reverse transcription was operated by the manufacturer's instructions (Takara, Japan). Quantitative RT-PCR was achieved on an ABI StepOnePlus real-time PCR system (Applied Biosystems, USA). Each reaction contains 10 µl 2×SYBR Green Master Mix Reagent (Takara, Japan), 2.0 µl cDNA sample, and 400 nM of gene-specific primers in a final volume of 20 µl. Primers were designed by primer premier 5.0 software and the sequences were listed in **Table 1**. Amplifications were performed at 95°C for 30 s, followed by 40 cycles of 95°C for 5 s, 60°C for 30 s. GAPDH gene was used as a control to normalize the relative expression of target genes. The change of each gene mRNA level was calculated as 2-ΔCT, where ΔCT = (CT treatment-CT control). The quantitative RT-PCR analysis for each cDNA sample was repeated for three times.

Statistical analysis

In this study, Statistical Package for Social Sciences software (SPSS Inc., Chicago, IL,

USA), version 19.0 were used for statistical analysis. The clinical data were all presented as mean ± SD and compared between groups by the student's t tests. The P<0.05 was considered to indicate a statistically significant difference.

Results

Clinical demographics and characteristics

In the study, there are 82 patients of unilateral osseous arthritis and 10 normal physical examination people. The study included four groups: control group, No arthroplasty group, joint replacement

group and loosened THA group. All participants of study are between the ages of 52~65 years; male 52, female 40; between the BMI of 26.1~27.9 Kg/m². The four groups show no significant difference in age, sex ratio and BMI (**Table 2**).

Abnormalities of monocyte cells morphology and activity in joint replacement and loosened THA

To observe cellular morphology and measure osteoclast activity, collect 10 to 20 ml peripheral bloods of all participants, and isolation and culture monocytes of bloods. These fertile mononuclear macrophages continually were cultured and observed by after 7 d, 14 d and 21 d. randomly select five positions, repeat three times, count and calculate the number and occupancy of multinucleated cells in cultured cells by TRAP tartrate resistant acid phosphatase staining. After tartrate-resistant acid phosphatase staining, positive activity material (multinuclear giant cell) was located in the cytoplasm. After monocyte cells were cultured 7 d, 14 d and 21 d, the normal persons and No arthroplasty's groups, multinucleated cells were absent. When monocyte cells (osteoclast precursors) were cultured on 7 d, Joint replacement and loosened THA groups, cultured cells initiate fusion. And with the prolonged time of culture (14 d and 21 d), the integration of the cell gradually increased. After cultured 21 d, multinuclear giant cell rate of the joint replacement's group reached 32.1±9.3%; multinuclear

Early diagnostic biomarkers of aseptic loosening

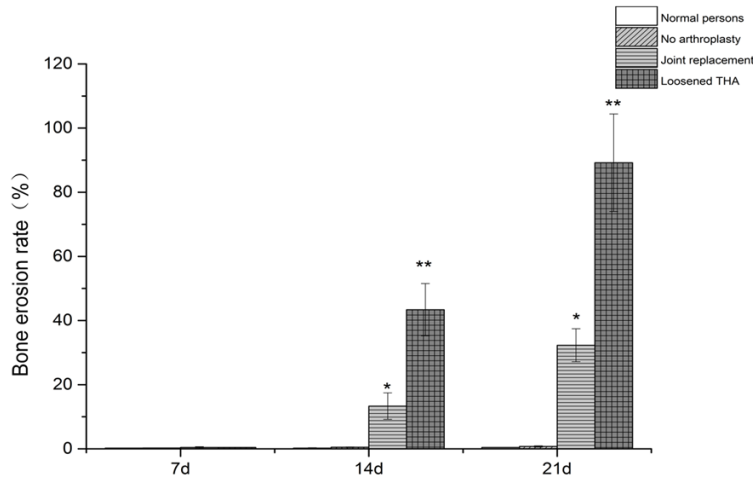


Figure 1. Osteoclast activity of participant.

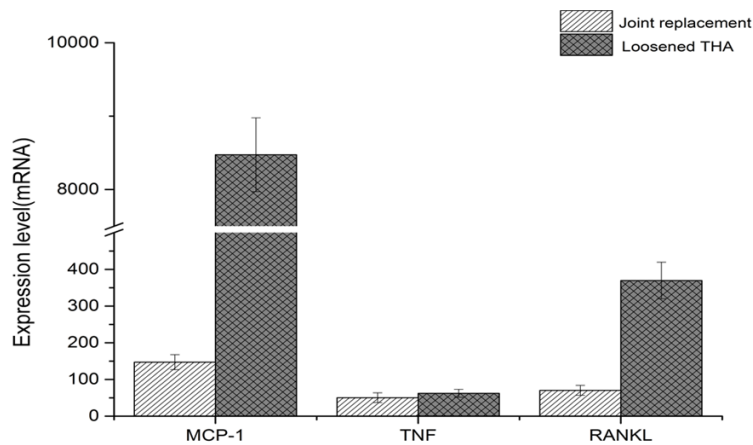


Figure 2. MCP-1, TNF and RANKL of expression level.

giant cell rate of loosened THA's group reached $92.8 \pm 20.6\%$ (Table 3).

At the same time, others of cells were cultured by dentin slices. To evaluate osteoclast activity, quantitatively measured dentin slices of area and volume of the absorption under inverted microscope. Same as multinuclear giant cell rate, in the normal persons and No arthroplasty's groups, bone erosion rates were low quietly after cultured 7 d, 14 d and 21 d. Bone erosion rates of the joint replacement respectively reached 12.9% and 31.6% after cultured 14 d and 21 d, compare with control, it remarkably increased $P < 0.05$; bone erosion rates of loosened THA reached, respectively 43.4% and 88.4% after cultured 14 d and 21 d, compare with control, it remarkably increased $P < 0.01$ (Figure 1).

Expression level of MCP-1 gene in the peripheral blood of joint replacement and loosened THA

Collected peripheral blood samples from participants of the joint replacement and loosened THA groups, extracted mRNA of the samples, detected mRNA level of relevant loosened genes by quantitative RT-PCR. The gene primers were showed in Table 1. In the Figure 2, the loosened THA group of expression level of MCP-1 gene was much higher than joint replacement. Expression level of RANKL gene of loosened THA group was higher 7.4 times than joint replacement. However, expression level of the TNF gene there were little difference between the joint replacement group and loosened THA group (Figure 2).

Discussion

Total hip arthroplasty has become a successful surgery strategy for end stage arthritis patients, which significantly resume normal life [5, 7, 8]. However, there are still many

patients suffering from complications of the failure of the THA which could need further revision surgery [9, 11, 14].

Currently, the precise biological mechanisms of aseptic loosening of the total hip replacement have not been clearly elucidated [21-23]. Aseptic loosening of the total hip replacement has been considered to trigger by multi-factors such as biological, microbiological, biomechanical factors [24, 25]. Mechanical stress and local host responses by the implanted materials is the most important two factors [14, 26-29]. And the implanted materials include high density polyethylene, bone cement, and metals etc. [15, 30-32]. The stimulated inflammatory response by the released wear debris of implants can induce the osteoclast accumulating, excessive resorption, bone loss, and even-

Early diagnostic biomarkers of aseptic loosening

tually periprosthetic osteolysis [33, 34]. Therefore the new biomarkers which is applied for early diagnosis of aseptic loosening of the total hip replacement, can accurately, efficiently, sensitively and rapidly reduce the loose of occurrence and prevent further development to avoid the subsequent revision surgery [35, 36].

In the normal peripheral blood, Giant cells are not present the blood of mononuclear or tissue of macrophages cell cannot be transformed into osteoclasts, only early immature hyperplastic mononuclear macrophage can become the precursor of osteoclast (osteoclast precursor cells, OCP) [25, 27, 37-39]. When bone dissolve is initiated, the number of OCP in blood and local osteoclasts activity significantly increase, eventually leading to bone dissolve and loose [40]. So the hypothesis was proposed, if the number and activity of osteoclast increase, the joint replacement patients may appear early stage of aseptic loosening. In this paper, culture and observe osteoclasts cellular morphology, meanwhile, detect the osteoclast activity to find osteolysis.

Under the circumstances, we can timely take action to intervene further development of aseptic loosening. After cells come from participant of blood were cultured 7 d, 14 d and 21 d, the normal persons and No arthroplasty's groups, multinucleated cells were absent. When monocyte cells (osteoclast precursors) were cultured on 7 d, Joint replacement and loosened THA groups, cultured cells initiate fusion. And with the prolonged time of culture 14 d and 21 d), the integration of the cell gradually increased. After cultured 21 d, osteoclast rate of the joint replacement's group reached $32.1 \pm 9.3\%$; osteoclast rate of loosened THA's group had increased to $92.8 \pm 20.6\%$ (**Table 2**).

Further to verify the correlation between osteoclasts' number and activity, then detect the activity of osteoclast (bone erosion rates). Same as osteoclast rate, in the normal persons and No arthroplasty's groups, bone erosion rates were low quietly after cultured 7 d, 14 d and 21 d. However, bone erosion rates of the joint replacement compare with control, respectively reached 12.9% and 31.6% after cultured 14 d and 21 d, it remarkably increased, $P < 0.05$; bone erosion rates of loosened THA reached respectively 43.4% and 88.4% after cultured 14 d and 21 d, compare with control, it remarkably increased, $P < 0.01$ (**Figure 1**). Our results

suggest that osteoclasts' number and activity in peripheral blood could remind that the patients of accepted prosthesis have been as aseptic loosening after total hip replacement in the early days.

Loosened THA patients had significantly higher RANKL expression on only osteoblastic stromal cells, than primary THA patients [41]. Osteoblastic stromal cells play an important role in the periprosthetic osteolysis induced by wear debris. Numbers of studies showed that positive correlation between the expression levels of IP-10, MCP-1, or MIG in the synovial fluid and RANKL levels of synovial fluid or osteoblastic stromal cells in the periprosthetic bone marrow [42]. In our study, the loosened THA group of expression level of MCP-1 gene was much higher than joint replacement. Expression level of RANKL gene of loosened THA group was higher 7.4 times than joint replacement. The release and expression of cytokines and chemokines from synovial fibroblasts such as IL-6, IL-8, MCP-1 and MCP-2 could be induced micro-particles [43]. This study showed that loosened THA patients had higher levels of MCP-1 in the synovial fluid than primary THA patients. This finding suggests that the effects of MCP-1 periprosthetic osteolysis induced by wear debris in loosened THA are mediated through RANKL expression of synovial fluid. The multinucleated giant cells of blood and MCP-1 in the synovial fluid all may make as biological marker for early failure of aseptic loosening THA in the future. Certainly, we also need to further verify the reliability of this biological marker to guide the early clinical diagnose for aseptic loosening THA.

In conclusion, the present study was considered to evaluate possible function of biological marker (the multinucleated giant cells of blood and MCP-1 in the synovial fluid) for risk of early failure of aseptic loosening THA. The results showed that Emergence and increasing activity of the multinucleated giant cells of blood and the expression levels of MCP-1 in the synovial fluid could prompt osteolysis occur, also further diagnose risk of early failure of aseptic loosening THA.

Disclosure of conflict of interest

None.

Early diagnostic biomarkers of aseptic loosening

Address correspondence to: Dr. Jianning Zhao, Southern Medical University, Guangzhou 510515, People's Republic of China; Department of Orthopedics, Jinling Hospital, Nanjing 210008, People's Republic of China. Tel: +86-25-80860015; Fax: +86-25-1364-1368; E-mail: zhaojning0207@yeah.net

References

- [1] Wei B, Gu Q, Li D, Yan J, Guo Y, Mao F, Xu Y, Zang F, Wang L. Mild degenerative changes of hip cartilage in elderly patients: an available sample representative of early osteoarthritis. *Int J Clin Exp Pathol* 2014; 7: 6493-6503.
- [2] Goldring SR, Jasty M, Roelke MS, Rourke CM, Bringhurst FR, Harris WH. Formation of a synovial-like membrane at the bone-cement interface: Its role in bone resorption and implant loosening after total hip replacement. *Arthritis Rheum* 1986; 29: 836-842.
- [3] Malchau H, Herberts P, Ahnfelt L. Prognosis of total hip replacement in Sweden: follow-up of 92,675 operations performed 1978-1990. *Acta Orthop Scand* 1993; 64: 497-506.
- [4] Ince A, Rupp J, Frommelt L, Katzer A, Gille J, Lohr JE. Is "aseptic" loosening of the prosthetic cup after total hip replacement due to non-culturable bacterial pathogens in patients with low-grade infection? *Clin Infect Dis* 2004; 39: 1599-1603.
- [5] Pagnano MW, Hanssen AD, Lewallen DG, Shaughnessy WJ. The effect of superior placement of the acetabular component on the rate of loosening after total hip arthroplasty. long-term results in patients who have crowe type-ii congenital dysplasia of the hip. *J Bone Joint Surg Am* 1996; 78: 1004-1014.
- [6] Claassen L, Ettinger M, Plaass C, Daniilidis K, Calliess T, Ezechieli M. Diagnostic value of bone scintigraphy for aseptic loosening after total knee arthroplasty. *Technol Health Care* 2014; 22: 767-773.
- [7] Warth LC, Callaghan JJ, Liu SS, Klaassen AL, Goetz DD, Johnston RC. Thirty-five-Year results after charnley total hip arthroplasty in patients less than fifty years old. *J Bone Joint Surg Am* 2014; 96: 1814-1819.
- [8] Parvizi J, Suh DH, Jafari SM, Mullan A, Purtill JJ. Aseptic loosening of total hip arthroplasty: infection always should be ruled out. *Clin Orthop Relat Res* 2011; 469: 1401-1405.
- [9] Hannouche D, Zaoui A, Zadegan F, Sedel L, Nizard R. Thirty years of experience with alumina-on-alumina bearings in total hip arthroplasty. *In Orthop* 2011; 35: 207-213.
- [10] Landgraeber S, Putz S, Schlattjan M, Bechmann LP, Totsch M, Grabellus F, Hilken G, Jager M, Canbay A. Adiponectin attenuates osteolysis in aseptic loosening of total hip replacements. *Acta Biomater* 2014; 10: 384-393.
- [11] Landgraeber S, Quint U, Classen T, Totsch M. Senescence in cells in aseptic loosening after total hip replacement. *Acta Biomater* 2011; 7: 1364-1368.
- [12] Dale H, Fenstad A M, Hallan G, Havelin LI, Furnes O, Overgaard S, Pedersen AB, Karrholm J, Garellick G, Pukkkinen P, Eskelinen A, Makela K, Engesaeter LB. Increasing risk of prosthetic joint infection after total hip arthroplasty: 2,778 revisions due to infection after 432,168 primary THAs in the Nordic Arthroplasty Register Association (NARA). *Acta Orthop* 2012; 83: 449-458.
- [13] Fabi D, Levine B, Paprosky W, Della Valle C, Sporer S, Klein G, Levine H, Hartzband M. Metal-on-metal total hip arthroplasty: causes and high incidence of early failure. *Orthopedics* 2012; 35: e1009-1016.
- [14] Choe H, Inaba Y, Kobayashi N, Ike H, Aoki C, Shizukuishi K, Iwamoto N, Yukizawa Y, Ishida T, Inoue T, Saito T. Use of 18F-fluoride PET to determine the appropriate tissue sampling region for improved sensitivity of tissue examinations in cases of suspected periprosthetic infection after total hip arthroplasty. *Acta Orthop* 2011; 82: 427-432.
- [15] Howie DW, Neale SD, Haynes DR, Holubowycz OT, McGee MA, Solomon LB, Callary SA, Atkins GJ, Findlay DM. Periprosthetic osteolysis after total hip replacement: molecular pathology and clinical management. *Inflammopharmacology* 2013; 21: 389-396.
- [16] Johanson PE, Digas G, Herberts P, Thanner J, Karrholm J. Highly crosslinked polyethylene does not reduce aseptic loosening in cemented THA 10-year findings of a randomized study. *Clin Orthop Relat Res* 2012; 470: 3083-3093.
- [17] Peng KT, Hsu WH, Shih HN, Hsieh CW, Huang TW, Hsu RW, Chang PJ. The role of reactive oxygen species scavenging enzymes in the development of septic loosening after total hip replacement. *J Bone Joint Surg Br* 2011; 93: 1201-1209.
- [18] Trumm BN, Callaghan JJ, George CA, Liu SS, Goetz DD, Johnston RC. Minimum 20-year follow-up results of revision total hip arthroplasty with improved cementing technique. *J Arthroplasty* 2014; 29: 236-241.
- [19] Haverkamp D, Klinkenbijn MN, Somford MP, Albers GH, van der Vis HM. Obesity in total hip arthroplasty-does it really matter? A meta-analysis. *Acta Orthop* 2011; 82: 417-422.
- [20] Melvin JS, Karthikeyan T, Cope R, Fehring TK. Early Failures in Total Hip Arthroplasty-A Changing Paradigm. *J Arthroplasty* 2014; 29: 1285-1288.

Early diagnostic biomarkers of aseptic loosening

- [21] Randau TM, Friedrich MJ, Wimmer MD, Reichert B, Kuberra D, Stoffel-Wagner B, Limmer A, Wirtz DC, Gravius S. Interleukin-6 in Serum and in Synovial Fluid Enhances the Differentiation between Periprosthetic Joint Infection and Aseptic Loosening. *PLoS One* 2014; 9: e89045.
- [22] Garcia-Rey E, Cruz-Pardos A, Madero R. Clinical outcome following conversion of Girdlestone's resection arthroplasty to total hip replacement a retrospective matched case-control study. *Bone Joint J* 2014; 96: 1478-1484.
- [23] Khatod M, Cafri G, Namba RS, Inacio MC, Paxton EW. Risk factors for Total Hip Arthroplasty Aseptic Revision. *J Arthroplasty* 2014; 29: 1412-1417.
- [24] Lübbeke A, Garavaglia G, Barea C, Stern R, Peter R, Hoffmeyer P. Influence of patient activity on femoral osteolysis at five and ten years following hybrid total hip replacement. *J Bone Joint Surg Br* 2011; 93: 456-463.
- [25] Michaëlsson K. Surgeon volume and early complications after primary total hip arthroplasty. *BMJ* 2014; 348: g3433.
- [26] Del Buono A, Denaro V, Maffulli N. Genetic susceptibility to aseptic loosening following total hip arthroplasty: a systematic review. *Br Med Bull* 2011; 101: 39-55.
- [27] Mäkelä KT, Eskelinen A, Pulkkinen P, Paavolainen P, Remes V. Results of 3,668 primary total hip replacements for primary osteoarthritis in patients under the age of 55 years: A follow-up of a previous report from the Finnish Arthroplasty Register. *Acta Orthop* 2011; 82: 521-529.
- [28] Haraguchi K, Koyanagi J, Tsuda K. Results of the Long-Term Follow-Up Study After the Metasul Metal-on-Metal Cementless Total Hip Arthroplasty[M]//Tribology in Total Hip and Knee Arthroplasty. Springer Berlin Heidelberg 2014; 145-151.
- [29] Chalmers PN, Sporer SM, Levine BR. Correlation of Aspiration Results With Aseptic Loosening in Total Hip Arthroplasty. *J Arthroplasty* 2013; 28: 1671-1676.
- [30] Wyles CC, Van Demark III RE, Sierra RJ, Trousdale RT. High rate of infection after aseptic revision of failed metal-on-metal total hip arthroplasty. *Clin Orthop Relat Res* 2014; 472: 509-516.
- [31] Prokopetz JJ, Losina E, Bliss RL, Wright J, Baron JA, Katz JN. Risk factors for revision of primary total hip arthroplasty: a systematic review. *BMC Musculoskelet Disord* 2012; 13: 251.
- [32] Waris V, Sillat T, Waris E, Virkki L, Mandelin J, Takagi M, Kontinen YT. Role and regulation of VEGF and its receptors 1 and 2 in the aseptic loosening of total hip implants. *J Orthop Res* 2012; 30: 1830-1836.
- [33] Zhang L, Yang D, Yin X, Zhou Y. Risk factors for poor hip flexion after total hip arthroplasty for the treatment of ankylosing spondylitis a multivariate analysis. *Clin Rheumatol* 2014; 33: 1-7.
- [34] Koenig K, Huddleston JI, Huddleston H, Maloney WJ, Goodman SB. Advanced age and comorbidity increase the risk for adverse events after revision total hip arthroplasty. *J Arthroplasty* 2012; 27: 1402-1407, e1.
- [35] Sadoghi P, Liebensteiner M, Agreiter M, Leithner A, Bohler N, Labek G. Revision surgery after total joint arthroplasty: a complication-based analysis using worldwide arthroplasty registers. *J Arthroplasty* 2013; 28: 1329-1332.
- [36] Fritz EA, Glant TT, Vermes C, Jacobs JJ, Roebuck KA. Titanium particles induce the immediate early stress responsive chemokines IL-8 and MCP-1 in osteoblasts. *J Orthop Res* 2002; 20: 490-498.
- [37] Purdue PE, Koulouvaris P, Potter HG, Nestor BJ, Sculco TP. The cellular and molecular biology of periprosthetic osteolysis. *Clin Orthop Relat Res* 2007; 454: 251-261.
- [38] Wang CT, Lin YT, Chiang BL, Lee SS, Hou SM. Over-expression of receptor activator of nuclear factor- κ B ligand (RANKL), inflammatory cytokines, and chemokines in periprosthetic osteolysis of loosened total hip arthroplasty. *Biomaterials* 2010; 31: 77-82.
- [39] Gallo J, Raska M, Mrazek F, Petrek M. Bone remodeling, particle disease and individual susceptibility to periprosthetic osteolysis. *Physiol Res* 2008; 57: 339-349.
- [40] Goodman S. Wear particulate and osteolysis. *Orthop Clin North Am* 2005; 36: 41-48.
- [41] Ingham E, Fisher J. The role of macrophages in osteolysis of total joint replacement. *Biomaterials* 2005; 26: 1271-1286.
- [42] Landgraeber S, Toetsch M, Wedemeyer C, Saxler G, Tsokos M, von Knoch F, Neuhauser M, Loer F, von Knoch M. Over-expression of p53/BAK in aseptic loosening after total hip replacement. *Biomaterials* 2006; 27: 3010-3020.
- [43] Shanbhag AS, Hasselman CT, Rubash HE. Inhibition of wear debris mediated osteolysis in a canine total hip arthroplasty model. *Clin Orthop Relat Res* 1997; 344: 33-43.