

Original Article

Increased mast cell numbers associated with nerve fiber alterations in the colon from Hirschsprung's disease patients

Shiqi Wang^{1,2,3}, Xianqing Jin^{1,2,3}, Xin Wang^{1,2,3}, Xionghui Ding^{1,2,3}, Ning Wang^{1,2,3}

¹Department of Pediatric Surgery, Children's Hospital of Chongqing Medical University, Ministry of Education Key Laboratory of Child Development and Disorders, Chongqing, China; ²China International Science and Technology Cooperation Base of Child Development and Critical Disorders, Chongqing, China; ³Chongqing Key Laboratory of Pediatrics, Chongqing, China

Received October 17, 2015; Accepted November 26, 2015; Epub February 1, 2016; Published February 15, 2016

Abstract: This study is aimed to investigate the pathogenesis of Hirschsprung's disease (HSCR) through examination of quantitative and morphological changes of mast cells (MCs) and nerve fibers in different segments of affected colon. Stenotic, transitional, and dilated segments were collected from HSCR patients (n = 62) at the Children's Hospital of Chongqing Medical University from January 2011 to December 2013 (Chongqing, China). Control samples were collected from patients (n = 10) who had died from non-gastrointestinal disease. Toluidine blue staining, immunohistochemistry (mast cell tryptase and S100 antibodies), and compound staining were performed to identify and morphologically characterize MCs and nerve fibers. Sections were examined under light microscopy for the distribution and morphology of MCs and nerve fibers, and the results were evaluated with color image analyzing software. MCs were localized in mucosal and submucosal layers, and accumulated around the nerve fibers in HSCR samples. The number of MCs in stenotic HSCR intestine was significantly greater than in dilated intestine or in controls ($P < 0.05$). Furthermore, MC degranulation and S100-positive fibers were found at a greater degree in the stenotic intestine group ($P < 0.05$). Finally, the number and the area of S100-positive fibers were positively correlated with the number of MCs ($r = 0.513$, $P < 0.01$; $r = 0.474$, $P < 0.01$). The number and morphological changes in MCs and nerve fibers were positively correlated in HSCR samples, indicating that the interaction of MCs with nerve fibers may play an important role in the pathogenesis of HSCR.

Keywords: Hirschsprung's disease, mast cells, nerve fiber, degranulation

Introduction

Hirschsprung's disease (HSCR) is a rare congenital disorder of the colon in which certain nerve cells, known as ganglion cells, are absent, causing bowel dysfunction and affecting the overall health of the child. HSCR occurs in one out of 5000 newborns and makes up ~25% of pediatric digestive tract malformations, with major clinical manifestations, such as constipation and enterocolitis [1, 2]. While the disease can be corrected surgically, it is lethal if untreated. Thus, early diagnosis is imperative for successful outcomes.

Mast cells (MCs) are involved in physiological processes such as host defense against bacteria and tissue remodeling [3-5]. In recent years, studies have shown that MCs appear to contrib-

ute to the pathogenesis of HSCR, although the mechanism is not yet well-defined [6]. MCs, derived from bone marrow precursor cells, are widely distributed in mucous membranes and connective tissues of the respiratory, gastrointestinal, and urinary tracts, and are important effector, regulatory immune cells which play a key role in the nerve-immune-endocrine network. MCs are filled with basophilic cytoplasmic granules, which contain many bioactive substances, such as histamine, proteoglycan, 5-serotonin, leukotriene, platelet activation factor, prostaglandin, tryptase, chymotrypsin, and a variety of interleukins [7]. Through the release of these various factors from the cytoplasmic granules by exocytosis (degranulation), MCs regulate and orchestrate many different physiological processes when stimulated [8].

Gastrointestinal MCs are of two subtypes: MCs positive for tryptase with no immunodetectable chymase (MCT) or MCs positive for both tryptase and chymase (MCTC). These two types of MCs are involved in many physiological processes of the intestine, including intestinal immunity, intestinal motility, intestinal permeability and secretion of digestive enzymes, which are collectively known as the fourth intestinal mucosa barrier [9, 10].

As important members of the gastrointestinal immune system, MCs have complex interactions with the enteric nervous system (ENS). When activated, MCs can amplify and transfer a signal to adjacent nerve fibers and neurons by releasing factors such as histamine. In turn, the ENS can also influence MCs by releasing neurotransmitters or neuropeptides such as substance P after stimulation. MCs and the ENS thus interact closely for the normal regulation of the immune system and gastrointestinal function but are also related to the development of Irritable Bowel Syndrome and food allergies leading to chronic constipation and other gastrointestinal disorders [11-14].

Quantitative and regional alterations in MCs have been observed on histological examination. MCs are frequently observed in contact with blood vessels and nerve fibers in HSCR [15]. An increased number of MCs in the aganglionic segment of the intestine has been previously described in HSCR patients [6]. Furthermore, the number of MCs was found to be significantly less in transitional segments compared to ganglionic segments of HSCR patients relative to controls. Here, in order to further investigate the role of MCs in HSCR, quantitative and morphological features of MCs and nerve fibers in different intestinal segments were examined in a cohort of Chinese patients with HSCR.

Materials and methods

Ethics statement

Protocols were approved by the Ethics Committee of the Children's Hospital, Chongqing Medical University (Chongqing, China). Written informed consent was obtained from the parents of all patients recruited for the study.

Tissue samples and clinical characteristics of patients

The stenotic, transitional, and dilated segments were collected from HSCR patients (n = 62; male n = 48, female n = 14) at the Children's Hospital of Chongqing Medical University from January 2011 to December 2013. The age of the patients ranged from 14 days to 13 years: < 1 month (n = 3); 1 to 3 months (n = 14); 3 months to 1 year (n = 22); and > 1 year (n = 23). Clinical HSCR types were classified as common (n = 38), long segment (n = 14), and short segment (n = 10). Before surgery, all of the patients underwent barium enema, histochemical rectal mucosa acetylcholinesterase analysis, and anorectal manometry. A final diagnosis of HSCR was confirmed as the absence of ganglion cells in the myenteric nerve plexus of the stenotic segment on frozen section during surgery and HE stain following surgery. Control bowel specimens (n = 10; male n = 4, female n = 6) were obtained from patients who had died of non-gastrointestinal disease. Age ranged from 10 days to 12 years. Full thickness samples were taken in cases where mature ganglion cells were observed on hematoxylin & eosin (HE) stained stenotic, transitional, and dilated segments by light microscopy. All pathological data for patients and controls were intact. Fresh tissue samples were immediately fixed in 10% neutral formalin and embedded in paraffin. Each paraffin block was serially dissected into 5 sections (3 µm thickness), which were numbered 1, 2, 3, 4, and 5, respectively, and stored until further use.

Reagents and instruments

Toluidine blue (TB; Shanghai Chemical Reagent Company; Shanghai, China) was used for differential staining of MC. Immunohistochemistry was performed with mast cell tryptase rabbit monoclonal antibody (ab151757; Abcam; Cambridge, MA, USA), S100 rabbit anti-human antibody (Fuzhou Maixin Biology Technology Development Co., Ltd.; Fujian, China), and visualized with the Immunohistochemistry Elivision™ Super Kit (Fuzhou Maixin Biotechnology Development Co., Ltd.) and Diaminobenzidine (DAB) (Beijing Zhongshan Jinqiao Biotechnology Co., Ltd.; Beijing, China). Analysis under light microscopy was performed with the Nikon ECLIPSE 55i microscope (Tokyo, Japan) and the

Mast cells in Hirschsprung's disease

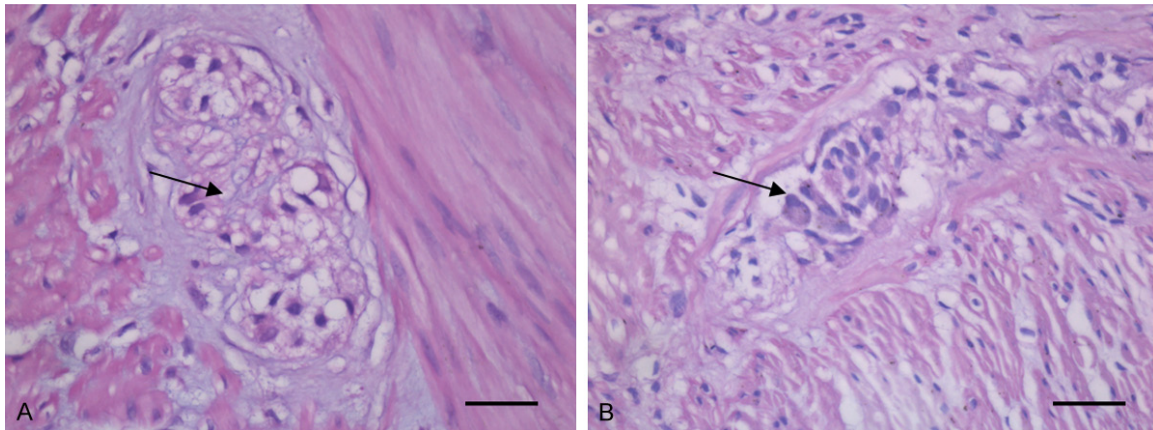


Figure 1. HE staining of ganglionic (control) and aganglionic (HSCR) intestine. Fixed HE sections of (A) control and (B) stenotic HSCR tissues under light microscopy ($\times 400$). Arrows (\rightarrow) highlight ganglion cells. Scale bar = 50 μm .

YC.YX-2050 pathological image analysis system (ZEISS; Beijing, China).

HE staining

A diagnosis of HSCR was based on HE staining of ganglion cells and confirmed on review of the surgical pathological reports of the biopsies from resections.

Slide pretreatment

For all histochemical analyses performed on paraffin embedded sections, slides were first heated to 60°C for 2 hr, and deparaffinized and hydrated in a xylene and alcohol series.

Toluidine blue stain

Sections were stained in 0.5% TB for 20 min, rinsed in running tap water, and exposed to 0.5% glacial acetic acid for differential staining. Sections were mounted and examined. MC appeared violet under light microscopy.

Immunohistochemical stain

Antigen retrieval was performed, and sections were subsequently preincubated in 3% H_2O_2 at room temperature for 10 min to quench endogenous peroxidase. Sections were incubated with primary antibody overnight at 4°C and rinsed with 0.01 mol/L PBS. Primary antibody was replaced with PBS for the negative control. For signal amplification, incubations of sections were performed at room temperature for 10 min first with solution A (amplification agent) of Elivision™ Super Kit followed by solution B

(polymerase conjugates) of the secondary antibody kit. For visualization, sections were incubated in DAB for 3 min and rinsed in running tap water to stop the reaction. Sections were counterstained with hematoxylin, rinsed in running tap water, mounted, and examined under light microscopy.

Compound staining

All steps of the immunohistochemistry protocol were performed as described including/excluding the DAB reaction. Sections were subsequently stained in 0.5% TB for 20 min, rinsed in running tap water, exposed to 0.5% glacial acetic acid for differential staining, and mounted. MCs appeared violet under light microscopy.

Image analysis

Under light microscopy, MCs were stained violet by TB, but brown through immunohistochemistry. Intact and degranulated MCs were counted in 10 random fields ($\times 200$) in the mucosal or submucosal layer. The density of MCs was expressed as the total number of MC/10 (fields) and the ratio of degranulated MCs as the number of degranulated MC/total number of MC. S100-positive nerve fibers were stained tan under light microscopy. Intact nerve plexus was examined and recorded in 10 random fields ($\times 200$) in the submucosal layer. The density of nerve fibers was expressed as the total number of nerve fibers/10 (fields). The mean area of nerve fibers was calculated with the YC.YX-2050 pathological image analysis

Mast cells in Hirschsprung's disease

Table 1. Comparison of MC density and degranulation in HSCR and control cases ($\bar{x} \pm s$)

Group	Stenotic section	Transition section	Dilated section	Non-HSCR cases
MC density/TB staining	19.64 \pm 3.62 ^{a,b}	12.83 \pm 2.74 ^{a,b}	5.02 \pm 1.81	4.49 \pm 1.65
MC density/Imm-unochemical staining	20.55 \pm 3.74 ^{a,b}	13.09 \pm 3.01 ^{a,b}	5.43 \pm 1.55	4.87 \pm 1.72
Degranulation/%	26.32 \pm 4.57 ^{a,b}	19.62 \pm 4.12 ^{a,b}	12.05 \pm 2.81	11.90 \pm 3.17

^aP < 0.05 for the comparison to the control group; ^bP < 0.05 for the comparison to the dilated section.

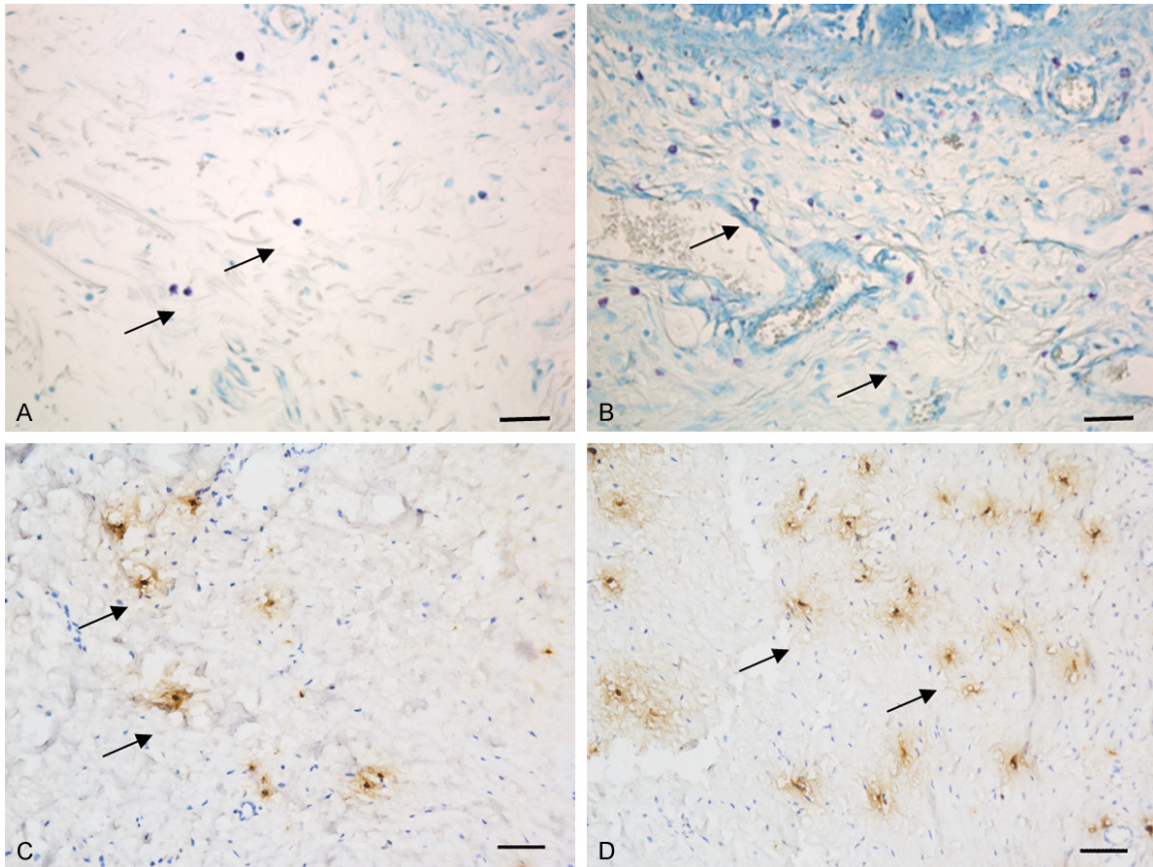


Figure 2. Degranulated morphology of mast cells in HSCR patients. MCs were identified in tissue sections from HSCR patients and controls, with Toluidine blue and immunohistochemical staining with mast cell tryptase rabbit monoclonal antibody ($\times 200$). A. Control, Toluidine blue; B. HSCR stenotic section, Toluidine blue; C. Control, immunohistochemistry; D. HSCR stenotic section, immunohistochemistry. Arrows (\rightarrow) highlight mast cells. Scale bar = 50 μ m.

system. Measurements were performed by two experienced pathologists independently.

Statistical analysis

All statistical analyses were performed with SPSS statistical software (version 17.0, 2008, SPSS Inc.; Chicago, IL, USA). Data are presented as the mean \pm SEM. Differences between groups were compared using ANOVA and the relationship between variables using the Pearson correlation coefficient. P < 0.05 was regarded as statistically significant.

Results

Mast cells

Pathological examination of histological sections was performed to confirm HSCR diagnosis and to characterize MCs by morphology, location, and number. Aganglionic colonic segments were defined by the absence of the ganglion cells and first identified through HE staining (**Figure 1**). The results were consistent with the original diagnosis made before surgery on the basis of barium enema, histochemical rec-

Mast cells in Hirschsprung's disease

Table 2. Density and size of nerve fibers in HSCR and non-HSCR cases ($\bar{x} \pm s$)

Group	Stenotic section	Transition section	Dilated section	Non-HSCR cases
Density of nerve fibers	7.44 ± 3.03 ^{a,b}	6.39 ± 2.82 ^{a,b}	3.36 ± 2.13	2.92 ± 2.41
Area of nerve fibers/ μm^2	978.63 ± 432.71 ^{a,b}	658.43 ± 231.65 ^{a,b}	303.62 ± 207.93	292.75 ± 193.22

^aP < 0.05 for comparison to the control group; ^bP < 0.05 for comparison to the dilated section.

tal mucosa acetylcholinesterase analysis, and anorectal manometry.

Under light microscopy, MCs appeared purple with blue cytoplasm when stained with TB, and brown through immunohistochemistry. MCs were mainly distributed in the mucosa, lamina propria, and the submucosa. Fewer MCs were observed in the muscular layer and serosa. Statistical analysis of the MC numbers in submucosa obtained by the two staining methods demonstrated that TB and immunohistochemistry were comparable for MC counts. MC density in the stenotic segment, transitional segment, dilated segment, and control submucosa were 19.64 ± 3.62, 12.83 ± 2.74, 5.02 ± 1.81 and 4.49 ± 1.65 by TB staining, and 20.55 ± 3.74, 13.09 ± 3.01, 5.43 ± 1.55, 4.87 ± 1.72 by immunohistochemical staining respectively (**Table 1**). Differences in MC numbers between stenotic and dilated sections were statistically significant in HSCR patients (P < 0.05), as well as between transition and dilated sections (P < 0.05). Furthermore, MC counts were increased in stenotic and transition sections from HSCR patients relative to controls (P < 0.05).

The morphology of the normal MCs was integrated, round or spindle shaped, with uniform cytoplasm and distinct membranes. Degranulated MCs appeared irregular in shape, with ulcerated membranes and many particles from cell membranes. The degree of degranulation was significantly increased in stenotic and transition sections of patients compared to the controls (P < 0.05; **Figure 2**). The data obtained for evaluation of MCs are summarized in **Table 1**.

Nerve fibers

To reveal morphological changes in nerve fibers, immunostaining with antibody against S100 was performed on patient and control samples. Nerve fibers, which were located in the submucosal plexus and the myenteric plexus, stained positive for S100, and S100 stain-

ing appeared as dots, lines, or clusters. In contrast, S100 staining was absent in the ganglion cells and appeared as a blank area in the plexus. Hyperplasia, enhanced staining, curved shape, and increased area of S100 positive nerve fibers were evident in sections from the HSCR patients (P < 0.05; **Figure 2**). The data obtained for the evaluation of nerve fibers are summarized in **Table 2**.

Mast cells and nerve fibers

In order to examine the relationship between MC and nerve fibers, compound staining was performed on tissue sections to highlight the position of MCs relative to nerve fibers. First, MCs were observed to accumulate around blood vessels and nerve fibers. Second, MCs were distributed along or clustered around the hypertrophic S100 positive nerve fibers (**Figures 3 and 4**), such that a positive relationship emerged between the density of MC and nerve fibers (correlation coefficient = 0.513; P < 0.01). Furthermore, the density of MC also correlated well with the increase in area of nerve fibers in HSCR patients (correlation coefficient = 0.474, P < 0.01). Finally, the rate of degranulation of nerve fibers and vessels by MC in HSCR submucosal segments was 29.38 ± 5.52%, which was significantly greater than in other segments (18.61 ± 4.12%; P < 0.01).

Discussion

The fact that HSCR is a surgically manageable disease if diagnosed early, underscores the need to identify these cases as early as possible [16]. A crucial method for early diagnosis and/or treatment is an understanding of the underlying mechanism(s), which to date remains unclear. In the present study, MC morphology and numbers were evaluated, as well as the methods to detect them, in resected specimens from cases of HSCR and compared to controls. Our results corroborate previous indications that MCs may affect adjacent neu-

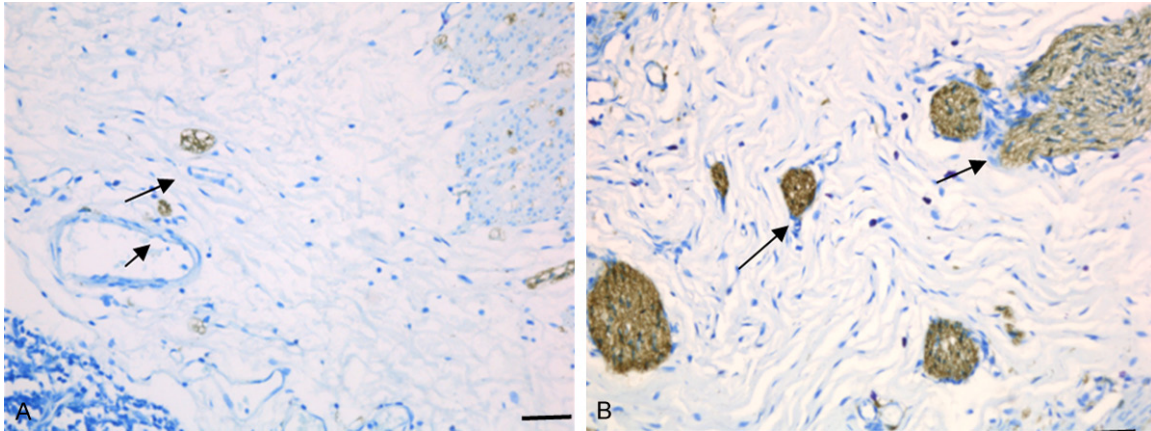


Figure 3. Nerve fibers in HSCR submucosa are hypertrophic. Immunohistochemistry with S-100 antibody was performed to identify nerve fibers in the submucosa of patients and controls ($\times 200$). A. Control; B. HSCR stenotic section. Arrows (\rightarrow) highlight nerve fibers. Scale bar = 50 μm .

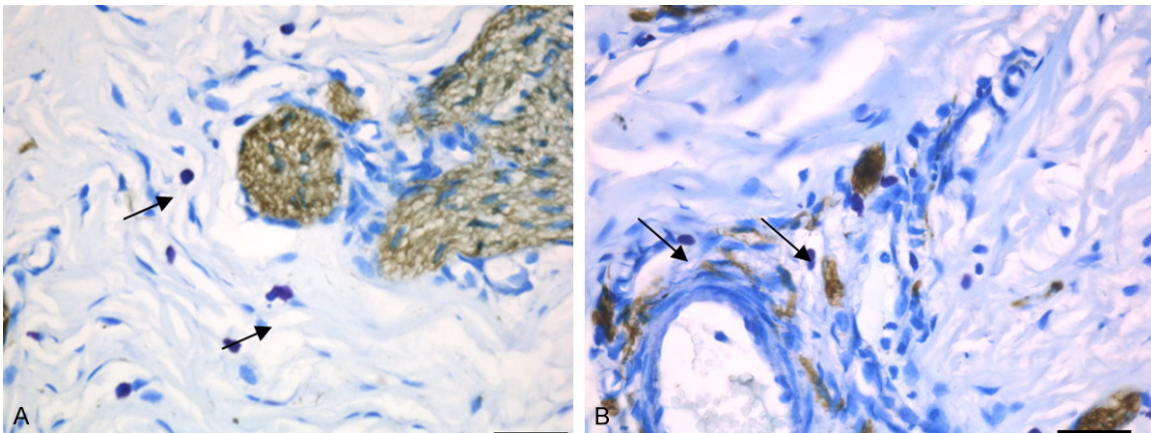


Figure 4. Mast cells accumulate around nerve fibers and small blood vessels in the submucosal layer of the spasm segment in HSCR patients. Compound staining (TB with antibody staining for S-100) was performed on patient samples ($\times 400$). A. Nerve fibers; B. Small blood vessels. Arrows (\rightarrow) highlight mast cells. Scale bar = 100 μm .

rons and thus, play a role in the pathogenesis of HSCR [17].

Immunohistochemical detection of MCs with anti-mast cell tryptase, although frequently reported in other studies, has been found to be less accurate than Toluidine blue staining [18]. Therefore, MC numbers were compared in cases and controls by both methods in our study. Toluidine blue staining is a simple and effective method, requiring an incubation time as short as one minute [19, 20]. In our hands, a similar result, namely that MCs were increased in HSCR cases compared to controls, was obtained by both methods. In addition, a degranulation rate for MCs, based on these methods, was determined for the first time.

Degranulation rate as a measure of MC behavior was easier to determine compared to immunohistochemical staining due to the ability to observe morphological changes in MCs. The results demonstrated that the degranulation rate was significantly higher in spasm segments compared to controls, indicating that MCs were activated in the spasm segment of HSCR. These findings together strongly implicate MC degranulation as a potential mechanism contributing to the pathogenesis of HSCR.

Neural hypertrophy in the colonic submucosa is associated with aganglionosis and is a surrogate marker for HSCR [21]. The thickness of submucosal nerve fibers has been measured in many studies previously. However, less objec-

tive methods for measurement such as image graticules have been used [22]. In this study, the status of the nerve fibers was analyzed with S100 immunostaining and image analysis software. S100 is a protein expressed in glial cells and is present in nerve fibers, but absent in ganglion cells. Therefore, S100 may be a better marker in the study of enteric nervous system morphology [23]. In our study, the density and size of nerve fibers in the colonic submucosa of HSCR and control cases were measured and directly compared. The difference between the two groups was statistically significant for the two parameters. In addition, the two parameters were also correlated by image analysis morphometry of the nerve fibers with MC numbers. Thus, by all methods employed, a significant positive correlation was observed between the number and the area of nerve fibers.

An intriguing possibility based on these results is that factors derived from MCs may affect size and proliferation of nerve fibers. MCs release a number of biologically active substances from their cytoplasmic granules during activation, and some of these substances are likely to have an effect on adjacent nerve fibers or neurons [24]. Morphometric parameters of nerve fibers and number of MCs in aganglionic segment were increased compared to normally innervated colon, indicating that the proliferation of nerve fibers had occurred. Both paracrine factors, such as substance P, a calcitonin gene related protein, or somatostatin from MCs, or autocrine factors, such as neuropeptides or neurotransmitters, may stimulate this response in neurons [25]. In fact, elevated content of neuronal growth factor and increased number of MCs in the aganglionic colon wall in pediatric HSCR has been observed [26]. Based on these results, we propose that a synergistic relationship between MCs and the intestinal nervous system exists in HSCR patients.

However, in a recent study of a cohort of Indian HSCR children, a poor correlation between the number of MCs and the perimeter of nerve fibers ($r = 0.274$) was observed [19]. This result may be due to differences in the quality, for example, of specimen samples as well as in measuring methods. The exact role of these cells in the pathogenesis of HRSC, thus, requires further investigation with a focus on

the enteric nervous system and its development, and the role of MCs in cases where ganglion cells are absent.

In conclusion, MCs may have a significant role in the pathogenesis and development of Hirschsprung's disease from neural immunological aspects, and the mechanism underlying disease development may be due to a synergistic effect between MCs and the intestinal nervous system. Thus, these findings provide a potential basis for the future diagnosis and treatment of HRSC. Further studies are necessary, however, to illuminate a more detailed mechanism for the participation of MCs in the disease and whether an inhibitor of MCs would improve and/or eradicate symptoms of HRSC patients.

Acknowledgements

The authors are grateful to the patients involved in this study and their families. This work was supported by the National Natural Science Foundation of China (grant 81370474).

Disclosure of conflict of interest

None.

Address correspondence to: Dr. Xianqing Jin, Department of Pediatric Surgery, Affiliated Children's Hospital, Chongqing Medical University, 136 Zhongshan 2nd Road, Yuzhong District, Chongqing 86400014, China. Tel: +86-63638834; Fax: +86-63638834; E-mail: etzhl@163.com

References

- [1] Emison ES, McCallion AS, Kashuk CS, Bush RT, Grice E, Lin S, Portnoy ME, Cutler DJ, Green ED, Chakravarti A. A common sex-dependent mutation in a RET enhancer underlies Hirschsprung disease risk. *Nature* 2005; 434: 857-863.
- [2] Martucciello G, Pini Prato A, Puri P, Holschneider AM, Meier-Ruge W, Jasonni V, Tovar JA, Grosfeld JL. Controversies concerning diagnostic guidelines for anomalies of the enteric nervous system: a report from the fourth International Symposium on Hirschsprung's disease and related neurocristopathies. *J Pediatr Surg* 2005; 40: 1527-1531.
- [3] Bischoff SC. Physiological and pathophysiological functions of intestinal mast cells. *Semin Immunopathol* 2009; 31: 185-205.
- [4] Kalesnikoff J, Galli SJ. New developments in mast cell biology. *Nat Immunol* 2008; 9: 1215-1223.

Mast cells in Hirschsprung's disease

- [5] Galli SJ, Grimaldeston M, Tsai M. Immunomodulatory mast cells: negative, as well as positive, regulators of innate and acquired immunity. *Nat Rev Immunol* 2008; 8: 478-486.
- [6] Kobayashi H, Yamataka A, Fujimoto T, Lane GJ, Miyano T. Mast cells and gut nerve development: implications for Hirschsprung's disease and intestinal neuronal dysplasia. *J Pediatr Surg* 1999; 34: 543-548.
- [7] He SH. Key role of mast cells and their major secretory products in inflammatory bowel disease. *World J Gastroenterol* 2004; 10: 309-318.
- [8] Franceschini B, Ceva-Grimaldi G, Russo C, Di-guardi N, Grizzi F. The complex functions of mast cells in chronic human liver diseases. *Dig Dis Sci* 2006; 51: 2248-2256.
- [9] Bischoff SC. Physiological and pathophysiological functions of intestinal mast cells. *Semin Immunopathol* 2009; 31: 185-205.
- [10] Wang LH, Fang XC, Pan GZ. Bacillary dysentery as a causative factor of irritable bowel syndrome and its pathogenesis. *Gut* 2004; 53: 1096-1101.
- [11] Borrelli O, Barbara G, Di Nardo G, Cremon C, Lucarelli S, Frediani T, Paganelli M, De Giorgio R, Stanghellini V, Cucchiara S. Neuroimmune interaction and anorectal motility in children with food allergy-related chronic constipation. *Am J Gastroenterol* 2009; 104: 454-463.
- [12] Leon A, Buriani A, Dal Toso R, Fabris M, Romanello S, Aloe L, Levi-Montalcini R. Mast cells synthesize, store, and release nerve growth factor. *Proc Natl Acad Sci U S A* 1994; 91: 3739-3743.
- [13] Hamilton MJ, Frei SM, Stevens RL. The Multifaceted Mast Cell in Inflammatory Bowel Disease. *Inflamm Bowel Dis* 2014; 20: 2364-2378.
- [14] Sandborn WJ, Feagan BG, Rutgeerts P, Hanauer S, Colombel JF, Sands BE, Lukas M, Fedorak RN, Lee S, Bressler B, Fox I, Rosario M, Sankoh S, Xu J, Stephens K, Milch C, Parikh A. Vedolizumab as induction and maintenance therapy for Crohn's disease. *N Engl J Med* 2013; 369: 711-721.
- [15] Zheng B, Chen YM, Wei FM, Guo ZY, Zhao SY, Li P. Distribution of mast cells and its role in the pathogenesis of Hirschsprung disease. *Chin J Gastrointest Surg* 2009; 12: 507-510.
- [16] Hermanowicz A, Debek W, Dzienis-Koronkiewicz E, Chyczewski L. Topography and morphometry of intestinal mast cells in children with Hirschsprung's disease. *Folia Histochem Cytobiol* 2008; 46: 65-68.
- [17] Bergeron KF, Silversides D, Pilon N. The developmental genetics of Hirschsprung's disease. *Clin Genet* 2013; 83: 15-22.
- [18] Zheng H, Chen YM, Wei MF, Guo ZY, Zhao SY, Li P. Distribution of mast cells and its role in the pathogenesis of Hirschsprung disease. *Zhonghua Wei Chang Wai Ke Za Zhi* 2009; 12: 507-10.
- [19] Yadav AK, Mishra K, Mohta A, Agarwal S. Hirschsprung's disease: is there a relationship between mast cells and nerve fibers? *World J Gastroenterol* 2009; 15: 1493-1498.
- [20] Kulka M, Metcalfe DD. Isolation of tissue mast cells. *Curr Protoc Immunol* 2010; Chapter 7: Unit 7.25.
- [21] Volpe A, Alaggio R, Midrio P, Iaria L, Gamba P. Calretinin, β -tubulin immunohistochemistry, and submucosal nerve trunks morphology in Hirschsprung disease: possible applications in clinical practice. *J Pediatr Gastroenterol Nutr* 2013; 57: 780-787.
- [22] Yang WI, Oh JT. Calretinin and microtubule-associated protein-2 (MAP-2) immunohistochemistry in the diagnosis of Hirschsprung's disease. *J Pediatr Surg* 2013; 48: 2112-2117.
- [23] Mohanraj A, Srinivasan S. Role of s-100 immunostaining in demonstration of nerve changes and quantification of dendritic cells in leprosy. *J Clin Diagn Res* 2014; 8: 38-40.
- [24] Sipos G, Sipos P, Altdorfer K, Pongor E, Fehér E. Correlation and immunolocalization of substance P nerve fibers and activated immune cells in human chronic gastritis. *Anat Rec (Hoboken)* 2008; 291: 1140-1148.
- [25] Castellani ML, Galzio RJ, Felaco P, Tripodi D, Toniato E, De Lutiis MA, Conti F, Fulcheri M, Conti C, Theoharides TC, Caraffa A, Antinolfi P, Felaco M, Tete S, Pandolfi F, Shaik-Dasthagiri-saheb YB. VEGF, substance P and stress, new aspects: a revisited study. *J Biol Regul Homeost Agents* 2010; 24: 229-237.
- [26] Demirbilek S, Ozardali HI, Aydm G. Mast-cells distribution and colonic mucin composition in Hirschsprung's disease and intestinal neuronal dysplasia. *Pediatr Surg Int* 2001; 17: 136-139.