

Case Report

Carcinosarcoma of the gallbladder accompanied with cholecystolithiasis: a case report

Weijian Hu^{1*}, Gongting Zhou^{1*}, Shengqiang Gao¹, Lin Wu², Haili Bao¹, Huajun Yu¹, Qiyu Zhang¹

Departments of ¹Hepatobiliary Surgery, ²Pathology, The First Affiliated Hospital of Wenzhou Medical University, Wenzhou, Zhejiang, P. R. China. *Equal contributors.

Received October 28, 2015; Accepted December 25, 2015; Epub February 1, 2016; Published February 15, 2016

Abstract: Carcinosarcoma of the gallbladder is a rare malignancy characterized by malignant epithelial and mesenchymal components. We herein report a case of a patient in a 68-year-old woman, with carcinosarcoma of the gallbladder. The patient is treated by cholecystostomy. Histologically, the epithelial component of the tumor was composed of adenocarcinoma and the mesenchymal component with spindle cells. The tumor invaded the ligamentum hepatoduodenale, hepatic flexure of colon, part of the transverse mesocolon, and liver first porta. So we decided to do the cholecystostomy. The prognosis of carcinosarcoma of the gallbladder remains poor, and thus, the authors recommend that effort should be made to improve surgical outcomes.

Keywords: Gallbladder carcinosarcoma

Introduction

Carcinosarcoma is a tumor characterized by malignant epithelial and mesenchymal elements. The carcinosarcoma in many different organs such as esophagus, kidney, uterus, lung, pancreas is well known [1, 2]; However, carcinosarcomas of the gallbladder are rare. Due to the rarity, the diagnosis of this tumor is difficult by the ultrasound or the computed tomography scan. To date, 50 cases have been reported in the English literature. Here, we report another case of gallbladder carcinosarcoma treated by cholecystostomy.

Case report

A 68-year-old female patient presented with a 5 days' history of severe pain in the right hypochondrium, accompanied by nausea and vomiting. The patient denied anorexia, weight loss, comorbidities, smoking, or previous surgery, but she reported a 2 years' history of cholelithiasis. Clinical examinations revealed a body temperature of 38.2°C and an immovable, mass, flat, painful, approximately 7×11 cm diameter in the right upper quadrant of the abdomen. Laboratory test showed haemoglo-

bin of 88 g/L, a normal leukocyte count. The tumor marker, serum carcinoembryonic antigen and α -fetoprotein (AFP) levels were normal, but the carbohydrate antigen 19-9 was mildly elevated (90 U/ml). Ultrasound Abdomen and Magnetic resonance imaging (MRI) showed a huge space-occupying and irregular wall thickening with enhancement of the body of the gallbladder (**Figure 1**). Cholecystostomy was carried out under the preoperative diagnosis of chronic cholecystitis and tumor of the gallbladder. During the surgery, the frozen examination revealed that it was a malignant mesenchymal tumor. The tumor had already infiltrated to the ligamentum hepatoduodenale, hepatic flexure of colon, part of the transverse mesocolon, liver first port. The specimens were sent for histopathology. Grossly, the tumor exhibited a 16×15×13 cm solid mass with hemorrhagic and necrotic changes, which originated from the body of the gallbladder and filled the entire gallbladder lumen. Histology revealed fragments of gallbladder tissue displaying infiltrating tumor composed mainly of moderately-differentiated tubular adenocarcinoma and sarcomatous tissue with fibroid differentiation (**Figure 2**). An immunohistochemical examination demonstrated negative staining for cyto-

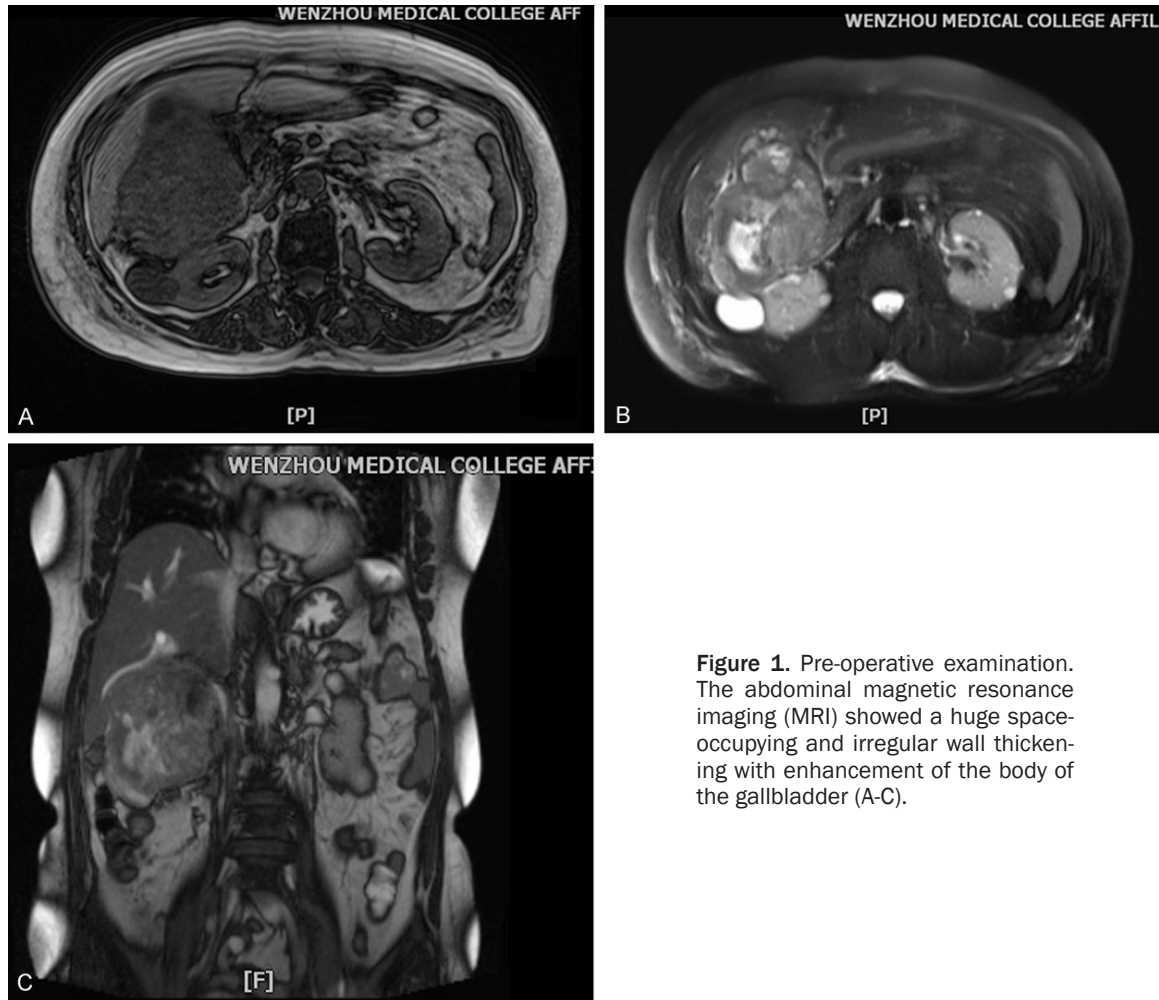


Figure 1. Pre-operative examination. The abdominal magnetic resonance imaging (MRI) showed a huge space-occupying and irregular wall thickening with enhancement of the body of the gallbladder (A-C).

keratin, CK5/6, CK7 and P63 of the sarcomatous component. The patient died one month after surgery.

Discussion

Among the malignant gallbladder neoplasms, gallbladder carcinosarcoma is extremely rare with an incidence of less than one percent. Since Landsteiner et al published first case of gallbladder carcinosarcoma in 1907 [3], there have been more than 50 cases reported in English literature in the PubMed. Carcinosarcoma is characterized by two intermingled epithelial and mesenchymal components of the same tissue. The epithelial component usually consists of adenocarcinoma, although a squamous cell carcinoma component may often be present. The mesenchymal component typically consists of undifferentiated spindle or satellite cells, and is occasionally

accompanied by various proportions of heterogeneous elements, including chondrosarcoma, osteosarcoma, rhabdomyosarcoma and leiomyosarcoma [4, 5]. In the present case, the carcinosarcoma consists of moderately-differentiated adenocarcinoma and sarcomatous tissue with spindle cells. Extensive sampling and diligent search revealed the elements of fibrosarcoma leading to a diagnosis of carcinosarcoma.

Due to their rarity, the histogenesis and natural history of carcinosarcoma is unclear. It has been speculated that these neoplasms arise from totipotent stem cells, that subsequently develops divergent differentiation along separate epithelial and mesenchymal pathways [6]. Exact tumorigenesis mechanism of gallbladder carcinosarcoma is still unknown. One study [7] indicated that certain genetic and gene expression alterations may be relevant to

Gallbladder carcinosarcoma with cholecystolithiasis

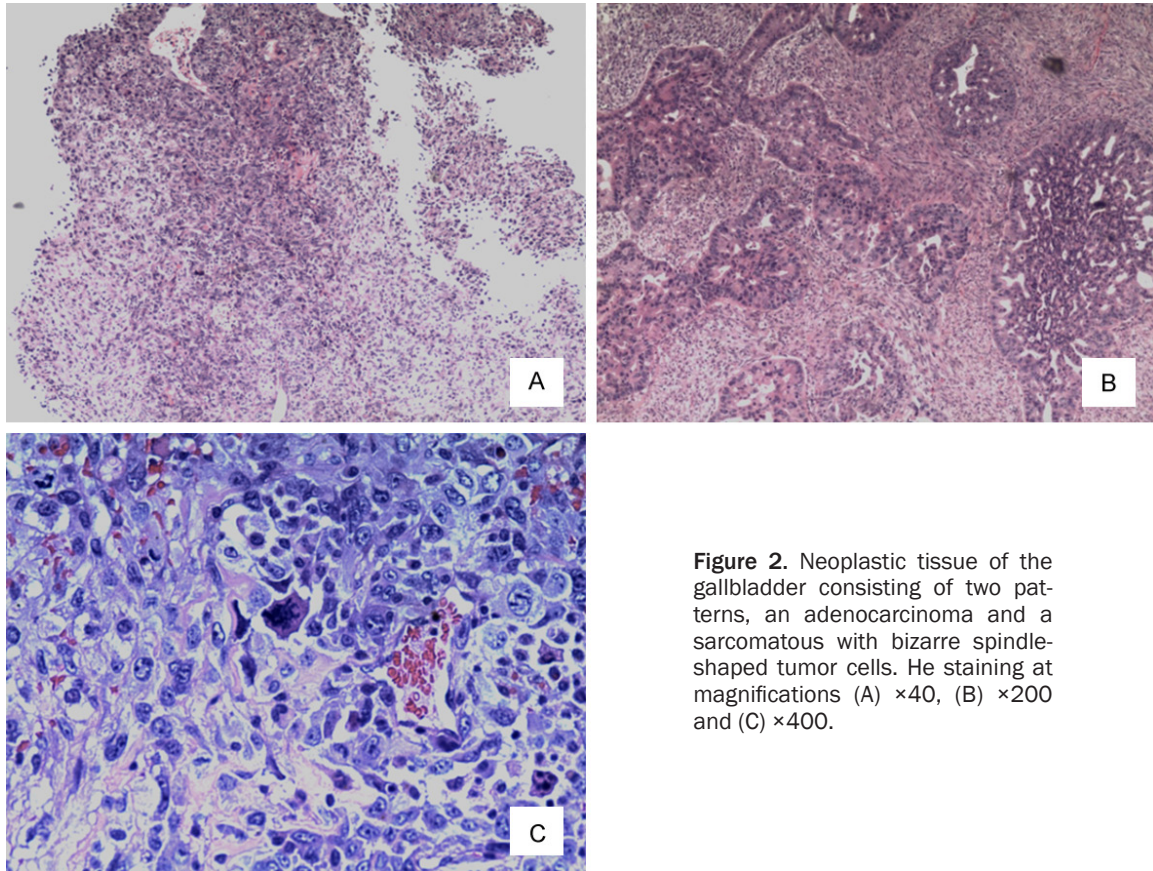


Figure 2. Neoplastic tissue of the gallbladder consisting of two patterns, an adenocarcinoma and a sarcomatous with bizarre spindle-shaped tumor cells. He staining at magnifications (A) $\times 40$, (B) $\times 200$ and (C) $\times 400$.

the sarcomatous change epithelial mesenchymal transition in cholangio carcinoma cells. Another report [8] further linked K-Ras alterations with disrupted cell cycle regulation and gallbladder carcinogenesis. Thus more large series of cases and microdissection-based genotypic analyses must be performed to elucidate the precise mechanism.

The symptoms and signs of gallbladder carcinosarcoma are non-specific. Patients with gallbladder carcinosarcoma often present with vague abdominal symptoms, such as dull abdominal pain, nausea, jaundice and weight loss. Occasionally, there is a palpable right upper quadrant mass. At laparotomy, most patients have locally advanced disease involving the gallbladder bed or distant metastasis. About 74% of the gallbladder carcinosarcoma cases are associated with cholecystolithiasis [9, 10]. In our case, the patient complained a 2 years history of cholelithiasis and acute pain in the right hypochondrium which is consistent to the cases reported before.

The preoperative diagnosis of carcinosarcoma is difficult because imaging studies, such as,

ultrasonography, CT, and abdominal angiography cannot differentiate it from carcinoma of the gall bladder. An abdominal angiography often shows neovascularity and staining of, where as Computed Tomography (CT) shows an enhanced solid mass lesion. Tumor markers such as AFP, CEA, CA125 are also non-specific [11, 12], but Serum CA19.9 level also may be elevated. The accurate diagnosis of this tumor must be confirmed by pathological examination that the tissue of the tumor require the presence of both malignant and mesenchymal elements. An immunohistochemical examination should show that the epithelial component is positive for cytokeratin, while the mesenchymal component is positive for vimentin.

Therapeutic interventions have not been well defined and no optimal postoperative adjuvant therapy, such as, chemotherapy and radiation therapy, has been established because of the rarity of gallbladder carcinosarcoma and its poor prognosis. The treatment of this disease is the same as that of other gallbladder cancer. To our knowledge, the best treatment option is surgery. Cholecystectomy alone is sufficient for

cancer cells confined to the lamina propria, whereas more advanced states require resection of a 3 to 5 cm wedge of liver tissue at the gallbladder bed, combined with LN dissection in the absence of evidence of distant metastasis.

The prognosis of this disease is normally poor. A recent review reported that the overall 3-year survival rates of gallbladder carcinosarcomas after resection were 31.0%. And the mean survival of carcinosarcoma was 17.5 months. To our knowledge, most cases present with locally advanced disease. Liver metastasis and peritoneal dissemination are common in these cases. The adrenal glands, pancreas, diaphragm, and lower thoracic vertebrae are other reported metastatic sites. The regional, retroperitoneal, and para-aortic lymph nodes may be involved. In our case, the tumor invades to the adjacent area such as hepatic flexure of colon, part of the transverse mesocolon and died 1 month after discharge. The prognosis is affected by many factors. Zhang et al [13] reported that tumors which were smaller than 5 cm had a longer survival and that therefore, the tumor size should be considered as a major component in the future staging system. They also indicated that the presence of gallstones, epithelial and mesenchymal component types, age and sex were of little prognostic value.

Disclosure of conflict of interest

None.

Address correspondence to: Dr. Qiyu Zhang, Department of Hepatobiliary Surgery, The First Affiliated Hospital of Wenzhou Medical University, Wenzhou 325000, Zhejiang, P. R. China. E-mail: qiyuzhwmu@163.com (QYZ); huweijian0825@163.com (WJH)

References

- [1] Jonson AL, Bliss RL, Truskinovsky A, Judson P, Argenta P, Carson L, Dusenbery K and Downs LS Jr. Clinical features and outcomes of uterine and ovarian carcinosarcoma. *Gynecol Oncol* 2006; 100: 561-564.
- [2] Batsakis JG and Suarez P. Sarcomatoid carcinomas of the upper aerodigestive tracts. *Adv Anat Pathol* 2000; 7: 282-293.
- [3] K L. Plattenepithenelkarzinom und sarkom der gallenblase in einem falle von gallenblase. *Ztschr Klin Med* 1907; 62: 427-433.
- [4] Takahashi Y, Fukushima J, Fukusato T and Shiga J. Sarcomatoid carcinoma with components of small cell carcinoma and undifferentiated carcinoma of the gallbladder. *Pathol Int* 2004; 54: 866-871.
- [5] Kim MJ, Yu E and Ro JY. Sarcomatoid carcinoma of the gallbladder with a rhabdoid tumor component. *Arch Pathol Lab Med* 2003; 127: e406-408.
- [6] Uzun MA, Koksall N, Gunerhan Y, Celik A and Gunes P. Carcinosarcoma of the gallbladder: report of a case. *Surg Today* 2009; 39: 168-171.
- [7] Yoo HJ, Yun BR, Kwon JH, Ahn HS, Seol MA, Lee MJ, Yu GR, Yu HC, Hong B, Choi K and Kim DG. Genetic and expression alterations in association with the sarcomatous change of cholangiocarcinoma cells. *Exp Mol Med* 2009; 41: 102-115.
- [8] Kuroki T, Tajima Y, Matsuo K and Kanematsu T. Genetic alterations in gallbladder carcinoma. *Surg Today* 2005; 35: 101-105.
- [9] Lazcano-Ponce EC, Miquel JF, Munoz N, Herrero R, Ferrecio C, Wistuba II, Alonso de Ruiz P, Aristi Urista G and Nervi F. Epidemiology and molecular pathology of gallbladder cancer. *CA Cancer J Clin* 2001; 51: 349-364.
- [10] Nimura Y. Extended surgery in bilio-pancreatic cancer: the Japanese experience. *Semin Oncol* 2002; 29: 17-22.
- [11] Okabayashi T, Sun ZL, Montgomey RA and Hanazaki K. Surgical outcome of carcinosarcoma of the gall bladder: a review. *World J Gastroenterol* 2009; 15: 4877-4882.
- [12] Huguet KL, Hughes CB and Hewitt WR. Gallbladder carcinosarcoma: a case report and literature review. *J Gastrointest Surg* 2005; 9: 818-821.
- [13] Zhang L, Chen Z, Fukuma M, Lee LY and Wu M. Prognostic significance of race and tumor size in carcinosarcoma of gallbladder: a meta-analysis of 68 cases. *Int J Clin Exp Pathol* 2008; 1: 75-83.