

Case Report

Primary chondrosarcoma of the prostate: a case report

Zhen He^{1,2*}, Nan Sha^{1,2*}, Shi-Yong Qi^{1,2}, Bing Zhu¹, Chao Lu^{1,2}, Meng Zhang^{1,2}, Tong Yang^{1,2}, Yu-Zheng Wu^{1,2}, Bin Xie^{1,2}, Yong Xu^{1,2}

¹Department of Urology, Second Hospital of Tianjin Medical University, Tianjin, China; ²Tianjin Institute of Urology, Second Hospital of Tianjin Medical University, Tianjin, China. *Equal contributors.

Received November 4, 2015; Accepted January 1, 2016; Epub February 1, 2016; Published February 15, 2016

Abstract: Chondrosarcoma of the prostate is a rare variant of prostatic cancer. Tumors are most commonly composed of an admixture of both original mesenchymal cells and well-differentiated chondrocytes. It is a kind of highly malignant aggressive tumor, which is rich in blood vessels. A unique case of chondrosarcoma of the prostate detected in a 59-year-old man who underwent transurethral resection of the prostate (TURP) for the treatment of dysuria is presented. Pathology revealed that the resected prostatic mass consisted of malignant mesenchymal and chondrosarcomatous elements. The diagnosis of chondrosarcomatoid carcinoma was finally made. The patient visited the Department of Urology in our hospital in purpose of further evaluation. He received a combination of cutaneous ureterostomy and radiotherapy but the response to the treatment was unsuccessful. Unfortunately, the patient died of MODS two months after the surgery in our hospital.

Keywords: Prostate, chondrosarcomatoid carcinoma, immunohistochemistry

Introduction

Chondrosarcoma of the prostate, which originated from the prostatic mesenchymal tissues, is an extremely rare malignant tumor and appears to be a distinct entity, considering the clinical course, prognosis, and therapy [1]. Commonly, chondrosarcomas may appear in several parts of the body including bone and soft tissues, especially eye sockets. Herein, we report a case of a 59 years old man with prostate chondrosarcoma and discuss the clinical, diagnostic and therapeutic aspects of this uncommon tumor.

Case report

A 59-year-old man presented to local hospital with a chief complaint of a four-year history of progressive dysuria and frequent micturition. There was no family history of genitourinary cancer. Ultrasound examination performed in local hospital showed a cystic-solid mass of 6 cm in diameter located outside the right bladder walls and the size of the prostate was 59*65*61 mm, which was observed low echo nodules inside. Digital rectal examination

(DRE), computed tomography (CT) and magnetic resonance imaging (MRI) were not performed. His serum total prostate-specific antigen (tPSA) was 0.50 ng/ml (normal range, 0.0-4.0 ng/ml). Several days later, transurethral resection of the prostate (TURP) was performed in local hospital. Histopathological examination showed an admixture of both original mesenchymal cells and well-differentiated chondrocytes (**Figure 1**). Immunohistochemical studies showed cells to be sporadic positive for S117 protein. Due to the unexpected findings of the pathology report, the patient visited the Department of Urology in our hospital in purpose of further evaluation. In our hospital, DRE revealed a moderately hard normal prostate gland, no nodular mass in both lobes of the prostate. Bone metastases were assessed with whole-body bone scan (WBBS) and considered negative. Chest CT scans showed nodular shadows in both lungs (**Figure 2**). MRI of the prostate gland revealed a focal nodule (38 mm) located in the pelvic cavity compressing and displacing the right bladder wall and the prostate extended to the bladder and seminal vesicle. A provisional diagnosis of prostate malignant tumor with bladder and seminal vesicle invasion and pelvic lymph node

Primary chondrosarcoma of the prostate

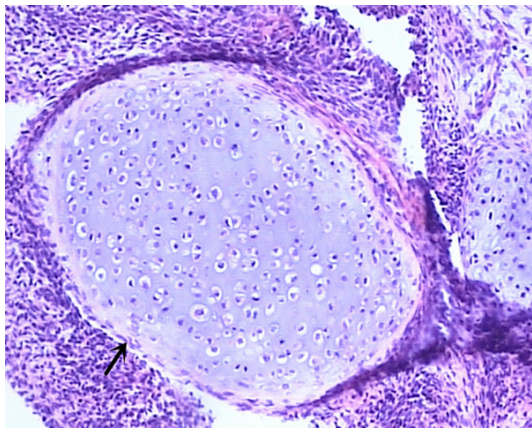


Figure 1. Histological findings of prostate cancer (H&E staining of tissue section showed an admixture of both original mesenchymal cells and well-differentiated chondrocytes, magnification: $\times 100$).

metastasis was made (**Figure 3**). Then the patient was scheduled for a radical cystoprostatectomy, cutaneous ureterostomy and pelvic lymphadenectomy. At surgery, the prostate and lymph nodes are fixed to the pubis and lateral pelvic walls. Because of poor mobility and different separation, we immediately changed to perform cutaneous ureterostomy only. So, we did not get the histological specimens to evaluate pathology results again. During postoperative days, the patient began to appear unexpected clinical symptoms, such as bloody effusion from the urethra with stench; urethra and right hip bone pain. 80 mg parecoxib sodium was administered daily intravenously to relieve pain symptoms. After consulting with radiation therapists, pelvic local palliative radiotherapy was given to ease symptoms and improve the survival quality of this patient after the wound healed. However, symptom relief is not obvious after days of radiotherapy. Although patient was advised to continue to undergo symptomatic treatment, the patients and families denied any intervention and discharge home. The patient died of multiple organ dysfunction syndrome (MODS) two months after the operation in our hospital.

Discussion

Sarcomas, which are uncommon and highly aggressive malignant tumors that contain epithelial and sarcomatous elements, account for less than 0.1% of all prostatic malignancies and usually develop in the younger age group

[2, 3]. It is generally acknowledged that sarcomas derive from mesodermic cells and evolve to various sorts of sarcomas after varying degrees of differentiation. Cartilaginous metaplasia is known to occur in the prostate and a case of prostatic chondroma reported by Sloan probably arising from such metaplasia [4]. It is a rare tumor.

Preoperative physical and radiologic examinations play a vital role in the diagnosis of a prostate tumor. On DRE the prostate is bony, nodular and hard in most of the reported cases [5]. It has great value to the early diagnosis of prostate cancer. Pelvic CT scans can demonstrate locally aggressive prostatic tumors. However, MR provides a more accurate preoperative diagnosis than CT when imaging the soft tissue tumors; it can better demonstrate invasion of the pelvic organs and internal architecture of the tumor. The typical features of carcinosarcoma of the prostate imaged on MRI include heterogeneous hypointense masses with cystic changes within the tumor on T2-weighted images and marked enhancement with necrotic areas on contrast-enhanced T1-weighted ones [6]. As imaging findings are not specific, ultrasound-guided transrectal needle biopsy of the prostate is often suggested to confirm the disease. In our case, the patient underwent TURP without performing DRE, CT or MRI to access the patient's condition adequately in local hospital. Although his serum tPSA was normal, pathological diagnosis results were opposite to preoperative clinical diagnosis. Thus, preoperative prostatic examination, such as DRE and MRI are needed whether the serum tPSA is normal or not.

Carcinosarcoma of the prostate is an aggressive malignancy which spreads by adjacent organ direct invasion and distant metastasis, especially lung and liver metastasis [7]. Due to the limited experience, there are no standard treatment recommendations. Therefore, an extended resection such as a radical prostatectomy or a radical cystoprostatectomy is suggested, which may be followed by radiation therapy and/or adjuvant chemo therapy, particularly in patients with lymphatic metastasis. But there are no advantages in terms of postoperative survive [1, 5, 8]. In the current case, our patient received a combination of cutaneous ureterostomy and radiotherapy in our hospital, but the response to the treatment was

Primary chondrosarcoma of the prostate

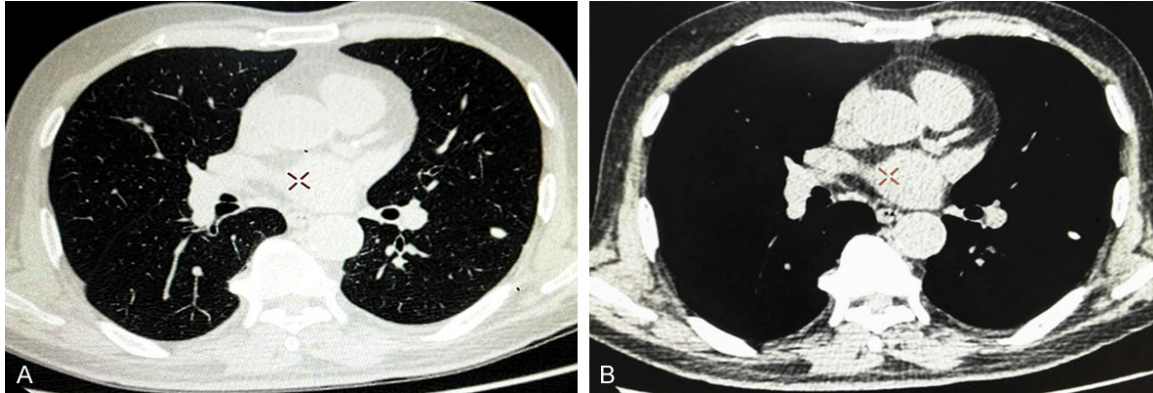


Figure 2. CT findings of pulmonary metastasis. Chest CT revealed nodular shadows in both lungs (A: Lung window image; B: Mediastinal window image).

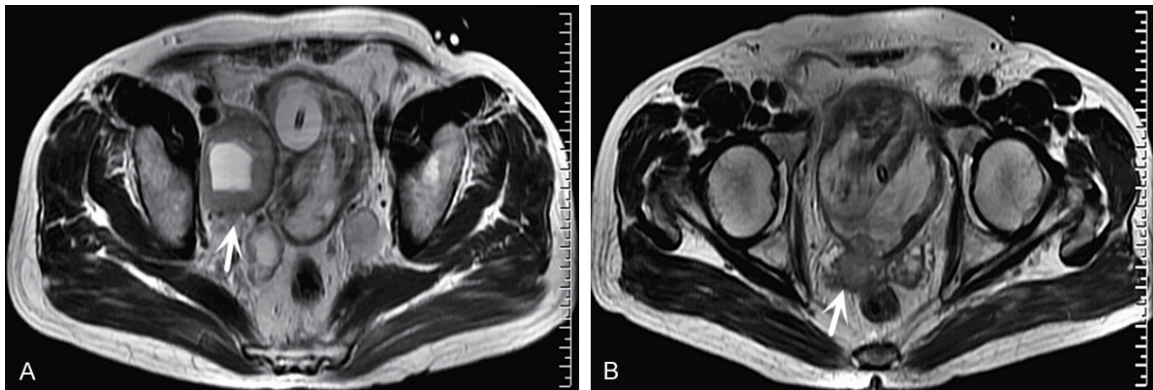


Figure 3. MRI of the prostate gland revealed a focal nodule located in the pelvic cavity compressing and displacing the right bladder wall (A) and the prostate invaded the bladder and seminal vesicle (B).

unsuccessful. Unfortunately, the patient died of MODS two months after the surgery in our hospital.

Definitive diagnosis of chondrosarcoma is based on the histological analysis with partial or mass resection. The carcinomatous and chondrosarcomatous components are mixed, with blending of the two in some areas [5]. The chondrosarcomatous area showed a positive staining for S-100 in immunohistochemical investigations [1].

Patients with chondrosarcoma have poor prognosis, with a 20% mortality rate during one year of diagnosis [5]. In our case, the patient died of MODS two months after the operation in our hospital.

In conclusion, we reported an extremely rare case of primary chondrosarcoma of the prostate. Preoperative physical and imaging exami-

nations are helpful to diagnosis. Definitive diagnosis is based on histological and immunohistochemical analysis of biopsy specimens. The prognosis of patients with chondrosarcomas of the prostate is poor.

Acknowledgements

This work is funded by grants from the National Natural Science Foundation of China (8147-2416).

Disclosure of conflict of interest

None.

Address correspondence to: Dr. Yong Xu, Department of Urology, Second Hospital of Tianjin Medical University, Tianjin Institute of Urology, 23 Pingjiang Road, Tianjin 300211, China. Tel: +86-22-88328695; E-mail: Drxuyong@126.com

Primary chondrosarcoma of the prostate

References

- [1] Fukawa T, Numata K, Yamanaka M, Miyamoto T, Kurokawa Y, Kanayama HO, Kagawa S, Utsunomiya M, Hirokawa M. Prostatic carcinosarcoma: a case report and review of literature. *Int J Urol* 2003; 10: 108-13.
- [2] Raines SL, Maddux HB. Sarcoma of the prostate: a review of the literature and case report. *Urol Cutaneous Rev* 1950; 54: 283-7.
- [3] Nazeer T, Barada JH, Fisher HA, Ross JS. Prostatic carcinosarcoma: case report and review of literature. *J Urol* 1991; 146: 1370-3.
- [4] Sloan SE, Rapoport JM. Prostatic chondroma. *Urology* 1985; 25: 319-21.
- [5] Hansel DE, Epstein JI. Sarcomatoid carcinoma of the prostate: a study of 42 cases. *Am J Surg Pathol* 2006; 30: 1316-21.
- [6] Goto T, Maeshima A, Oyamada Y, Kato R. Solitary pulmonary metastasis from prostate sarcomatoid cancer. *World J Surg Oncol* 2010; 8: 101.
- [7] Chang JM, Lee HJ, Lee SE, Byun SS, Choe GY, Kim SH, Seong CK, Kim SH. Pictorial review: Unusual tumours involving the prostate: radiological-pathological findings. *Br J Radiol* 2008; 81: 907-15.
- [8] McGee SM, Boorjian SA, Karnes RJ. Carcinosarcoma of the prostate replacing the entire lower genitourinary tract. *Urology* 2009; 74: 540-1.