

Case Report

Angiosarcoma initially presented as repeated shedding tonsil neoplasm: a case report and literature review

Jisheng Li^{1*}, Minghao Li^{2*}, Xiaofang Zhang³, Yuekai Li⁴, Hua Geng⁵, Xiaolan Cai⁶, Xiangling Wang¹, Ming Li¹, Limei Sun¹, Fengping Qin¹, Xuejun Yu¹

¹Department of Medical Oncology, Cancer Center, Qilu Hospital of Shandong University, Jinan, PR China; ²School of Medicine, Shandong University, Jinan, PR China; ³Department of Pathology, Qilu Hospital of Shandong University, Jinan, PR China; ⁴Department of Nuclear Medicine, Qilu Hospital of Shandong University, Jinan, PR China; ⁵Research Center of Basic Medical Sciences, Tianjin Medical University, Tianjin, PR China; ⁶Department of Otorhinolaryngology, Qilu Hospital of Shandong University, Jinan, PR China. *Equal contributors.

Received December 3, 2015; Accepted February 13, 2016; Epub April 1, 2016; Published April 15, 2016

Abstract: Background: Angiosarcomas are rare malignant vascular tumors composed of several clinical subtypes and collectively have a poor prognosis especially with metastases. They can involve any soft-tissue structures or viscera and commonly present in the head and neck anatomical region. However, both primary and metastatic angiosarcomas in tonsil are extremely rare. Herein we reported a peculiar case of diffused metastatic angiosarcoma initially presented as a repeated shedding tonsil neoplasm. Case presentation: A 45-year-old Chinese man without history of cancers or radiation in the head and neck region presented with a left tonsil neoplasm which enlarged progressively. And shortly pieces of necrotic tissues began repeatedly shedding from the tonsil neoplasm. About 2 months later he gradually presented with systematic symptoms including fever and dyspnea. Twice tissue biopsy for the tonsil neoplasms in local hospital failed to prove malignant disease with preliminary pathological diagnosis of necrosis and chronic inflammation. In our hospital, functional imaging with PET-CT supported a diffused metastatic disease status involving left tonsil, right atrium, mediastinum, and multiple bones. Further deep tissue biopsy and histopathology analysis revealed tonsil angiosarcoma with strong positive immunohistochemical staining for CD31 and CD34. Then the patient received two cycles of chemotherapy with paclitaxel plus cisplatin regimen and following efficacy evaluation revealed stable disease (SD). However, the patient gave up subsequent anti-cancer treatment due to personal choice and died 6 months after diagnosis due to progression of metastatic angiosarcoma. Conclusion: We described a unique case of diffused metastatic angiosarcoma involving tonsil in which diagnosis was not achieved until the third biopsy. Although we can't fully exclude the possibility that the tonsil angiosarcoma could be metastasized from a potential heart or bone primary site, this case was still extraordinarily peculiar because of both its rarity and unique initial presentation as a repeated shedding tonsil neoplasm. We have also presented a review of published reports concerning its rare incidence.

Keywords: Angiosarcoma, head and neck, metastasis, pathology, tonsil

Introduction

Angiosarcomas are a rare subtype of soft tissue sarcoma of vascular or lymphatic endothelial cell origin with aggressive behavior [1]. It's estimated that about 2% of soft tissue sarcomas and 5.4% of cutaneous soft tissue sarcomas are angiosarcomas [2, 3]. The term hemangioendothelioma indicates vascular tumors of intermediate malignancy while angiosarcoma indicates high-grade neoplasm. Most angiosarcomas arise spontaneously while some cases are associated with radiation and chronic lymphedema [1].

Treatment is challenging in many angiosarcoma cases and prognosis is relatively poor, however, antiangiogenic therapies could offer some hope for an effective angiosarcoma specific treatment in future [1].

Based on its clinical behavior, angiosarcoma could be classified into following subtypes: cutaneous angiosarcoma, lymphoedema-associated angiosarcoma, radiation-induced angiosarcoma, primary-breast angiosarcoma, and soft-tissue angiosarcoma [4]. It develops from vascular or lymphatic endothelial cells and can

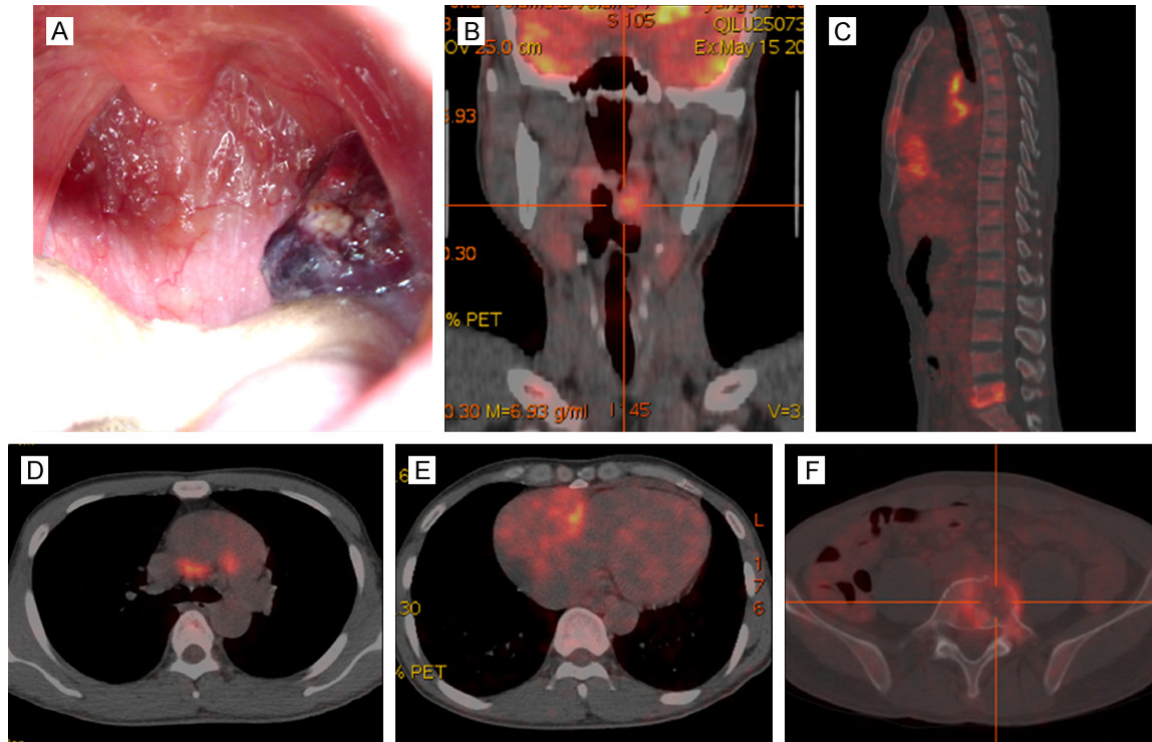


Figure 1. The left tonsil angiosarcoma presented as a dark red neoplasm of about 3 cm×3 cm×2 cm in its primary focus with small spots of caseous necrosis scattered in its surface (A). Using positron emission tomography-computed tomography (PET-CT), this malignant disease were detected by elevated standard uptake values (SUVs) in left tonsil (B), mediastinum masses (C, D), right atrium masses (maximum 4.6, average 2.4; C and E), and multiple bones (sternum and lumbar vertebra as examples, C, F).

involve any soft-tissue structure or viscera such as head and neck, breast, liver, heart, spleen and bone [5-9]. Although angiosarcomas originated in head and neck region represent about 27% of all angiosarcomas, they only account less than 0.1% of all head and neck malignancies [10]. Angiosarcomas in tonsil, either primary or metastatic, are ever rarer and only occasionally seen in case reports.

In the present report, we described a unique case of diffused metastatic angiosarcoma involving tonsil, heart, mediastinum and bones. Diagnosis for this case was challenging and not achieved until the third biopsy. Although we could not fully exclude the possibility that the tonsil angiosarcoma could be metastasized from a potential heart or bone primary site, this case was still extraordinary peculiar and interesting because of both its rarity and unique initial presentation as a repeated shedding tonsil neoplasm. We have also presented a review of published reports concerning its rare incidence.

Case presentation

A 45-year-old Chinese man without any history of cancers or radiation in the head and neck area presented with a swollen left tonsil after a cold. The tonsil swelling enlarged progressively and shortly pieces of dark red tissues began to repeatedly shedding from his left tonsil, which caused bloody sputum and even obvious tonsil bleeding occasionally. About two months later after the presence of tonsil neoplasm, the patient gradually presented with other systematic symptoms including fever, cough, dyspnea and weight loss of about 3 kilograms. Contrast-enhanced computerized tomography (CT) for neck, chest and abdomen in local hospital revealed a left tonsil neoplasm accompanied with pericardium, mediastinum and liver mass as well as pericardial effusion, which suggested a malignant disease with extensive metastases. Biopsy for the tonsil neoplasm was performed twice in local hospital but pathological analyses failed to reveal malignant disease in this case with preliminary pathological diagno-

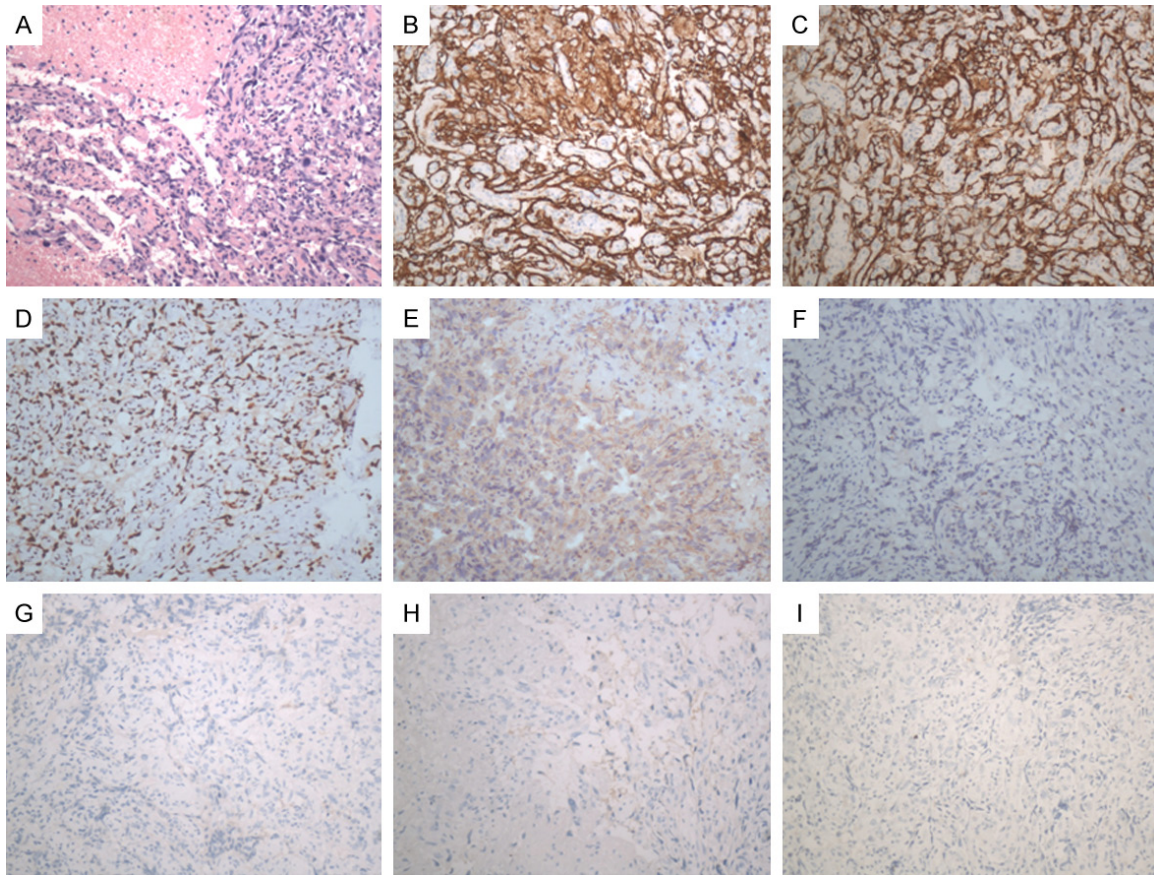


Figure 2. Histopathology and immunohistochemical staining results confirmed the diagnosis of angiosarcoma. Haematoxylin and eosin staining of section of the angiosarcoma showed pleomorphic spindle endothelial cells with large hyperchromatic nuclei and the distinct vasoformative areas filled with red blood cells (A, HE 200×). Immunostaining showed strong staining for CD31 (B, 200×) and CD34 (C, 200×), moderate staining for FLI1 (D, 200×) and Vimentin (E, 200×), but negative for S-100 (F, 200×), DOG1 (G, 200×), CR (H, 200×) and MC (I, 200×).

sis of necrosis and chronic inflammation in tonsil. The patient was then referred to our hospital for further diagnosis and treatment.

In our hospital, physical examination revealed a left tonsil mass of about 3 cm×2 cm with the color of dark red and small areas of caseous necrosis scattered in the surface of the tonsil neoplasm (**Figure 1A**). No enlarged lymph nodes were found in the head and neck region or the supraclavicular region. A preliminary diagnosis of metastatic malignant disease was made based on the medical history and disease presentation. Then positron emission tomography-computed tomography (PET-CT) was arranged for the patient and detected elevated standard uptake values (SUVs) in the left tonsil (maximum 3.7, average 2.2; **Figure 1B**), right atrium mass (maximum 4.6, average 2.4; **Figure 1C** and **1E**), mediastinum masses (maxi-

mum 3.6-5.7, average 2.2-3.6; **Figure 1C** and **1D**), and multiple bones (maximum 1.3-4.4, average 0.6-2.5; **Figure 1C** and **1F**) in addition to mild pericardial effusion. Cardiac ultrasound revealed a 4 cm×3 cm mass in the lateral wall of right atrium and mild pericardial effusion with a left ventricular ejection fraction of 0.75.

Multiple discipline teams (MDT) discussion involving otorhinolaryngology surgeon was arranged for this case and consensus was made that a metastatic malignant disease was preferentially considered and further tonsil biopsy was strongly recommended. The fact that pieces of tissues frequently shed from the neoplasm suggested that the tonsil malignancy grew very fast and the surface tissue might be necrotic and had lost typical malignant pathological characteristics. Previous two biopsies in local hospital might be too superficial to collect

typical cancerous tissues probably for fear of causing severe bleeding, thus a deep tissue biopsy by an experienced otorhinolaryngology surgeon was arranged for this case. Deep tonsillar tissue biopsy was performed and histopathology analysis revealed angiosarcoma. Microscopically, multiple sections showed a malignancy comprising tumor cells arranged in a vasoformative growth pattern with complex anastomosing channels, which was consistent with typical angiosarcoma histological findings. The immunohistochemical results showed that tumor cells were stained positive for CD31, CD34, FLI-1, Vimentin and Ki67 (approximately 10%) but negative for S-100, DOG1, MC and CR (**Figure 2**), supporting the diagnosis of angiosarcoma.

Based on the fact that this patient initially presented with an enlarging tonsil neoplasm with repeated tissue shedding and didn't present with systematic symptoms until two months later, we tend to consider this case as a metastatic angiosarcoma with tonsil primary. However, based on the limited previous medical history, accessible imaging study results and biopsy pathology, we cannot exclude the possibility that the tonsil angiosarcoma could be metastatic from a potential heart or bone primary site. But it's quite important to notice the unique initial disease presentation as repeated shedding tonsil neoplasm for this case in addition to its rarity.

Due to the diverse metastatic disease status, systematic chemotherapy was recommended as the initial treatment modality for this patient after a MDT discussion. The patient received two cycles of chemotherapy with paclitaxel plus cisplatin regimen accompanied with diphosphonate which he tolerated well. Following efficacy evaluation after two cycles of chemotherapy suggested stable disease (SD). The patient gave up subsequent anti-cancer treatment due to personal choice and died 6 months after diagnosis due to progression of metastatic angiosarcoma.

Discussion

Angiosarcoma is also known as malignant hemangioendothelioma, angioblastoma, hemangiosarcoma and intravascular endothelioma. As histologic high-grade tumors arising from vessels, angiosarcomas are no longer sub-

grouped into lymphangiosarcomas and hemangiosarcomas [11]. According to the latest WHO classification of soft tissue tumors, malignant vascular tumors include epithelioid hemangioendotheliomas and angiosarcomas of soft tissue [12]. A study of the distribution of angiosarcoma with pooled data from 534 patients suggests that commonly affected anatomical sites include head and neck (27.0%), breast (19.7%), extremities (15.3%), trunk (9.5%), liver (6.0%), heart (4.7%), bone (3.6%), spleen (2.6%) and other (or unknown) (11.6%) [1]. About thirty percent angiosarcomas patients present with metastases and common metastases involve lung (28.8%), bone (21.2%), liver (9.2%) and lymph node (18.1%) [5, 13, 14]. Prognosis for this rare disease of high malignancy is relatively poor. Soft-tissue sarcomas are associated with a 5-year survival rate of 50-60% [15], but angiosarcomas only have a 5-year survival rate of about 40% [6, 7, 16].

Sarcomas are rare in the head and neck region and most malignancy in this anatomical region are squamous cell carcinomas [17]. Although about 60% of cutaneous angiosarcomas arise in the skin of head and neck region, non-cutaneous sarcomas of the head and neck are exceptionally rare, accounting for approximately 4% to 10% of all sarcomas and less than 1% of all head and neck malignancies [17]. Within head and neck region, angiosarcomas originated in the oral cavity area are much rarer. In 2014, M. Nagata *et al.* reported three cases of intraoral angiosarcoma and summarized reports of primary oral angiosarcomas since 1998 [18]. Among the 15 cases of oral angiosarcoma, the common locations involved gingiva, hard palate, buccal mucosa and tongue. Clinically, they were usually presented as painful, spontaneously bleeding, round or ovoid nodules with rapid onset and invasion of adjacent tissues [18]. The oral region is not easy for metastatic tumor to colonize [19]. The oral cavity metastases of angiosarcoma have been reported for limited times with about half of them in gingiva [20-26]. Compared to oral cavity, the reports of angiosarcoma in tonsil are even scarcer.

Tonsil sarcomas constitute a rare entity in tonsillar neoplasms and are only described in some case reports. The common primary tonsillar neoplasms include lymphomas and squa-

Angiosarcoma presented as repeated shedding tonsil neoplasm

Table 1. Summary of six reported angiosarcoma cases involving tonsil

Publication year	Diagnosis	Age (year)	Gender	Primary site	Metastases	Survival time	Treatment	IHC Results
Present case	Metastatic angiosarcoma	51	Male	Unknown	Tonsil, right atrium, mediastinum, bones	6 months	Chemotherapy (paclitaxel plus cisplatin)	Positive: CD31, CD34; Negative: DOG1, MC and CR
2013 [54]	Cardiac angiosarcoma	37	Male	Heart	Both lungs, tonsil, duodenum	About 3 weeks	No treatment	N.A.
2012 [51]	Epithelioid tonsil angiosarcoma	71	Female	Tonsil	Buccal mucosa, duodenum, small bowel, uvula	>9 months	Surgery, radiation therapy (70 Gy), chemotherapy (taxol)	Positive: KL-1, Lu5, cytokeratin (8, 18, 19), vimentin, CD31, ERG, FLI-1; Negative: CK5, 34βE12, cytokeratin 7, 13, 20
2012 [55]	Multifocal laryngeal angiosarcoma	83	Female	Epiglottis and base of tongue	Tonsil, pharynx	About 18 months	Surgery, adjuvant chemotherapy (taxotere)	Positive: CD31, CD34; Negative: P63, CAM5.2, FVIII-RAg, cytokeratin AE1/AE3, CK903
2011 [53]	Primary breast heman-giosarcoma	54	Female	Breast	Tonsil, chest wall, submandibular lymph node, supraclavicular lymph node, foramen magnum	>7 months	Tonsillectomy, therapeutic embolization	Positive: CD31, CD34; Negative: HMG-45 and S-100
1952 [74]	Lymphangiosarcoma	54	Female	Arm	Both tonsils, lungs, bones	>8 months	Amputation	Not performed

IHC: Immunohistochemistry; FLI-1: Freundleukemia integration site 1; FVIII-RAg: factor VIII-related antigen; HMG: High-molecular weight cytokeratins; N.A.: not available.

mous cell carcinomas. Meanwhile, tonsil is neither a commonly affected anatomical site for metastatic neoplasms. Reported primary malignancy include rectal adenocarcinoma [27-29], melanoma [30-33], renal cell carcinoma [34, 35], breast malignant phyllodes tumor [36], endometrial adenocarcinoma [37], seminoma [38], small cell lung cancer [39-41], and small cell neuroendocrine carcinoma [42]. In 2014, Rokkjaer *et al.* reviewed the prevalence of malignant tumors detected in routine tonsillectomy specimens and found that only 11 out of 72,322 (0.015%) patients had malignancy [43]. Reported sarcoma subtypes detected in tonsil include follicular dendritic cell sarcoma [44, 45], primary monophasic synovial sarcoma [46], interdigitating dendritic cell sarcoma [47] and Kaposi's sarcoma [48-50], in addition to limited case of angiosarcoma.

Thorough literature searches were performed in MEDLINE, Web of Science and Google Scholar using keywords of “tonsil” and “angiosarcoma” with proper search strategy and to the best of our knowledge, totally five cases of tonsil angiosarcoma has been detailedly reported in English literatures. The related literature and clinical information including the present case have been summarized in **Table 1**. Actually only one of the five cases is primary tonsil angiosarcoma while the other four cases are all metastatic tonsil angiosarcoma. The case reported by Agaimy *et al.* in 2012 might be the first reported primary angiosarcoma of tonsil [51]. The patient was a 71-year-old woman without history of malignancy or radiation to the head and neck. She was treated with tonsillectomy for the refractory tonsil symptom of diffuse painful swelling and the histologic and immunohistochemical findings proved angiosarcoma. Except its rarity, another diagnostic challenge lied on the strong expression of cytokeratin in this case. This kind of pitfall has also been reported in other epithelioid angiosarcomas [52]. Ronen *et al.* demonstrated the difficulty in the diagnosis of angiosarcoma which initially presented as tonsillar hemorrhage in their case report [53]. In this case, the 54-year old female patient showed abrupt and massive tonsillar hemorrhage and the true diagnosis was made until obtaining the immunohistochemical results after bilateral tonsillectomy. Subsequent PET-CT demonstrated disseminated metastases in the chest wall, left

submandibular lymph node, supraclavicular lymph node, and right lobe of the liver. Compared to our cases, the patient has a history of high-grade breast angiosarcoma and this episode was proved to be the recurrence of her primary breast angiosarcoma. The earliest report we found, which was diagnosed as lymphangiosarcoma in arm, dated to 1952 and nowadays we no longer subdivide angiosarcomas into lymphangiosarcomas and hemangiosarcomas in diagnosis [11].

In this case, a female patient with post-mastectomy lymphedema presented with an ulcerating lesion of the dorsum of left arm which was proven to be lymphangiosarcoma and presented with metastasis in both tonsils, lungs and bones 8 months later. In addition to above 3 cases, a case of cardiac angiosarcoma metastasized to lung, tonsil and duodenum as well as another case of laryngeal angiosarcoma metastasized to tonsil and pharynx were also described in previous literature [54, 55].

In the present report, we described a unique case of diffused metastatic angiosarcoma involving tonsil, heart, mediastinum and bones. In addition to its rarity, the most particular feature is its initial presentation as an enlarging and repeated shedding tonsil neoplasm. At the time point of pathological diagnosis, the disease has already diversely metastasized and we cannot elucidate which anatomical site is the primary one because head and neck region, heart or bone are all common primary site for angiosarcoma. Neither could further pathological analysis help to clarify the primary site. But based on its unique initial presentation and the fact that the patient didn't present with systematic symptoms until two month later after the presence of tonsil neoplasm, we tent to consider this case as a metastatic angiosarcoma with tonsil as primary site, though neither could we fully exclude the possibility that the tonsil angiosarcoma might be metastasized from a potential heart or bone primary site.

Diagnosis for this case was also challenging and not achieved until the third biopsy. Based on the disease presentation and imaging study, a metastatic malignant disease was preferentially considered once the patient was referred to our hospital. However, previous two biopsies in local hospital failed to detect malignancy with only a preliminary pathological diagnosis

of necrosis and chronic inflammation. A quick enlarging and repeated shedding tonsil neoplasm suggested that the malignancy grew very fast and the surface tissue might be necrotic and have lost typical cancerous pathological characteristics. Further deep tissue biopsy by experienced otorhinolaryngology surgeon and histopathology analysis did successfully collect enough typical cancerous tissue which was proved to be angiosarcoma. MDT discussion and the involvement of experienced otorhinolaryngology surgeon played important role in the diagnosing process for this patient.

As mentioned earlier, neoplasms in tonsil are mostly lymphoma and squamous cell sarcoma with much fewer sarcoma especially angiosarcoma, which could be misdiagnosed because of their rarity. In histopathology, the pleomorphic malignant endothelial cells in angiosarcoma might appear polygonal or spindle shape with large hyperchromatic nuclei. In well or moderately differentiated area, distinct vascular channels or sinusoids with or without filled blood cells, often irregular in size and shape and surrounded by chronic inflammatory cells, are typical character for vascular neoplasms. In poorly differentiated angiosarcomas, the vascular architecture became more various and the cells more pleomorphic and mitotically active. The high grade epithelioid angiosarcomas might be histologically similar to anaplastic carcinoma or melanoma [1, 12, 56]. Given its various clinical characteristics and histologic features, immunohistochemistry is preferred to make a definite diagnosis by detecting the expressions of vascular molecule makers. The endothelial markers including CD31 (Platelet Endothelial Cell Adhesion Molecule-1), CD34 (Human Hematopoietic Progenitor Cell Antigen), Factor VIII-related antigen (FVIIIIRA), FLI1 (Friend leukemia integration 1 transcription factor) and Ulexeuropaeuslectin type 1 (UEA-1) are commonly used to verify the vascular origin of the neoplasm [57]. The membrane and cytoplasmic staining of CD31 is evidenced more sensitive and specific than CD34, though it dose express in macrophages and platelets [58]. Another highly specific maker is nuclear staining ERG (erythroblast transformation specific related gene), which could be independently more sensitive than conventional markers in some angiosarcomas [59, 60]. It is notable that in some cases, especially oral angiosarcomas,

the reactions for some non-specific markers, such as vimentin and pancytokeratins, might be misleading for diagnosis [18, 51, 52]. For the present case, multiple sections showed a malignancy with tumor cells in a vasoformative growth pattern with complex anastomosing channels, which were typical angiosarcoma histological findings. And tumor cells were stained positively for CD31, CD34, FLI1 and Vimentin but negative for S-100, DOG1, MC and CR, supporting the diagnosis of angiosarcoma.

For treatments and outcomes, angiosarcomas are often analyzed together, though they involve several different clinical subtypes. Owing to its high malignancy by definition, angiosarcomas have poor prognosis comparing to other vascular tumors or soft tissue sarcomas [6-8, 15]. The five years survival rate of angiosarcomas varied around 40% and the overall median survival time ranged from 7.3 to 42 months among different studies [5, 6, 8, 61]. The prognosis was moderated by clinical factors such as age, tumor size, anatomic site, and metastatic status instead of histologic features, partly for the reason of the difficulty for conventionally histologic grading [4, 14, 56, 61, 62]. In a recent retrospective study of 434 cutaneous angiosarcoma cases, patients younger than 50 years had a 10-year relative survival rate of 71.7%, while in older patients the rate dropped to 36.8%. And angiosarcoma of scalp and neck might have a lower 10-year relative survival rate compared to other sites [63]. But patients with primary or secondary angiosarcoma of oral and salivary gland might have a better prognosis than with other primary cutaneous or deep soft tissue angiosarcoma [64]. In addition to age, the extent of primary tumors, resection status and the pattern of tumor growth, indicated by whether the solid areas greater than 80%, were also prognostic factors for angiosarcoma of head and neck [65].

There are no specific treatment guidelines for subtypes of angiosarcoma up to now. Treatment of angiosarcomas has been included in management guidelines for other soft-tissue sarcomas, such as guidelines from European Society for Medical Oncology (ESMO) and the National Comprehensive Cancer Network (NCCN) [16, 66]. Most published reports of angiosarcoma treatment are retrospective case series instead of randomized trials and prospective studies.

For localized disease, radical surgery with complete resection is the primary treatment modality. Adjuvant radiotherapy with high dose and wide treatment field is recommended after surgery due to the high risk of local recurrence [7, 67]. Considering the risk of metastasis there is a rationale for the use of adjuvant chemotherapy, however, by now there still lacks sound evidence supporting neoadjuvant or adjuvant chemotherapy after radical surgery and radiotherapy for angiosarcoma [8, 16]. For metastatic angiosarcoma, cytotoxic chemotherapy is the primary treatment of choice, though evidence supporting this modality is also limited. The commonly used cytotoxic drugs include anthracyclines, taxanes and ifosfamide. A large meta-analysis of anthracycline-based chemotherapy demonstrated an overall response rate of 26% and median survival of 51 weeks in soft-tissue sarcomas [68]. Similar response rates but worse survival time were reported in angiosarcoma [69]. Over the past decade there has been growing interest using taxane agent to treat angiosarcoma. The ANGIOTAX study, the only prospective phase II study of chemotherapy in angiosarcoma, investigated the efficacy of paclitaxel in the treatment of locally-advanced and metastatic angiosarcoma [70]. Based on this trial, paclitaxel is listed as the cytotoxic agent of first choice for systemic treatment of angiosarcoma in the NCCN Guidelines. However, there are no available trials comparing the efficacy of anthracycline and taxane in angiosarcoma yet. Retrospective comparisons suggest similar response rates and survival for both cytotoxic agents [6]. Most recently, the role of several antiangiogenic molecules including bevacizumab, sorafenib and sunitinib in the treatment of angiosarcomas has been explored with great interest by several groups. Evidence in three phase II trials supports the use of sunitinib and sorafenib (broad-spectrum tyrosine-kinase targeting VEGFRs) as well as bevacizumab (VEGF-A monoclonal antibody) in the use of targeted treatment for locally-advanced and metastatic angiosarcoma [71-73].

Conclusion

We described a unique case of diffused metastatic angiosarcoma involving tonsil in which diagnosis was not achieved until the third biopsy. This case was still extraordinarily peculiar because of both its rarity and unique initial pre-

sentation as a repeated shedding tonsil neoplasm. The disease quickly deteriorated and the patient died of progressed metastatic angiosarcoma 6 months after diagnosis. For metastatic angiosarcoma, palliative chemotherapy is hampered by poor response rates and toxicities, while biological therapies especially antiangiogenic therapies offer hope for an angiosarcoma specific treatment in future.

Acknowledgements

This study was supported by National Natural Science Foundation of China (81201934, 81202100), and Tianjin Research Program of Application Foundation and Advanced Technology (12JCYBJC15600). Written informed consent was obtained from the legal guardians of the patient for publication of this case report and any accompanying images.

Disclosure of conflict of interest

None.

Address correspondence to: Dr. Xuejun Yu, Department of Medical Oncology, Cancer Center, Qilu Hospital of Shandong University, 107 Wenhua Xi Road, Jinan 250012, PR China. Tel: 86-531-82169851; E-mail: yuxuejun99@163.com

References

- [1] Young RJ, Brown NJ, Reed MW, Hughes D and Woll PJ. Angiosarcoma. *Lancet Oncol* 2010; 11: 983-991.
- [2] Coindre JM, Terrier P, Guillou L, Le Doussal V, Collin F, Ranchere D, Sastre X, Vilain MO, Bonichon F and N'Guyen Bui B. Predictive value of grade for metastasis development in the main histologic types of adult soft tissue sarcomas: a study of 1240 patients from the French Federation of Cancer Centers Sarcoma Group. *Cancer* 2001; 91: 1914-1926.
- [3] Rouhani P, Fletcher CD, Devesa SS and Toro JR. Cutaneous soft tissue sarcoma incidence patterns in the U.S.: an analysis of 12, 114 cases. *Cancer* 2008; 113: 616-627.
- [4] Deyrup AT, McKenney JK, Tighiouart M, Folpe AL and Weiss SW. Sporadic cutaneous angiosarcomas: a proposal for risk stratification based on 69 cases. *Am J Surg Pathol* 2008; 32: 72-77.
- [5] Fayette J, Martin E, Piperno-Neumann S, Le Cesne A, Robert C, Bonvalot S, Ranchere D, Pouillart P, Coindre JM and Blay JY. Angiosarcomas, a heterogeneous group of sarcomas

Angiosarcoma presented as repeated shedding tonsil neoplasm

- with specific behavior depending on primary site: a retrospective study of 161 cases. *Ann Oncol* 2007; 18: 2030-2036.
- [6] Fury MG, Antonescu CR, Van Zee KJ, Brennan MF and Maki RG. A 14-year retrospective review of angiosarcoma: clinical characteristics, prognostic factors, and treatment outcomes with surgery and chemotherapy. *Cancer J* 2005; 11: 241-247.
 - [7] Mark RJ, Poen JC, Tran LM, Fu YS and Juillard GF. Angiosarcoma. A report of 67 patients and a review of the literature. *Cancer* 1996; 77: 2400-2406.
 - [8] Abraham JA, Hornicek FJ, Kaufman AM, Harmon DC, Springfield DS, Raskin KA, Mankin HJ, Kirsch DG, Rosenberg AE, Nielsen GP, Deshpande V, Suit HD, DeLaney TF and Yoon SS. Treatment and outcome of 82 patients with angiosarcoma. *Ann Surg Oncol* 2007; 14: 1953-1967.
 - [9] Naka N, Ohsawa M, Tomita Y, Kanno H, Uchida A and Aozasa K. Angiosarcoma in Japan. A review of 99 cases. *Cancer* 1995; 75: 989-996.
 - [10] Kotromanovic Z, Mihalj H, Zubcic Z, Vceva A, Birtic D and Rajc J. Angiosarcoma of the hypopharynx: case report. *Coll Antropol* 2012; 36 Suppl 2: 185-187.
 - [11] Goldblum JR, Weiss SW and Folpe AL. *Enzinger and Weiss's soft tissue tumors*. Elsevier Health Sciences 2013.
 - [12] Fletcher CD; Organization WH and Cancer IAfRo. *WHO classification of tumours of soft tissue and bone*. IARC press; 2013.
 - [13] Lahat G, Dhuka AR, Lahat S, Smith KD, Pollock RE, Hunt KK, Ravi V, Lazar AJ and Lev D. Outcome of locally recurrent and metastatic angiosarcoma. *Ann Surg Oncol* 2009; 16: 2502-2509.
 - [14] Lahat G, Dhuka AR, Hallevi H, Xiao L, Zou C, Smith KD, Phung TL, Pollock RE, Benjamin R, Hunt KK, Lazar AJ and Lev D. Angiosarcoma: clinical and molecular insights. *Ann Surg* 2010; 251: 1098-1106.
 - [15] Mocellin S, Rossi CR, Brandes A and Nitti D. Adult soft tissue sarcomas: conventional therapies and molecularly targeted approaches. *Cancer Treat Rev* 2006; 32: 9-27.
 - [16] Grimer R, Judson I, Peake D and Seddon B. Guidelines for the management of soft tissue sarcomas. *Sarcoma* 2010; 2010: 506182.
 - [17] Gorsky M and Epstein JB. Head and neck and intra-oral soft tissue sarcomas. *Oral Oncol* 1998; 34: 292-296.
 - [18] Nagata M, Yoshitake Y, Nakayama H, Yoshida R, Kawahara K, Nakagawa Y and Shinohara M. Angiosarcoma of the oral cavity: a clinicopathological study and a review of the literature. *Int J Oral Maxillofac Surg* 2014; 43: 917-923.
 - [19] Hirshberg A, Shnaiderman-Shapiro A, Kaplan I and Berger R. Metastatic tumours to the oral cavity-pathogenesis and analysis of 673 cases. *Oral Oncol* 2008; 44: 743-752.
 - [20] Brook IM and Martin BA. Angiosarcoma, metastatic to the mandible and maxilla. *Br J Oral Surg* 1980; 18: 266-271.
 - [21] Toth BB, Fleming TJ, Lomba JA and Martin JW. Angiosarcoma metastatic to the maxillary tuberosity gingiva. *Oral Surg Oral Med Oral Pathol* 1981; 52: 71-74.
 - [22] Carr RJ and Green DM. Oral presentation of disseminated angiosarcoma. *Br J Oral Maxillofac Surg* 1986; 24: 277-285.
 - [23] Epstein JB, Knowling MA and Le Riche JC. Multiple gingival metastases from angiosarcoma of the breast. *Oral Surg Oral Med Oral Pathol* 1987; 64: 554-557.
 - [24] Win KK, Yasuoka T, Kamiya H and Jinno T. Breast angiosarcoma metastatic to the maxillary gingiva. Case report. *Int J Oral Maxillofac Surg* 1992; 21: 282-283.
 - [25] Pouloupoulos AK, Antoniadis K and Kiziridou A. Bilateral metastatic breast angiosarcoma to the mandibular gingiva: case report. *Oral Oncol* 2001; 37: 199-201.
 - [26] Ramadhan A, Willén H and Thor A. Angiosarcoma of the mandible: Metastasis from a primary tumor of the right atrium of the heart. 2013.
 - [27] Tonyali O, Sumbul AT, Ozturk MA, Koyuncuer A and Ekiz F. A case of rectal adenocarcinoma presented with palatine tonsil metastasis. *J Oncol Pharm Pract* 2016; 22: 341-3.
 - [28] Wang H and Chen P. Palatine tonsillar metastasis of rectal adenocarcinoma: a case report and literature review. *World J Surg Oncol* 2013; 11: 114.
 - [29] Goldenberg D, Golz A, Arie YB and Joachims HZ. Adenocarcinoma of the rectum with metastasis to the palatine tonsil. *Otolaryngol Head Neck Surg* 1999; 121: 653-654.
 - [30] Cecchi R, Pavesi M, Calamandrei P, Rapicano V and De Gaudio C. Tonsil metastasis from cutaneous melanoma: first clinical sign of recurrence after complete lymph node dissection. *J Cutan Med Surg* 2010; 14: 43-45.
 - [31] Tueche SG. Behavior of malignant melanoma with tonsil metastasis. *Ann Med Interne (Paris)* 2002; 153: 136-138.
 - [32] Aydogan LB, Myers JN, Myers EN and Kirkwood J. Malignant melanoma metastatic to the tonsil. *Laryngoscope* 1996; 106: 313-316.
 - [33] Craig RM, Glass BJ and Rhyne RR. Malignant melanoma: metastasis to the tonsil. *J Am Dent Assoc* 1982; 104: 893-894.
 - [34] Solis-Alfonso L and Suarez-Pria SD. Tonsil metastasis as initial presentation of clear cell renal carcinoma. *Actas Urol Esp* 2015; 39: 269-70.
 - [35] Marcotullio D, Iannella G, Macri GF, Marinelli C, Zelli M and Magliulo G. Renal clear cell carcinoma metastatic to the tonsil. *Int J Clin Exp Pathol* 2016; 9(4):4622-4632

- noma and tonsil metastasis. *Case Rep Otolaryngol* 2013; 2013: 315157.
- [36] Sano R, Sato E, Watanabe T, Oshima H, Ando A, Masaki M and Nakashima T. Phyllodes tumor metastasis to the tonsil with synchronous undifferentiated carcinoma. *Int J Surg Case Rep* 2014; 5: 290-293.
- [37] Zepiridis L, Zafarakas M, Theodoridis TD, Kaplanis K, Dinas KK and Bontis JN. A unique case of palatine tonsil metastasis from endometrial cancer. *Eur J Gynaecol Oncol* 2009; 30: 229-230.
- [38] Siniakov BS. A case of metastasis of seminoma to the palatine tonsil. *Vestn Otorinolaringol* 1963; 25: 99-101.
- [39] Kim EJ, Kim SR, Jin Gang S, Park SY, Han YM and Lee YC. Tonsillar metastasis of small cell lung cancer in a patient with idiopathic pulmonary fibrosis: a case report. *Medicine (Baltimore)* 2015; 94: e565.
- [40] Unsal M, Kutlar G, Sullu Y and Yurtlu S. Tonsillar metastasis of small cell lung carcinoma. *Clin Respir J* 2015; [Epub ahead of print].
- [41] Arroyo HH, Takehara J, Ogawa AI, Frizzarini R, Imamura R and Paula HM. Small cell lung carcinoma metastasis to palatine tonsils. *Braz J Otorhinolaryngol* 2013; 79: 645.
- [42] Chen XH, Bao YY, Zhou SH, Wang QY and Zhao K. Palatine Tonsillar Metastasis of Small-Cell Neuroendocrine Carcinoma from the Lung Detected by FDG-PET/CT After Tonsillectomy: A Case Report. *Iran J Radiol* 2013; 10: 148-151.
- [43] Rokkjaer MS and Klug TE. Malignancy in routine tonsillectomy specimens: a systematic literature review. *Eur Arch Otorhinolaryngol* 2014; 271: 2851-2861.
- [44] Kara T, Serinsoz E, Arpacı RB and Vayisoglu Y. Follicular dendritic cell sarcoma of the tonsil. *BMJ Case Rep* 2013; 2013.
- [45] McDuffie C, Lian TS and Thibodeaux J. Follicular dendritic cell sarcoma of the tonsil: a case report and literature review. *Ear Nose Throat J* 2007; 86: 234-235.
- [46] Soria-Céspedes D, Galvan-Linares AI, Oros-Ovalle C, Gaitan-Gaona F and Ortiz-Hidalgo C. Primary monophasic synovial sarcoma of the tonsil: immunohistochemical and molecular study of a case and review of the literature. *Head Neck Pathol* 2013; 7: 400-403.
- [47] Kim SY, Kang JH, Chun SH, Chang MH, Kim YS, Lee SN, Kim MS and Kang CS. Interdigitating dendritic cell sarcoma of the tonsil. *Asia Pac J Clin Oncol* 2010; 6: 144-148.
- [48] Chetty R and Batitang S. Kaposi's sarcoma of the tonsil. *ORL J Otorhinolaryngol Relat Spec* 1998; 60: 48-50.
- [49] Raikundalia KB. Kaposi's sarcoma of tonsil. *J Laryngol Otol* 1973; 87: 295-297.
- [50] Agaoglu FY, Dizdar Y, Basaran M, Bilgic B and Darendeliler E. Human immunodeficiency virus-negative tonsil Kaposi's sarcoma and Hodgkin's disease: case report and review of the literature. *J BUON* 2004; 9: 321-324.
- [51] Agaimy A, Kirsche H, Semrau S, Iro H and Hartmann A. Cytokeratin-positive epithelioid angiosarcoma presenting in the tonsil: a diagnostic challenge. *Hum Pathol* 2012; 43: 1142-1147.
- [52] Lin XY, Liu Y, Zhang Y, Yu JH and Wang EH. The co-expression of cytokeratin and p63 in epithelioid angiosarcoma of the parotid gland: a diagnostic pitfall. *Diagn Pathol* 2012; 7: 118.
- [53] Bar R, Netzer A, Ostrovsky D, Daitzchman M and Golz A. Abrupt tonsillar hemorrhage from a metastatic hemangiosarcoma of the breast: case report and literature review. *Ear Nose Throat J* 2011; 90: 116-120.
- [54] Lee CH, Chan GS and Chan WM. Unexplained recurrent pericardial effusion: a lethal warning? *Heart* 2003; 89: e11.
- [55] Dowdall JR, Opfermann KJ, Kim H and Lin HS. A case of radiation-induced multifocal laryngeal angiosarcoma presenting as a diagnostic dilemma. *Case Rep Otolaryngol* 2012; 2012: 139310.
- [56] Weiss SW, Goldblum JR and Folpe AL. *Enzinger and Weiss's soft tissue tumors*, 6th edition. Elsevier Health Sciences; 2013.
- [57] Ohsawa M, Naka N, Tomita Y, Kawamori D, Kanno H and Aozasa K. Use of immunohistochemical procedures in diagnosing angiosarcoma. Evaluation of 98 cases. *Cancer* 1995; 75: 2867-2874.
- [58] Sullivan HC, Edgar MA, Cohen C, Kovach CK, HooKim K and Reid MD. The utility of ERG, CD31 and CD34 in the cytological diagnosis of angiosarcoma: an analysis of 25 cases. *J Clin Pathol* 2015; 68: 44-50.
- [59] Sullivan HC, Edgar MA, Cohen C, Kovach CK, HooKim K and Reid MD. The utility of ERG, CD31 and CD34 in the cytological diagnosis of angiosarcoma: an analysis of 25 cases. *J Clin Pathol* 2015; 68: 44-50.
- [60] Wang ZB, Yuan J, Chen W and Wei LX. Transcription factor ERG is a specific and sensitive diagnostic marker for hepatic angiosarcoma. *World J Gastroenterol* 2014; 20: 3672-3679.
- [61] Buehler D, Rice SR, Moody JS, Rush P, Hafez GR, Attia S, Longley BJ and Kozak KR. Angiosarcoma outcomes and prognostic factors: a 25-year single institution experience. *Am J Clin Oncol* 2014; 37: 473-479.
- [62] Aust MR, Olsen KD, Lewis JE, Nascimento AG, Meland NB, Foote RL and Suman VJ. Angiosarcomas of the head and neck: clinical and pathologic characteristics. *Ann Otol Rhinol Laryngol* 1997; 106: 943-951.

- [63] Albores-Saavedra J, Schwartz AM, Henson DE, Kostun L, Hart A, Angeles-Albores D and Chable-Montero F. Cutaneous angiosarcoma. Analysis of 434 cases from the Surveillance, Epidemiology, and End Results Program, 1973-2007. *Ann Diagn Pathol* 2011; 15: 93-97.
- [64] Fanburg-Smith JC, Furlong MA and Childers EL. Oral and salivary gland angiosarcoma: a clinicopathologic study of 29 cases. *Mod Pathol* 2003; 16: 263-271.
- [65] Dettenborn T, Wermker K, Schulze HJ, Klein M, Schwipper V and Hallermann C. Prognostic features in angiosarcoma of the head and neck: A retrospective monocenter study. *J Craniomaxillofac Surg* 2014; 42: 1623-8.
- [66] ESMO/European Sarcoma Network Working Group. Soft tissue and visceral sarcomas: ESMO Clinical Practice Guidelines for diagnosis, treatment and follow-up. *Ann Oncol* 2014; 25 Suppl 3: iii102-112.
- [67] Pawlik TM, Paulino AF, McGinn CJ, Baker LH, Cohen DS, Morris JS, Rees R and Sondak VK. Cutaneous angiosarcoma of the scalp: a multidisciplinary approach. *Cancer* 2003; 98: 1716-1726.
- [68] Van Glabbeke M, van Oosterom AT, Oosterhuis JW, Mouridsen H, Crowther D, Somers R, Verweij J, Santoro A, Buesa J and Tursz T. Prognostic factors for the outcome of chemotherapy in advanced soft tissue sarcoma: an analysis of 2,185 patients treated with anthracycline-containing first-line regimens—a European Organization for Research and Treatment of Cancer Soft Tissue and Bone Sarcoma Group Study. *J Clin Oncol* 1999; 17: 150-157.
- [69] Asmane I, Litique V, Heymann S, Marcellin L, Metivier AC, Duclos B, Bergerat JP and Kurtz JE. Adriamycin, cisplatin, ifosfamide and paclitaxel combination as front-line chemotherapy for locally advanced and metastatic angiosarcoma. Analysis of three case reports and review of the literature. *Anticancer Res* 2008; 28: 3041-3045.
- [70] Penel N, Bui BN, Bay JO, Cupissol D, Ray-Coquard I, Piperno-Neumann S, Kerbrat P, Fournier C, Taieb S, Jimenez M, Isambert N, Peyrade F, Chevreau C, Bompas E, Brain EG and Blay JY. Phase II trial of weekly paclitaxel for unresectable angiosarcoma: the ANGIOTAX Study. *J Clin Oncol* 2008; 26: 5269-5274.
- [71] Maki RG, D'Adamo DR, Keohan ML, Saulle M, Schuetze SM, Undevia SD, Livingston MB, Cooney MM, Hensley ML, Mita MM, Takimoto CH, Kraft AS, Elias AD, Brockstein B, Blachere NE, Edgar MA, Schwartz LH, Qin LX, Antonescu CR and Schwartz GK. Phase II study of sorafenib in patients with metastatic or recurrent sarcomas. *J Clin Oncol* 2009; 27: 3133-3140.
- [72] George S, Merriam P, Maki RG, Van den Abbeele AD, Yap JT, Akhurst T, Harmon DC, Bhuchar G, O'Mara MM, D'Adamo DR, Morgan J, Schwartz GK, Wagner AJ, Butrynski JE, Demetri GD and Keohan ML. Multicenter phase II trial of sunitinib in the treatment of nongastrointestinal stromal tumor sarcomas. *J Clin Oncol* 2009; 27: 3154-3160.
- [73] Agulnik M, Yarber JL, Okuno SH, von Mehren M, Jovanovic BD, Brockstein BE, Evens AM and Benjamin RS. An open-label, multicenter, phase II study of bevacizumab for the treatment of angiosarcoma and epithelioid hemoendotheliomas. *Ann Oncol* 2013; 24: 257-263.
- [74] Froio GF and Kirkland WG. Lymphangiosarcoma in post-mastectomy lymphedema. *Ann Surg* 1952; 135: 421-425.