

Case Report

Primary pulmonary meningioma: a case report and a review of the literature

Guiyang Jiang¹, Yong Zhang¹, Juanhan Yu¹, Xuyong Lin¹, Chuifeng Fan¹, Chenglin Sun², Hongtao Xu¹, Enhua Wang¹

¹Department of Pathology, First Affiliated Hospital and College of Basic Medical Sciences, China Medical University, Shenyang 110211, China; ²Department of Surgery, The Center Hospital Affiliated to Shenyang Medical College, Shenyang, China

Received December 26, 2015; Accepted March 8, 2016; Epub April 1, 2016; Published April 15, 2016

Abstract: Ectopic meningiomas are rare, and primary pulmonary meningiomas are even rarer. Most of them are benign, but malignant primary pulmonary meningiomas have been reported. They usually present as a solitary pulmonary nodule, and primary lung cancer or metastasis may be suspected on imaging. Here, we report a case of a 63-year-old female with primary pulmonary meningioma. The chest CT scan revealed a well-circumscribed large intrapulmonary nodule in the left lung, and was diagnosed with a mesenchymal tumor by lung biopsy at a local hospital. After thorough examinations, a surgical resection was performed to remove the upper lobe of the left lung and the masses. A postoperative pathological report confirmed that the tumor was an ectopic meningioma. Metastatic meningioma was excluded by brain and spine MRI scans.

Keywords: Lung; meningioma, primary pulmonary meningioma, solitary pulmonary nodule

Introduction

Meningiomas are common tumors of the central nervous system (CNS) and are usually benign. Ectopic meningiomas are not common and are typically observed in the head and neck, though they may also be located in the skin, peripheral nerves, retroperitoneum, pelvis, and thorax [1-6]. However, primary pulmonary meningioma is rare, which usually appears as a solitary pulmonary nodule in lung radiographs. Since the first case was reported in 1981 by Erlandson et al., there have been only less than 45 cases reported in the world, and only five were malignant or atypical meningiomas [7-13]. Different histogenetic and pathologic mechanisms have been proposed, but the true etiology of these tumors is still controversial [14-16]. Here, we present a new case of primary pulmonary meningioma.

Case report

A 63-year-old female patient presented with a space-occupying lesion on the left lung in a

medical examination 10 month ago. The pathological biopsy was indicative of a mesenchymal tumor, but did not exclude the possibility of ectopic meningioma. The patient did not initially receive treatment; however, she sought further treatment on March 17, 2014. The clinical examination revealed a soft neck with a centrally localized trachea, swollen lymph nodes that were not touching the neck and supraclavicle, symmetrical thorax, breathing consistent with a steady rhythm, and normal language fibrillation with silent lung percussion. Breath sounds during lung auscultation were clear, without wet and dry rales. Plain computed tomography (CT) scans of the lung revealed thoracic symmetry and a visible shadow of a nodule in the left upper lung lobe, with a size of approximately 4.46 × 3.58 cm² and smooth edges. When the plain CT value was set at 44 HU, stripe-like shadows were observed in the lung lobes, and the bronchus at different levels was smooth, without expansion and narrowing (**Figure 1**). The hilars were small with the mediastinum in the middle. No enlarged lymph nodes were detected. The CNS CT scan and

A case report of primary pulmonary meningioma

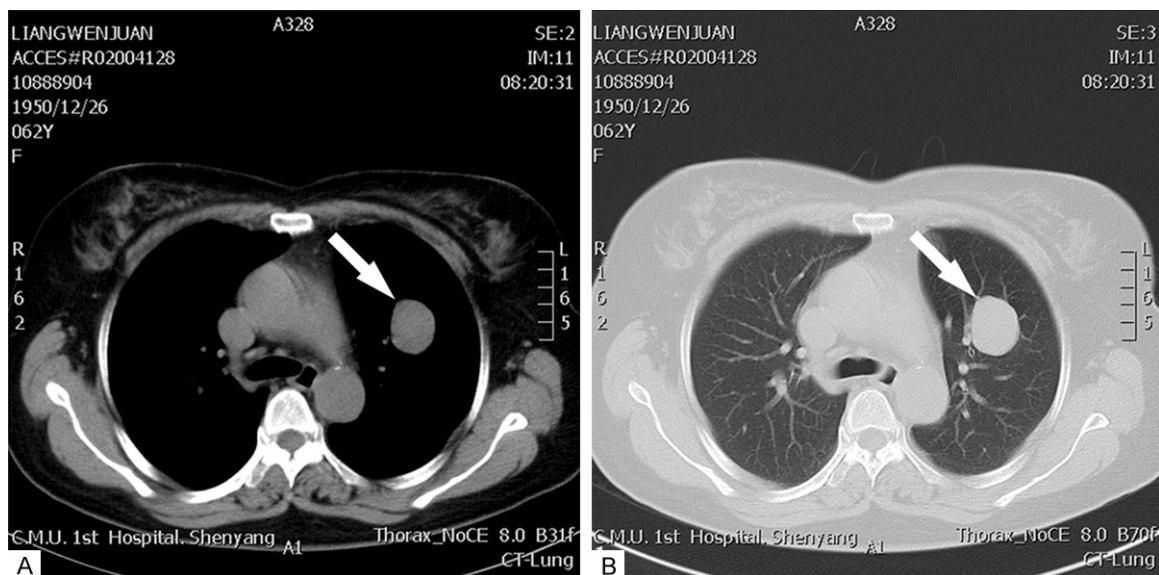


Figure 1. Computed tomography (CT) revealed a shadow of a nodule that was visible in the left upper lobe of the lung. The size was approximately $4.46 \times 3.58 \text{ cm}^2$ (the lesion is marked by the white arrow). The edges of the nodule were smooth. When the plain CT value was set at 44 HU, stripe-like shadows were observed in the lung lobes, and the bronchus at different levels was smooth without expansion and narrowing. The hilars were small, with the mediastinum located in the middle. No enlarged lymph nodes were detected.

magnetic resonance imaging (MRI) showed no abnormalities.

Surgical resection was performed to remove the upper lobe of the left lung. During the operation, a nodule was observed in the left lung. The nodule was cut open and fish-like tissue was observed. The nodule was then frozen and confirmed to be a low malignant potential mesenchymal tumor. The postoperative recovery of the patient was optimal.

On gross examination, a piece of the left lobe of the lung (volume, $10 \times 6 \times 5 \text{ cm}^3$) was removed, in which a gray nodule with a 3.5 cm diameter was observed. The boundaries were clear and the texture was relatively solid, with a slightly coarse and granular shape. No abnormalities were observed in the surrounding lung tissue. A microscopic examination revealed clear boundaries between the tumor and surrounding tissue, and no capsule. The tumor mainly consisted of epithelial and spindle cells. The epithelioid cells were relatively large, but the sizes were variable, with both polygonal and oval shapes observed. The cells had abundant cytoplasm and the staining was light. The nuclei were large and were round or oval. The nuclear membranes were clear and small nucleoli were visi-

ble. Some cells were observed with false inclusion bodies that were within the nuclei, and some formed sand-like organelles. The epithelial cells primarily formed swirling or nested structures. The spindle cells were mostly elongated or exhibited fibroblast-like spindles. Similarly, these cells had abundant cytoplasm and were lightly stained. The nuclei were round or oval, with inconspicuous nucleoli. The cell boundaries were not clear, and they formed banded beam-like or water-like structures, and were diffuse. In addition, in some regions of the nodule, the cells formed small lumps or showed a stripe-like distribution, were surrounded by interstitial fibrosis, and were accompanied by tissues with hyalinization. Necrosis and mitotic events were not observed in the tissue by microscopy. Additionally, no glass-like degeneration was observed in the thick-walled vessels (**Figure 2A-C**).

Immunohistochemical staining revealed a positive cytokeratin (CK) signal in some tumor cells. The signal was localized to the tumor cell cytoplasm, and displayed fine granules with moderately positive intensities. Epithelial membrane antigen (EMA) staining was similar to the pattern of CK expression, but was slightly stronger. Vimentin expression was positive in the cyto-

A case report of primary pulmonary meningioma

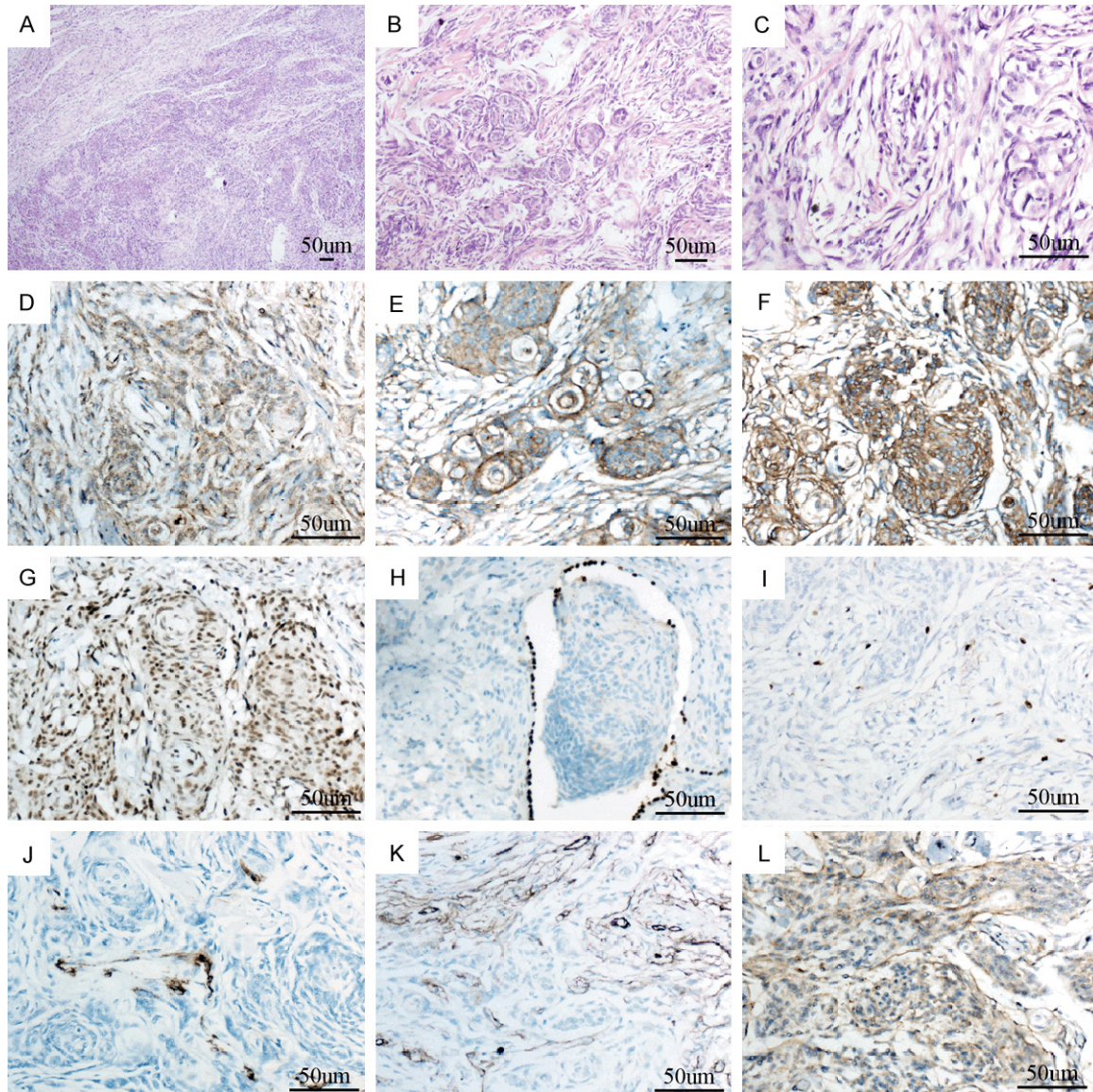


Figure 2. Biopsy results. Hematoxylin and eosin staining clearly showed that the tumor had a mass-like distribution, that the boundaries between tumor and the lung tissue were clear, and that the surrounding lung tissue showed consolidation and fibrosis ($\times 40$, A). Epithelioid cells formed a typical swirling structure ($\times 100$, B). Spindle cells formed banded bundles or water-like structures. No obvious mitosis was observed ($\times 200$, C). Immunohistochemical staining was performed using a 1:100 dilution of the following antibodies: cytokeratin ($\times 200$, D); epithelial membrane antigen ($\times 200$, E); vimentin ($\times 200$, F); progesterone receptor ($\times 200$, G); transcription termination factor 1 ($\times 200$, H); Ki-67 ($\times 200$, I); smooth muscle alpha-actin ($\times 200$, J); CD34 ($\times 200$, K); and CD99 ($\times 200$, L) (Fuzhou Maixin).

plasm of the tumor cells. Progesterone receptor (PR) showed clear nuclear expression in over 90% of the tumor cells, transcription termination factor 1 (TTF-1) staining of the tumor cells was negative but was positive in the alveolar epithelial cells, the Ki-67 positive rate was approximately 5%, smooth muscle alpha-actin (SMA) expression was positive in the cells of the vascular wall but negative in the tumor

cells, CD34 expression was negative in tumor cells but positive in endothelial cells, CD99 cytoplasmic expression in some tumor cells was weak to moderate hilars (**Figure 2D-L**), and the expression of S-100 and glial fibrillary acidic protein was negative. Finally, the pathological diagnosis for the left upper lobe was ectopic meningioma and the Ki-67-positive rate was 5%. Possible relapse was considered.

A case report of primary pulmonary meningioma

Discussion

Ectopic primary pulmonary meningioma is very rare, and only less than 45 cases have been reported in the literature [7-13]. However, some of these previous reports did not exclude intrapulmonary metastasis of intracranial meningioma by imaging studies, which makes primary pulmonary meningioma even rarer [17-21]. Here, we provide a new case of primary pulmonary meningioma, which showed no abnormalities by CT scan and MRI of CNS.

The exact origin of ectopic pulmonary meningioma is still unclear. Several theories exist regarding the formation of extracranial meningiomas. Based on the existing reports, primary pulmonary meningioma is believed to originate from arachnoid cell located in the lungs, from pluripotent inner cells in the epithelium of the pleura, or from small pulmonary meningothelial nodules [20-22]. However, molecular differences between MPMNs and meningiomas were recognized by a genotypic comparison [16]. So the pathogenesis remains controversial, and further research is necessary.

Primary pulmonary meningioma mostly occurs in the elderly. Previous reports have indicated that patients generally present with no clinical symptoms and are diagnosed accidentally by an examination. Primary pulmonary meningioma is occasionally accompanied by a cough, expectoration, and/or other symptoms [21]. Isolated nodules are often located around the lobes of the lungs, with clear boundaries. Primary pulmonary meningioma histological classifications and immunohistochemical features are similar to those of meningiomas in the CNS. Electron microscopy revealed that the tumor cells had finger-like projections and were connected by desmosomes.

The differential diagnosis can be made based on the following observations. First, although rare, metastatic meningiomas of the lung must be excluded. Meningiomas of the central nervous system arise in the cranial cavity and spinal cord, and a radiological study of the CNS, preferably an MRI, is required. Second, solitary fibrous tumors often occur in the chest and can be attached to the visceral pleura. The tumors are mostly lobular with clear boundaries. The tumor cells are spindle-like, with a spiral and weave-like arrangement, and are accompanied

by a large amount of thick and disordered collagen fibers. The collagen often shows hyalinization. The tumor cells are CD34 positive and EMA negative, and these markers can be used to differentiate solitary fibrous tumors from primary pulmonary meningiomas. Third, spindle cell mesothelioma (SCM) is primarily or exclusively comprised of spindle cells. It has a nodular appearance when observed by the naked eye. Based on microscopic observations, the tumors are cellular and consist of intertwined bundles of spindle cells. Immunohistochemical staining for cytokeratin is consistently positive, vimentin staining is also positive, and EMA staining is occasionally positive. Staining of PR is negative. These markers can be used to differentiate SCM from meningioma. Fourth, spindle cell thymoma can occur in the lungs. It is associated with spindle-shaped tumor cells, which are arranged into irregular bundles. Occasionally, it displays a storiform- or heman-giopericytoma-like appearance. Lymphocytic infiltration may also be observed. Spindle cell thymoma is keratin positive and vimentin negative. Meningioma is characterized by a spiral structure and a gravel body, and thus can be identified. Next, fibrous tissue inflammatory pseudo tumor (FTIP) is present in the lung and involves nodules with clear boundaries. It consists of hyperplastic fibroblasts. The tumor cells are arranged in bundles, and are accompanied by a large number of plasma cells and lymphocytes. Occasionally, there are more yellow tumor cells. Angiogenesis occurs within the lesion and there are visible remnants of the alveolar epithelium present, but the structures characteristic of meningioma are not present. Staining for SMA, ALK and CD68 is positive. Therefore, FTIP can be identified. Spindle cell carcinoma is a tumor of the lung. The tumor cells are spindle-like and form bundles or a storiform arrangement. The boundaries between the parenchyma and mesenchyme are clear. This type of tumor is positive by immunohistochemistry for keratin, and lacks the structures characteristic of meningiomas. Finally, other metastatic tumors of the lung, either carcinomas or sarcomas, commonly exhibit multiple nodules. Single nodules are rare. Usually, a surgical lung biopsy or histological examination can be used for identification.

Meningiomas are usually benign with a good prognosis [23, 24]. In recent years, reports of

A case report of primary pulmonary meningioma

pulmonary malignant meningiomas have emerged [7, 25], and have shown that primary pulmonary meningioma involves infiltrating growth with cellular atypia and obvious nucleoli. Nuclear division is common. Postoperative recurrence and metastasis may occur. Here, our case of primary pulmonary meningioma with no microscopic tissue necrosis. And nuclear divisions were rarely observed. However, local growth was relatively dense. The Ki-67 positive rate was approximately 5%. And the nodule diameter (3.5 cm) is relatively larger than benign meningiomas with a median size of 1.8 cm. After nearly one year of follow-up following a wedge resection, the evidence of metastasis or recurrences was not observed, and the patient is alive well.

Acknowledgements

This work was supported by grants from the National Natural Science Foundation of China (No. 81402369 to Guiyang Jiang, No. 81372497 to Hongtao Xu and No. 81272606 to Enhua Wang), and the Natural Science Foundation of Liaoning Province (No. 2013021049 to Yong Zhang).

Disclosure of conflict of interest

None.

Address correspondence to: Dr. Hongtao Xu, Department of Pathology, First Affiliated Hospital and College of Basic Medical Sciences, China Medical University, Shenyang 110211, China. Tel: (0086) 24-28710866; Fax: (0086) 24-28710866; E-mail: htxu77@163.com

References

- [1] Fried BM. Metastatic Inoculation of a meningioma by cancer cells from a bronchiogenic carcinoma. *Am J Pathol* 1930; 6: 47-52 41.
- [2] Pamphlett R. Carcinoma metastasis to meningioma. *J Neurol Neurosurg Psychiatry* 1984; 47: 561-563.
- [3] Schmitt HP. Metastases of malignant neoplasms to intracranial tumours: the "tumour-in-a-tumour" phenomenon. *Virchows Arch A Pathol Anat Histopathol* 1984; 405: 155-160.
- [4] Petraki C, Vaslamatzis M, Argyrakos T, Petraki K, Strataki M, Alexopoulos C and Sotsiou F. Tumor to tumor metastasis: report of two cases and review of the literature. *Int J Surg Pathol* 2003; 11: 127-135.
- [5] Aghi M, Kiehl TR and Brisman JL. Breast adenocarcinoma metastatic to epidural cervical spine meningioma: case report and review of the literature. *J Neurooncol* 2005; 75: 149-155.
- [6] Lanotte M, Benech F, Panciani PP, Cassoni P and Ducati A. Systemic cancer metastasis in a meningioma: report of two cases and review of the literature. *Clin Neurol Neurosurg* 2009; 111: 87-93.
- [7] Prayson RA and Farver CF. Primary pulmonary malignant meningioma. *Am J Surg Pathol* 1999; 23: 722-726.
- [8] van der Meij JJ, Boomars KA, van den Bosch JM, van Boven WJ, de Bruin PC and Seldenrijk CA. Primary pulmonary malignant meningioma. *Ann Thorac Surg* 2005; 80: 1523-1525.
- [9] Incarbone M, Ceresoli GL, Di Tommaso L, Cappuzzo F, Inzirillo F, Infante M and Alloisio M. Primary pulmonary meningioma: report of a case and review of the literature. *Lung Cancer* 2008; 62: 401-407.
- [10] Weber C, Pautex S, Zulian GB, Pusztaszeri M and Lobrinus JA. Primary pulmonary malignant meningioma with lymph node and liver metastasis in a centenary woman, an autopsy case. *Virchows Arch* 2013; 462: 481-485.
- [11] Kim YY, Hong YK, Kie JH and Ryu SJ. Primary pulmonary meningioma: an unusual cause of a nodule with strong and homogeneous enhancement. *Clin Imaging* 2016; 40: 170-173.
- [12] Lepanto D, Maffini F, Petrella F, Colandrea M, Putzu C, Barberis M, Paganelli G and Viale G. Atypical primary pulmonary meningioma: a report of a case suspected of being a lung metastasis. *Ecancermedicallscience* 2014; 8: 414.
- [13] Caobelli F, Facchetti F, Pizzocaro C, Ferrari V, Savelli G and Guerra UP. A very unusual and aggressive form of a primary pulmonary meningioma seen with a (6)(8)Ga-DOTATOC PET/CT image. *Rev Esp Med Nucl Imagen Mol* 2015; 34: 123-124.
- [14] Gaffey MJ, Mills SE and Askin FB. Minute pulmonary meningothelial-like nodules. A clinicopathologic study of so-called minute pulmonary chemodectoma. *Am J Surg Pathol* 1988; 12: 167-175.
- [15] Marchevsky AM. Lung tumors derived from ectopic tissues. *Semin Diagn Pathol* 1995; 12: 172-184.
- [16] Ionescu DN, Sasatomi E, Aldeeb D, Omalu BI, Finkelstein SD, Swalsky PA and Yousem SA. Pulmonary meningothelial-like nodules: a genotypic comparison with meningiomas. *Am J Surg Pathol* 2004; 28: 207-214.
- [17] Stoller JK, Kavuru M, Mehta AC, Weinstein CE, Estes ML and Gephardt GN. Intracranial me-

A case report of primary pulmonary meningioma

- ningioma metastatic to the lung. *Cleve Clin J Med* 1987; 54: 521-527.
- [18] Strimlan CV, Golembiewski RS, Celko DA and Fino GJ. Primary pulmonary meningioma. *Surg Neurol* 1988; 29: 410-413.
- [19] Robinson PG. Pulmonary meningioma. Report of a case with electron microscopic and immunohistochemical findings. *Am J Clin Pathol* 1992; 97: 814-817.
- [20] Moran CA, Hochholzer L, Rush W and Koss MN. Primary intrapulmonary meningiomas. A clinicopathologic and immunohistochemical study of ten cases. *Cancer* 1996; 78: 2328-2333.
- [21] Gomez-Aracil V, Mayayo E, Alvira R, Arraiza A, Ramón y Cajal S. Fine needle aspiration cytology of primary pulmonary meningioma associated with minute meningotheliallike nodules. Report of a case with histologic, immunohistochemical and ultrastructural studies. *Acta Cytol* 2002; 46: 899-903.
- [22] Lockett L, Chiang V and Scully N. Primary pulmonary meningioma: report of a case and review of the literature. *Am J Surg Pathol* 1997; 21: 453-460.
- [23] Satoh Y and Ishikawa Y. Primary pulmonary meningioma: Ten-year follow-up findings for a multiple case, implying a benign biological nature. *J Thorac Cardiovasc Surg* 2010; 139: e39-40.
- [24] Kodama K, Doi O, Higashiyama M, Horai T, Tateishi R and Nakagawa H. Primary and metastatic pulmonary meningioma. *Cancer* 1991; 67: 1412-1417.
- [25] Rowsell C, Sirbovan J, Rosenblum MK and Perez-Ordóñez B. Primary chordoid meningioma of lung. *Virchows Arch* 2005; 446: 333-337.