

Case Report

Bizarre parosteal osteochondromatous proliferation in the fifth rib: report of a case with novel presentations

Hong Yu^{1*}, Haihui Sheng^{2*}, Xiaoqun Yang³, Hengjun Gao², Xuhui Kong⁴, Chaofu Wang⁵

¹Department of Pathology, Taizhou People's Hospital, Taizhou, Jiangsu Province, China; ²Shanghai Engineering Center for Molecular Medicine, National Engineering Center for Biochip at Shanghai, Shanghai, China;

³Department of Pathology, Cancer Hospital of Fudan University, Shanghai, China; ⁴Department of Ophthalmology, Taizhou People's Hospital, Taizhou, Jiangsu Province, China; ⁵Department of Pathology, Ruijin Hospital, Shanghai Jiaotong University School of Medicine, Shanghai, China. *Equal contributors.

Received December 27, 2015; Accepted March 8, 2016; Epub May 1, 2016; Published May 15, 2016

Abstract: Bizarre parosteal osteochondromatous proliferation (BPOP) is a rare benign surface osteocartilaginous lesion, mainly affecting the small bones of the hands and feet. Here, we present a case of a young male with a mass in the rib that originally was thought to be a chondrosarcoma. After pathology consultation in our hospital, the final pathology diagnosis was BPOP, also called Nora's lesion. The location of the lesion of the patient was atypical. To our knowledge, this was the first report of BPOP in the rib.

Keywords: Bizarre parosteal osteochondromatous proliferation, Nora's lesion, osteochondroma, diagnosis, differential diagnosis

Introduction

Bizarre parosteal osteochondromatous proliferation (BPOP) was first described by Nora et al in 1983 [1]. BPOP is described as an uncommon reactive mesenchymal lesion composed of bone, cartilage and fibrous tissues which usually affects the small bones of the hands and feet, and is easily misdiagnosed [2]. Herein, we first present a case report of BPOP in the fifth rib in a young man to raise awareness of this rare disease.

Case report

A 34-year-old man was in local hospital for routine medical examination in June 2014. Chest computed tomography (CT) scan showed a 2.5-cm-diameter mass involving the back end of the fifth right rib. Therefore, the patient underwent a surgical resection of the mass in the local hospital. Postoperative pathological diagnosis was chondrosarcoma with grade II. The patient was referred to our hospital for pathology consultation. Histopathological slides and radiographs were reviewed by a multi-disciplinary team including the pathology and

imaging experts of our hospital. The chest CT scan of the local hospital revealed a 2.5-cm-diameter nodular with well-defined margin involving the fifth rib. The mass was laying the surface of the back end of the fifth rib without cortical erosion and not invading the nearby lung or soft tissues (**Figure 1**). Histopathologically, the lesion exhibited a well-defined contour and had cap-like cartilage maturing into trabecular bone. Characterized with unusual mineralized cartilaginous matrix (blue bone), the lesion was composed of a heterogeneous mixture of cartilage, bone, and fibrous tissue. In some areas, slight atypia in the form of anisokaryosis and irregular shape were noted of the chondrocytes (**Figure 2**). The final pathological diagnosis was BPOP involving the fifth rib based on the imaging findings and histomorphologic features. The patient is being followed up regularly and there is no clinical evidence of recurrence at 18 months after surgery.

Discussions

BPOP, also called Nora's lesion, is a benign lesion first described by Nora and colleagues in 1983. To date, around 200 cases of Nora's

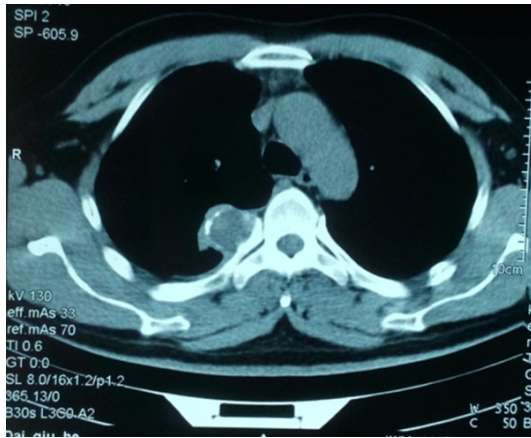


Figure 1. Computed tomography scan showed a rounded mass with well-defined border on the surface of the fifth rib back-end without cortical destruction.

lesion have been reported in the literature. Nora's lesion is an uncommon reactive mesenchymal lesion that usually affects the small bones of the hands and feet. Subsequently various other locations have also been reported in the literature including the radius, ulna, fibula, femur, tibia, humerus, skull, zygoma, maxilla, mandible, and nasal dorsum [3-9]. However, these presentations are extremely rare. The present patient developed a lesion in the rib region, and to our knowledge, this is the first reported case of Nora's lesion involving the rib.

BPOP can affect patients in a broad age range with no apparent sex predilection, but its incidence increases in the third and fourth decades of life [10]. One third of patients had a history of trauma [11]. It usually present as a painless, slowly enlarging mass [12]. Although BPOP is known to have a high rate of local recurrence, there have been no cases of malignant degeneration or metastasis. Complete excision is the most commonly recommended treatment. Mors et al. advocated wide surgical margins or negative margins confirmed by frozen section to reduce the high recurrence rate [5]. The present patient received a surgical resection of the mass. After 18 months follow-up, there is no clinical evidence of recurrence and the patient is still undergoing followed-up.

BPOPs have distinctive radiographic and histopathologic features that distinguish them from other osteochondromatous diseases. Radiologically, BPOPs exhibit as well-margined

mass of heterotopic mineral arising directly from the cortical surface of the underlying bone without destruction of the parent bone and infiltration of adjacent soft tissues. Histopathologically, the features of BPOP include proliferative changes in bone, cartilage, and fibrous tissue mixed heterogeneously. A cartilage cap is usually observed. The cartilage can be quite proliferative and numerous chondrocytes with bizarre enlarged, binucleate cells, and slight atypia that may mimic a chondrosarcoma. Distinctive feature of the presence of the so-called "blue bone" caused by deep blue staining of mineralized cartilaginous matrix with haematoxylin and eosin always could be found. The blue bone is essential for the diagnosis of BPOP.

BPOP is an unusual and easily misdiagnosed clinical entity. Differential diagnoses include osteochondroma, periosteal chondroma, subungual exostosis, chondrosarcoma, periosteal chondrosarcoma, parosteal osteosarcoma, and myositis ossificans. Osteochondromas seldom occur on the small bones. Radiographs show cortical and medullary continuity. Moreover, osteochondromas do not have typical blue bone of BPOP. Periosteal chondroma could be distinguished from BPOP by lack of blue bone and fibrous tissue which always could be observed in BPOP. Subungual exostosis is a proliferative process consisting of bone and cartilage, and involving the nail bed. Patients usually present with a mass lesion that elevates the nail and sometimes causes ulceration. In addition, subungual exostosis is lack of blue bone which is essential for the diagnosis of BPOP. Chondrosarcoma is remarkably different from BPOP in location, clinical, radiographic and morphologic findings. Chondrosarcoma is a malignant tumor composed entirely of a hyaline cartilage matrix and chondrocytes in lacunae. Except for differences in lesion location, radiographic, and histopathologic appearance, the permeative and destructive qualities of the tumor are apparent. Periosteal chondrosarcomas are extremely rare, and frequently have the cytologic features of malignancy. Radiographic appearance and histopathologic findings show that the tumors usually break through the cortex and invade the surrounding soft tissue which is not seen in BPOP. In addition to cortical destruction in imaging features, key indicators of parosteal osteosarcoma are atypical osteoblasts and

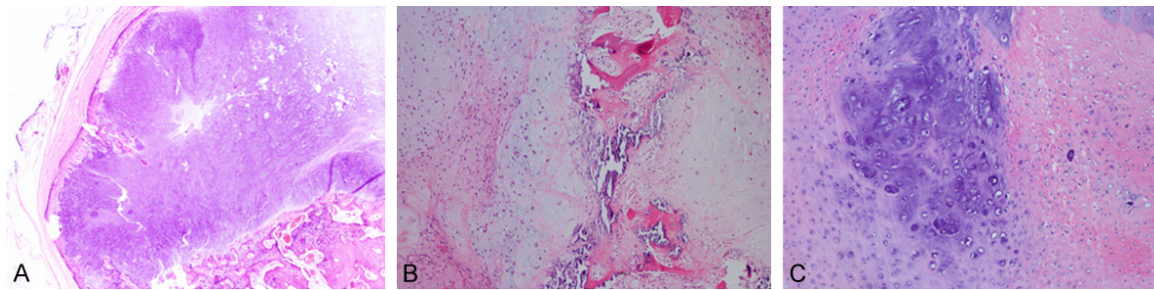


Figure 2. Histopathological analysis. A. The lesion exhibited a well-defined contour and had cap-like cartilage maturing into trabecular bone (20×). B. The lesion was consisted of a mixture of bone, cartilage and fibrous tissue miscel-laneously (100×). C. The lesion showed characteristic “blue bone” (100×).

fibroblasts infiltration into the peripheral tissue. Myositis ossificans is localized, self-limiting, reparative lesion that is composed of reactive hypercellular fibrous tissue and bone. The most common locations are those most susceptible to trauma such as the elbow, thigh, buttock, and shoulder. Radiologically, flocculent dense calcifications become evident in the periphery of the mass and eventually bone deposition sharply demarcates the periphery of the lesion in an eggshell-like fashion. Histopathologically, myositis ossificans is characterized by a zonal proliferation of fibroblasts and bone-forming osteoblastic elements that progresses through various stages over time which could not be observed in BPOP.

In summary, we present the first case of BPOP arising from the fifth rib region. Since these lesions are easily confused with other benign and malignant conditions, it is important to carefully evaluate their distinct clinical, radio-graphic and histopathologic features to avoid misdiagnosis. Complete surgical resection and long-term follow-up is essential due to the potential for local recurrence.

Acknowledgements

This work was supported by the Taizhou Soci-al Development Project Foundation, Jiangsu, China (grant No. TS028). The 333 Project of Scientific Research Project Foundation, Jiang-su, China (grant No. BRA2015224). The 12th Five-Year Plan Key Project of Science and Technology, China (grant No. 2013ZX1000-2007).

Disclosure of conflict of interest

None.

Address correspondence to: Dr. Chaofu Wang, De-partment of Pathology, Ruijin Hospital, Shanghai Jiaotong University School of Medicine, Shanghai, China. E-mail: wangchaofu@126.com; Dr. Xuhui Kong, Department of Ophthalmology, Taizhou Peo-ple's Hospital, Taizhou, Jiangsu Province, China. E-mail: tzkxh@sohu.com

References

- [1] Nora FE, Dahlin DC, Beabout JW. Bizarre par-osteal osteochondromatous proliferations of the hands and feet. *Am J Surg Pathol* 1983; 7: 245-250.
- [2] Meneses MF, Unni KK, Swee RG. Bizarre par-osteal osteochondromatous proliferation of bone (Nora's lesion). *Am J Surg Pathol* 1993; 17: 691-697.
- [3] Shankly PE, Hill FJ, Sloan P, Thakker NS. Bizarre parosteal osteochondromatous prolif-eration in the anterior maxilla: report of a case. *Oral Surg Oral Med Oral Pathol Oral Radiol Endod* 1999; 87: 351-356.
- [4] Bhalla VK, Coulson H, Parker W, Wynn J, Pipkin WL, Howell CG, Toscano M, Hatley RM. Popliteal pseudoaneurysm caused by Nora's lesion of the femur in a young child: a rare presentation and first report. *J Pediatr Surg* 2012; 47: e55-59.
- [5] Mors M, Cervantes SS, Hinni M. Bizarre paros-teal osteochondromatous proliferation pre-senting in the nasal dorsum. *J Oral Maxillofac Pathol* 2015; 19: 109-110.
- [6] Dashti Hm, Reith JD, Schlott BJ, Lewis EL, Cohen DM, Bhattacharyya I. Bizarre parosteal osteochondromatous proliferation(Nora's le-sion) of the mandible. A rare bony lesion. *Head Neck Pathol* 2012; 6: 264-269.
- [7] Shakib K, Kalsi H, Tsiridis E, Kumar M. Rare case of bizarre parosteal osteochondromatous proliferation presenting in the zygoma. *Br J Oral Maxillofac Surg* 2011; 49: e27-29.
- [8] Chamberlain AM, Anderson KL, Hoch B, Trumble TE, Weissstein JS. Benign bizarre par-

- osteal osteochondromatous proliferation of the hand originally diagnosed as osteochondroma: a report of two cases and review. *Hand (NY)* 2012; 5: 106-110.
- [9] Holmes C, Choksi P, Wrobel JS. Bizarre parosteal osteochondromatous proliferation: a novel case report of recurrence in the toe. *J Am Podiatr Med Assoc* 2015; 105: 80-84.
- [10] Teoh KH, Shortt N, Wilkinson G, Salter DM, Robb JE, Porter DE. Bizarre parosteal osteochondromatous proliferation of the metatarsal: a pediatric case report and archival review. *J Foot Ankle Surg* 2009; 48: 690, e7-690, e11.
- [11] Flint JH, McKay PL. Bizarre parosteal osteochondromatous proliferation and periosteal chondroma: a comparative report and review of the literature. *J Hand Surg Am* 2007; 32: 893-898.
- [12] Ting BL, Jupiter JB. Recurrent bizarre parosteal osteochondromatous proliferation of the ulna with erosion of the adjacent radius: case report. *J Hand Surg Am* 2013; 38: 2381-2386.