

Case Report

Skull metastasis of the clear cell variant of papillary thyroid carcinoma

Fan Li, Man Li, Yangyang Wang, Dandan Li, Jun Li, Hongwei Dang, Lijuan Pang, Jin Zhao

Department of Pathology, School of Medicine, Shihezi University, Shihezi, Xinjiang, China

Received January 21, 2016; Accepted April 22, 2016; Epub July 1, 2016; Published July 15, 2016

Abstract: Papillary thyroid carcinoma (PTC), which is characterized by low incidence of distant metastases, is a common subtype of thyroid carcinoma. Metastases of the clear cell variant (CCV), one of the many PTC variants, are rare. A 73-year-old woman with a 2-year history of a growing subcutaneous tumor in the right temporal region of her skull was admitted to our hospital; the tumor was initially speculated to be meningioma. She was simultaneously being investigated for thyroid mass, which was characterized by abnormal cells with large and atypical nuclei, as well as clear cytoplasm; this mass was considered thyroid cancer according to the result of fine needle aspiration cytology. The patient underwent surgery to remove the temporal mass, which was diagnosed to be skull metastasis of the CCV of PTC. The patient did not receive treatment after being discharged. During the follow-up period, the patient unfortunately passed away eighteen months after the operation. Given that little is known about metastases of the CCV of PTC, we will discuss the pathological and clinical features and further treatment of CCV. Distant metastases of the other PTC subtypes are usual, whereas aggressive behavior of CCV is rarely seen. Notably, the patient was admitted to our hospital because of skull metastasis. However, little is known about the primary focus. We identified the primary tumor through postoperative pathological examination of the skull metastasis. Facing with a skull mass, the clinician and pathologist should consider the possibility of metastasis.

Keywords: Papillary thyroid carcinoma, clear cell variant (CCV), skull metastasis

Introduction

Thyroid cancer (TC) accounts for approximately 2.1% of all cancers and is considerably more common in females than in males [1] at a male/female ratio of 1:3 among the Asian population [2]. TC has been classified into papillary thyroid carcinoma (PTC), follicular thyroid carcinoma, medullary thyroid carcinoma (MTC), and undifferentiated carcinoma. Among these subtypes, PTC is the most common, with the relative frequency increasing from 60% to 84.6% in the past decade [3]. PTC is an indolent tumor and seldom shows distant metastases. Once metastasis occurs, the disease-specific mortality rate increases up to 70.0% [4]. PTC has many variants, mainly including follicular variant, clear cell variant (CCV), diffuse sclerosis variant, tall cell variant and so on [5-7]. Among these variants, the follicular variant easily invades the meninges and eyes [8], whereas the tall cell variant is more aggressive [9, 10],

with a five-year survival worse than that of patients suffering from the other PTC variants [11]. Distant metastasis of the CCV is even less prevalent, with only one reported case involving the lung after total thyroidectomy [12]. We reported herein a 73-year-old woman with a 2-year history of skull metastasis of the CCV of PTC that occurred following a 50-year history of thyroid mass.

Case report

A 73-year-old woman with a 2-year history of a growing subcutaneous tumor in the right temporal region of her skull was admitted to our hospital. She had a medical history of hypertension and coronary heart disease. She was simultaneously being investigated for thyroid mass, which is characterized by abnormal cells with large and atypical nuclei, as well as clear cytoplasm; this mass was considered thyroid cancer according to the result of fine needle

The clear cell variant of papillary thyroid carcinoma

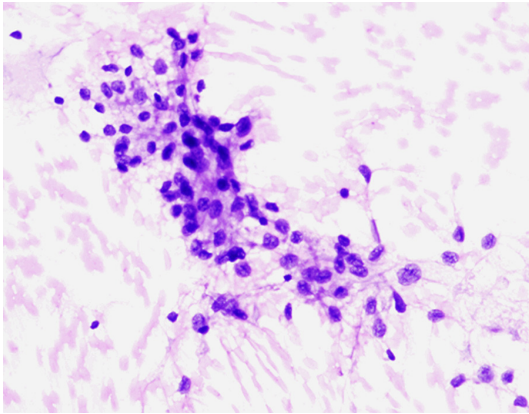


Figure 1. FNAC of the right thyroid mass showed the cells with large and atypical nuclei, as well as clear cytoplasm, which may be considered TC Original magnification, $\times 200$.

aspiration cytology (FNAC; **Figure 1**). Physical examination upon admission indicated a painless, poorly mobile, and hard mass in the right temporal region of the patient's skull. She was also alert and conscious. Neurological examination showed no abnormality.

Head computed tomography (CT) scan revealed a clear boundary, inhomogeneous density, and osteolytic lesion in her parietal-temporal bone (**Figure 2**). Head magnetic resonance imaging (MRI) revealed a 6.8 cm \times 4.7 cm heterogeneously enhanced mass, leading to osteolytic change extension to subcutaneous (**Figure 3**). Based on this radiological appearance, the mass was speculated to be a meningioma. Chest CT scan revealed multiple metastases in both lungs (**Figure 4A**). Thyroid ultrasonography (US) also revealed a bilaterally enlarged thyroid with diffuse lesions and multiple abnormal echoes. Cervical US revealed no metastasis in the cervical lymph node. To exclude possible metastasis from a distant site, chest X-ray of the patient was also obtained; the result was unremarkable.

Cerebral angiography showed that the tumor was hypervascular and was being fed mainly from several external branches of the jaw artery (**Figure 5A**). A day before the surgery, the patient underwent a transcatheter cerebral arterial embolization (TACE). Then, gelatin sponge and lipiodol embolization agent were poured into the arteries feeding the tumor (**Figure 5B**). The tumor, along with marginal skull, was success-

fully removed. The operation revealed that the tumor adhered tightly to the dura mater. Fortunately, the 6 cm \times 4 cm tumor did not invade the brain parenchyma. The postoperative recovery was also uneventful.

Postoperative pathological examination through hematoxylin and eosin (H&E) staining revealed that the CCV, a subtype of PTC, invaded the skull. Microscopy revealed a neoplasm comprising cells arranged in a papillary pattern. All tumor cells had a rich and clear cytoplasm, and the majority of the tumor cells displayed vacuolation (**Figure 6A**). Immunohistochemistry (IHC) also revealed positive results for thyroglobulin and TTF-1 immunoreactivity (**Figure 6B** and **6C**). CK19 and galectin-3 were also strongly expressed (**Figure 6D** and **6E**). By contrast, the results for calcitonin, glial fibrillary acidic protein (GFAP), and Syn were negative (**Figure 6F-H**). A definitive diagnosis of CCV metastasis was obtained based on either H&E and IHC or abnormal cell morphology of FNAC, as well as on the patient's medical history.

The patient did not receive adjuvant therapy after the surgery. Four months later, the patient was admitted again to our hospital. Head MRI showed no recurrence. However, compared with the previous result, chest CT scan revealed increased number and volume of metastases (**Figure 4B**).

After a four-month follow-up visit, the patient complained of dysphagia accompanied by painless swelling of the lateral neck region. Then, she passed away eighteen months after the operation.

Discussion

In the present case, a 73-year-old patient, who had a medical history of thyroid mass for 50 years and an abnormal FNAC result, underwent surgery because of skull metastasis. We discuss herein several of the interesting clinical features of this case.

In terms of the diagnosis, the primary focus of the confirmed diagnosis of the majority of previous cases was reported [12-14]. In this case, histological classification of the primary tumor origin was not made through postoperative pathological examination but was determined through the diagnosis of the metastatic tumor,

The clear cell variant of papillary thyroid carcinoma

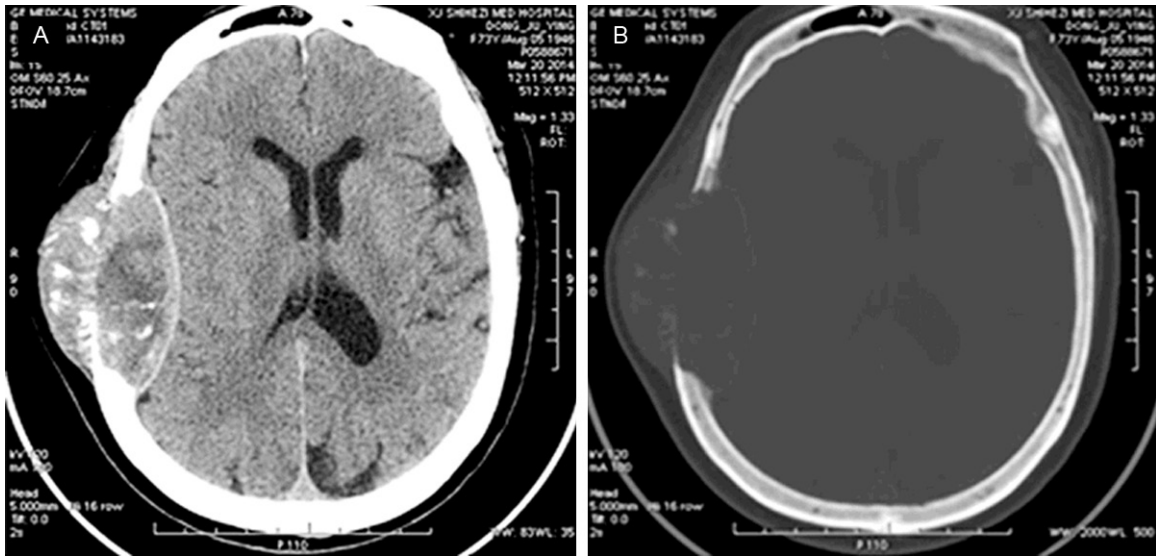


Figure 2. Cranial CT scan showed the clear boundary, inhomogeneous density, and osteolytic lesion in the parietal-temporal bone: transversal (A), axial sections and (B), bone window.

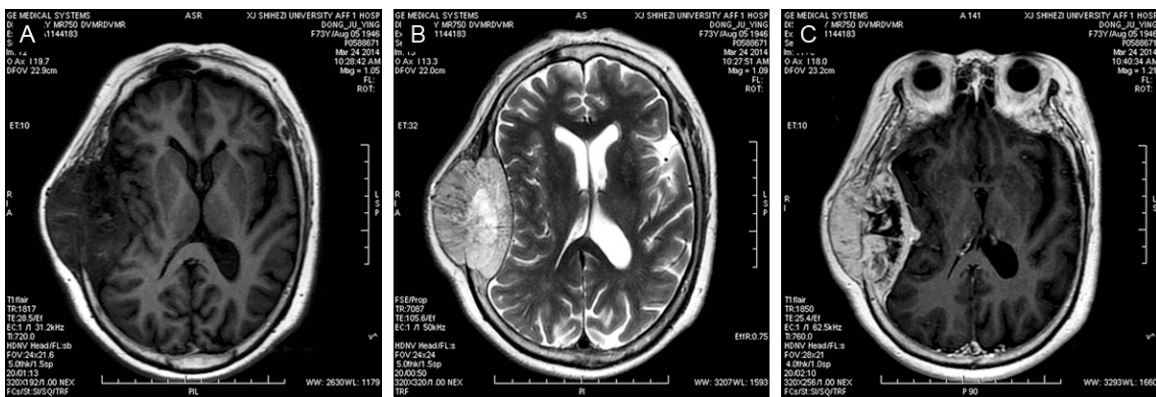


Figure 3. MRI revealed a 4.7 cm × 8.0 cm × 7.0 cm lesion, leading to osteolytic change extension to subcutaneous in the right side of the temporal bone. A. The mass exhibited a hypointense signal on axial T1-weighted image similar to the low-intensity T1-weighted signal detected in meningioma. B. Axial T2-weighted MRI showed that the extradural, bulging tumor has a slight contact with the brainstem. C. Contrast-enhanced axial T1-weighted MRI revealed evident enhancement, thickening of adjacent meninges, and compression of adjacent brainstem.

as well as based on the FNAC result and the patient's medical history.

IHC showed tumor tissues that highly expressed thyroglobulin and TTF-1 (**Figure 6B** and **6C**). Both markers verified that the skull metastasis originated from TC. The use of these markers is a specific and sensitive approach to differentiate lung adenocarcinoma from TC and thus prevents misdiagnosis [15]. The results for CK19 and galectin-3 immunoreactivity were positive, whereas that for calcitonin was negative (**Figure 6D-F**). These three markers contributed to the

histological classification of TC. The combination of CK19 and galectin-3 is the most sensitive for the diagnosis of PTC [16]. CK19 distinguishes PTC from follicular carcinomas [17]. The negative expression of calcitonin persuasively indicates PTC rather than MTC. Given that calcitonin is strongly expressed in MTC [18], it can lead to an earlier diagnosis of MTC than through the exclusive use of imaging procedures and/or FNAC [19]. GFAP also serves as a diagnostic marker for glioblastoma and is positively correlated with tumor volume [20]. Syn is a neuroendocrine marker [21]. In the

The clear cell variant of papillary thyroid carcinoma

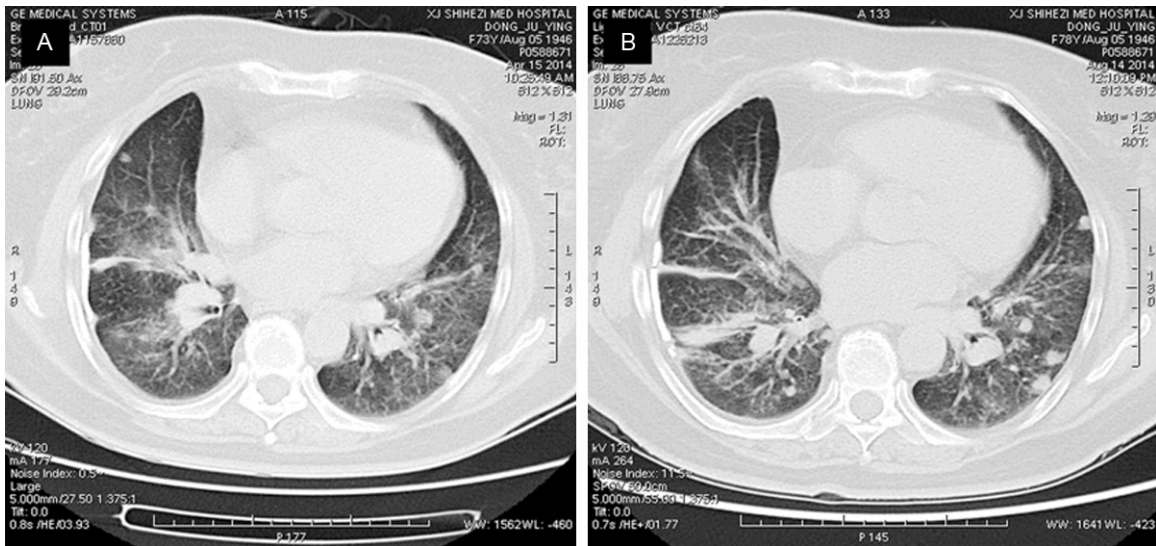


Figure 4. Result of chest CT about preoperation and postoperation made a comparison. A. Chest CT revealed multiple metastases in both lungs. B. The number and volume of metastases in both lungs increased four months after the surgery.

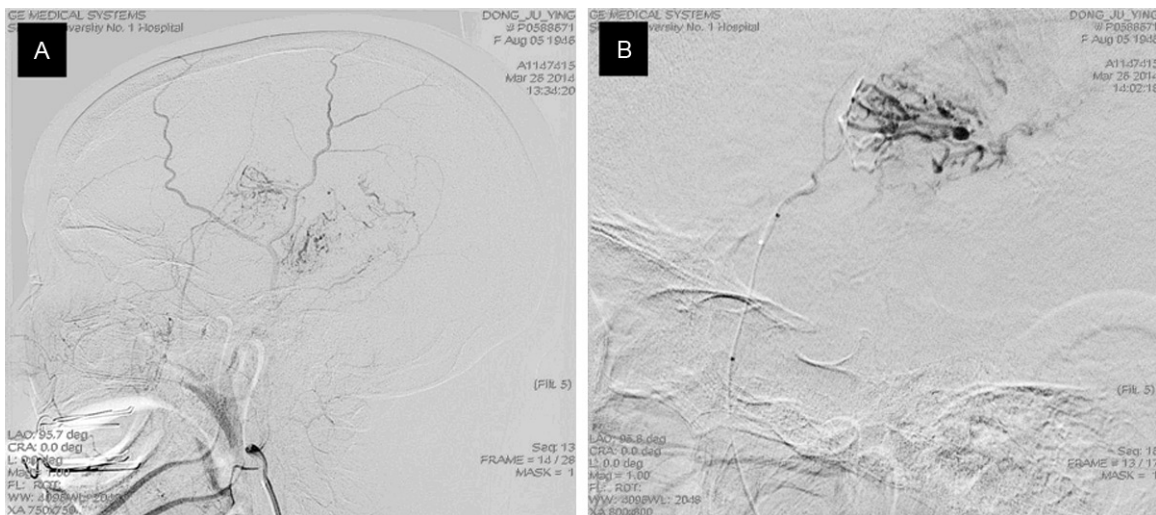


Figure 5. The patient underwent cerebral angiography and TACE. A. Cerebral angiography showed a rich blood supply around the tumor; the blood supply comes mainly from several external branches of the jaw artery. B. By using the Guidewire software, we poured the gelatin sponge and lipiodol embolization agent into the opening of the artery in front of and under the tumor.

present case, the negative expression of GFAP and Syn ruled out primary brain tumor and neuroendocrine tumor (**Figure 6G** and **6H**).

PTC is generally an indolent tumor, which is comparable to the 50-year medical history of the thyroid mass in the present case. PTC has many variants, mainly including the follicular variant, CCV, diffuse sclerosis variant, tall cell variant, and so on [5-7]. Among these variants,

the follicular variant easily invades the meninges and eyes [8], whereas the tall cell variant is more aggressive [9, 10], with a five-year survival worse than that of patients suffering from the other PTC variants [11]. Metastasis of the CCV of PTC to distant sites is an unusual clinical phenomenon, and only one case, which involves the lung after total thyroidectomy, has so far been reported [12]. This case is the first reported case of CCV metastasis to the skull.

The clear cell variant of papillary thyroid carcinoma

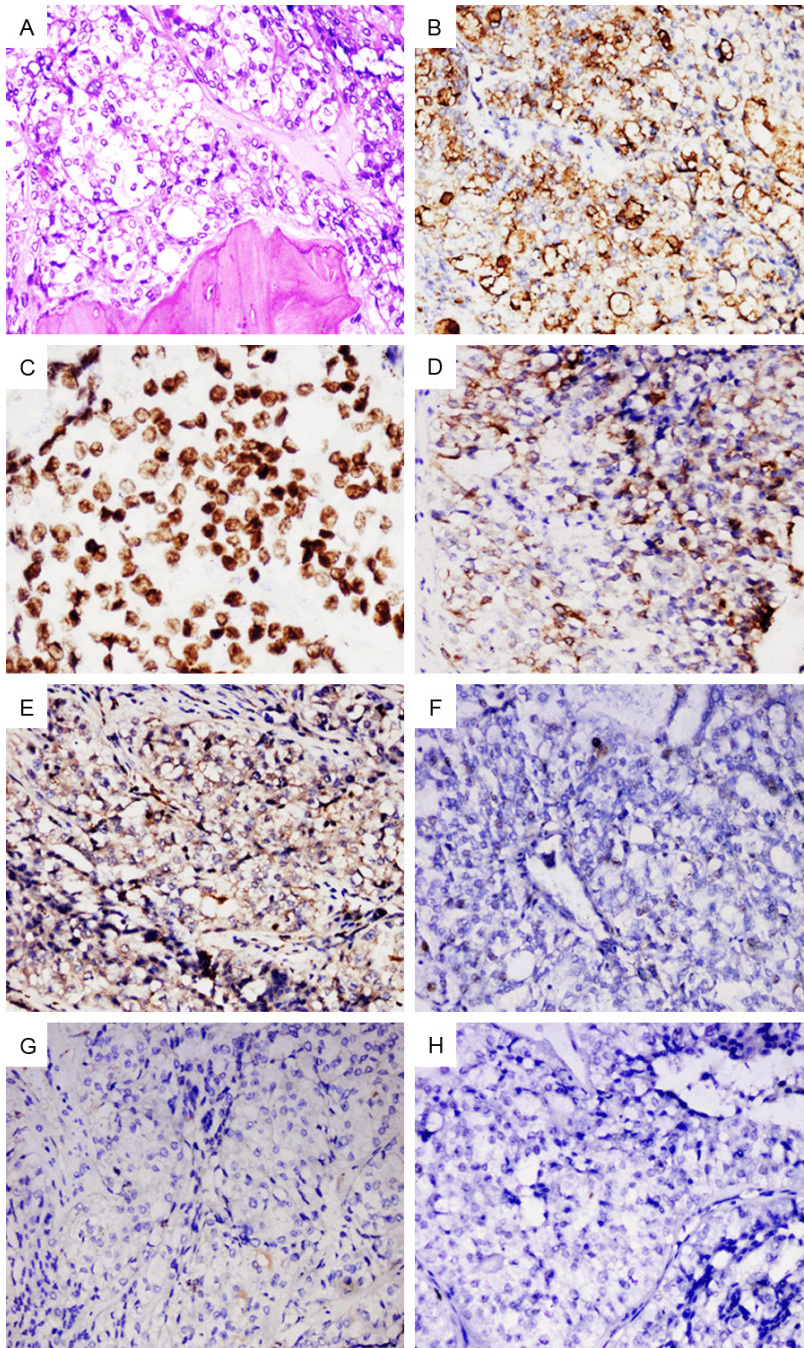


Figure 6. H&E and IHC detection of skull metastasis was described below. A. H&E showed metastasis of the CCV of PTC in the skull; the tumor plasma was characterized by vacuolation and invasion of the meninges. Original magnification, $\times 200$. B. IHC indicated a positive result for thyroglobulin immunoreactivity. Original magnification, $\times 400$. C. The result for TTF-1 nuclear immunoreactivity was positive, verifying metastasis of TC in the skull. Original magnification, $\times 400$. D. Immunoreactivity of CK19 was diffuse; CK19 also revealed strong expression. Original magnification, $\times 400$. E. Galectin-3 was also strongly expressed. Original magnification, $\times 400$. By contrast, F-H. The results for calcitonin, GFAP and Syn were negative. Original magnification, $\times 400$.

Our patient underwent TACE prior to tumor resection because TACE reduces operative bleed-

ing and allows easy removal of hypervascular tumors [22-24]. In previous studies (Table 1), thyroidectomy or (and) radioactive treatment was (were) administered after metastases [12-14, 25, 26]. In the present case, skull metastasis was removed, although the original focus still existed. Thus, surgeons should perform thyroidectomy to relieve esophageal compression symptoms and administer radioactive iodine (RAI) combined with rhTSH, a recombinant human thyroid-stimulating hormone, which can protect liver and renal function and reduce unnecessary exposure to radiation [27]. The administration of RAI following surgery improves the overall survival of patients [28]. However, the RAI dose should be carefully determined; otherwise, many complications may occur [29, 30]. For patients 70 years old or older, the administered dose should not exceed 250 mCi [31].

FNAC is a simple, less invasive method exhibiting high accuracy of thyroid lesion diagnosis [32-34]. In the present case, FNAC clearly revealed cells with large and atypical nuclei, as well as clear cytoplasm, which may be considered TC (Figure 1). US is the most common method employed to diagnose thyroid disease. Zhang and colleagues [35] conducted a research among a total of 407 TC cases, and the diagnostic rate of

PTC using US was 82.5%. US also revealed that PTC had a high prevalence of calcification.

The clear cell variant of papillary thyroid carcinoma

Table 1. Treatment for PTC variants

Variant	Age	Sex	Metastases position	Treatment after metastases	Result	Follow-up
Follicular [14]	68	Female	Liver metastases	RAI and removal of liver lesion	Doing well one year after surgery	One year
Macrofollicular [25]	48	Female	Lung metastases	Thyroidectomy and RAI	Asymptomatic	NA
Clear cell [12]	49	Female	Lung metastases	rhTSH and RAI	Number and size of metastases decreasing	NA
Diffuse sclerosis [26]	61	Female	Multiple metastases ^{aa}	rhTSH and RAI	CEA level decreasing mildly	NA
Oxyphilic [13]	15	Female	Multiple metastases ^{bb}	High-dose RAI	No leukemia or secondary malignancy	Eight years

Note: aa: lymph nodes, brain, bone, liver, and lung metastases. bb: brain, skeleton, lungs, and soft tissue metastases. NA: not available.

However, US provided no definite diagnosis in the present case. This phenomenon may be caused either by the absence of typical US feature in the PTC or by the lack of competence of our hospital's physicians.

Distant metastases of other PTC subtypes is common, whereas aggressive behavior of CCV is rarely observed. Notably, the patient was admitted to our hospital because of metastatic skull tumor, and little is known about the primary focus. Eventually, we identified the primary tumor through postoperative pathological examination of skull metastasis. Faced with a skull mass, the clinician and pathologist should consider the possibility of metastasis. Clinical material on CCV has not yet been collected and analyzed. Thus, researchers should focus on CCV patients. However, whether CCV should be considered a distinct clinicopathologic entity and whether CCV still holds a favorable prognosis remain a matter of continuing debate.

Acknowledgements

This work was supported by the Shihezi University Youth Science and Technology Talent Cultivation Plan of Foundational Applications Research (number 2015ZRKXYQ19).

Disclosure of conflict of interest

None.

Address correspondence to: Dr. Jin Zhao, Department of Pathology, School of Medicine, Shihezi University, Shihezi, China. Tel: +86-135-7974-4456; Fax: +86-993-205-7136; E-mail: 1505108219@qq.com

References

[1] Ferlay J, Soerjomataram I, Dikshit R, Eser S, Mathers C, Rebelo M, Parkin DM, Forman D and Bray F. Cancer incidence and mortality worldwide: Sources, methods and major pat-

terns in GLOBOCAN 2012. *Int J Cancer* 2015; 136: E359-386.

[2] Krook KA, Fedewa SA and Chen AY. Prognostic indicators in well-differentiated thyroid carcinoma when controlling for stage and treatment. *Laryngoscope* 2015; 125: 1021-7.

[3] Pazaitou-Panayiotou K, Iliadou PK, Chrisoulidou A, Mitsakis P, Doumala E, Fotareli A, Boudina M, Mathiopoulou L, Patakiouta F and Tziomalos K. The increase in thyroid cancer incidence is not only due to papillary microcarcinomas: a 40-year study in 1 778 patients. *Exp Clin Endocrinol Diabetes* 2013; 121: 397-401.

[4] Lin JD, Hsueh C and Chao TC. Long-Term Follow-Up of the Therapeutic Outcomes for Papillary Thyroid Carcinoma With Distant Metastasis. *Medicine (Baltimore)* 2015; 94: e1063.

[5] Bukhari MH, Niazi S, Anwar M and Nasir A. An audit of local experience, histological classification of primary tumours of the thyroid according to WHO revised criteria with a critical account. *Histopathology* 2009; 55: 120-124.

[6] Duskova J. Known pitfalls of the thyroid neoplasm diagnostics in the view of the new (2004) WHO Classification. *Cesk Patol* 2006; 42: 24-28.

[7] Ito Y, Hirokawa M, Uruno T, Kihara M, Higashiyama T, Takamura Y, Miya A, Kobayashi K, Matsuzuka F and Miyauchi A. Prevalence and biological behaviour of variants of papillary thyroid carcinoma. *Pathology* 2008; 40: 617-622.

[8] Madani A, Jozaghi Y, Tabah R, How J and Mitmaker E. Rare Metastases of Well-Differentiated Thyroid Cancers: A Systematic Review. *Ann Surg Oncol* 2014; 22: 460-466.

[9] Beninato T, Scognamiglio T, Kleiman DA, Uccelli A, Vaca D, Fahey TJ 3rd and Zarnegar R. Ten percent tall cells confer the aggressive features of the tall cell variant of papillary thyroid carcinoma. *Surgery* 2013; 154: 1331-1336; discussion 1336.

[10] Ganly I, Ibrahimasic T, Rivera M, Nixon I, Palmer F, Patel SG, Tuttle RM, Shah JP and Ghossein R. Prognostic implications of papillary thyroid carcinoma with tall-cell features. *Thyroid* 2014; 24: 662-670.

The clear cell variant of papillary thyroid carcinoma

- [11] Axelsson TA, Hrafnkelsson J, Olafsdottir EJ and Jonasson JG. Tall Cell Variant of Papillary Thyroid Carcinoma: A Population-Based Study in Iceland. *Thyroid* 2015; 25: 216-20.
- [12] Lee JI, Chung YJ, Park SJ, Ryu HS and Cho BY. Euthyroid Status After Total Thyroidectomy Due to Functioning Lung Metastases from a Clear Cell Variant of Papillary Thyroid Carcinoma. *Thyroid* 2012; 22: 1084-1087.
- [13] Vrachimis A, Schmid KW, Jurgens H, Schober O, Weckesser M and Riemann B. Cerebral metastases from thyroid carcinoma: complete remission following radioiodine treatment. *Dtsch Arztebl Int* 2013; 110: 861-866.
- [14] Djenic B, Duick D, Newell JO and Demeure MJ. Solitary liver metastasis from follicular variant papillary thyroid carcinoma: A case report and literature review. *Int J Surg Case Rep* 2015; 6C: 146-149.
- [15] Sathiyamoorthy S and Maleki Z. Cytomorphologic overlap of differentiated thyroid carcinoma and lung adenocarcinoma and diagnostic value of TTF-1 and TGB on cytologic material. *Diagn Cytopathol* 2014; 42: 5-10.
- [16] Wu G, Wang J, Zhou Z, Li T and Tang F. Combined staining for immunohistochemical markers in the diagnosis of papillary thyroid carcinoma: improvement in the sensitivity or specificity? *J Int Med Res* 2013; 41: 975-983.
- [17] Isic Dencic T, Cvejic D, Paunovic I, Tatic S, Havelka M and Savin S. Cytokeratin19 expression discriminates papillary thyroid carcinoma from other thyroid lesions and predicts its aggressive behavior. *Med Oncol* 2013; 30: 362.
- [18] Feng J and Wang J. [Expression and clinical significance of Ki67 and calcitonin in medullary thyroid carcinoma]. *Lin Chung Er Bi Yan Hou Tou Jing Wai Ke Za Zhi* 2014; 28: 1921-1924.
- [19] Bae YJ, Schaab M and Kratzsch J. Calcitonin as Biomarker for the Medullary Thyroid Carcinoma. *Recent Results Cancer Res* 2015; 204: 117-137.
- [20] Tichy J, Spechtmeyer S, Mittelbronn M, Hattingen E, Rieger J, Senft C and Foerch C. Prospective evaluation of serum glial fibrillary acidic protein (GFAP) as a diagnostic marker for glioblastoma. *J Neurooncol* 2016; 126: 361-9.
- [21] Wang Z, Li W, Chen T, Yang J, Luo L, Zhang L, Sun B and Liang R. Retrospective analysis of the clinicopathological characteristics of gastrointestinal neuroendocrine neoplasms. *Exp Ther Med* 2015; 10: 1084-1088.
- [22] Yoshimura J, Tsukamoto Y, Sano M, Hasegawa H, Nishino K, Saito A, Fukuda M, Okamoto K and Fujii Y. Successful removal of a huge hypervascular tentorial cavernous angioma after preoperative endovascular embolization. *J Neurosurg Pediatr* 2014; 14: 43-47.
- [23] Isozumi T, Kidooka M, Lee H, Fukao S, Ito S and Minamikawa T. [Stepwise improvement of visual field after preoperative embolization and tumor resection of cerebral metastasis of alveolar soft part sarcoma]. *Brain Nerve* 2013; 65: 1515-1520.
- [24] Hirohata M, Abe T, Fujimura N, Takeuchi Y and Shigemori M. Preoperative embolization of brain tumor with pial artery or dural branch of internal carotid artery as feeding artery. *Interv Neuroradiol* 2006; 12: 246-251.
- [25] Marques P, Leite V and Bugalho MJ. Remarkable response to radioiodine therapy in a case of metastatic macrofollicular variant of papillary thyroid carcinoma. *Clin Nucl Med* 2014; 39: 219-221.
- [26] Kuo CS, Tang KT, Lin JD, Yang AH, Lee CH and Lin HD. Diffuse sclerosing variant of papillary thyroid carcinoma with multiple metastases and elevated serum carcinoembryonic antigen level. *Thyroid* 2012; 22: 1187-1190.
- [27] Lee SJ, Lee HY, Lee WW and Kim SE. The effect of recombinant human thyroid stimulating hormone on sustaining liver and renal function in thyroid cancer patients during radioactive iodine therapy. *Nucl Med Commun* 2014; 35: 727-732.
- [28] Ruel E, Thomas S, Dinan M, Perkins JM, Roman SA and Ann Sosa J. Adjuvant radioactive iodine therapy is associated with improved survival for patients with intermediate risk papillary thyroid cancer. *J Clin Endocrinol Metab* 2015; jc20144332.
- [29] Lee HN, An JY, Lee KM, Kim EJ, Choi WS and Kim DY. Salivary gland dysfunction after radioactive iodine (I-131) therapy in patients following total thyroidectomy: emphasis on radioactive iodine therapy dose. *Clin Imaging* 2015; 39: 396-400.
- [30] Fard-Esfahani A, Emami-Ardekani A, Fallahi B, Fard-Esfahani P, Beiki D, Hassanzadeh-Rad A and Eftekhari M. Adverse effects of radioactive iodine-131 treatment for differentiated thyroid carcinoma. *Nucl Med Commun* 2014; 35: 808-817.
- [31] Tuttle RM, Leboeuf R, Robbins RJ, Qualey R, Pentlow K, Larson SM and Chan CY. Empiric radioactive iodine dosing regimens frequently exceed maximum tolerated activity levels in elderly patients with thyroid cancer. *J Nucl Med* 2006; 47: 1587-1591.
- [32] Sinna EA and Ezzat N. Diagnostic accuracy of fine needle aspiration cytology in thyroid lesions. *J Egypt Natl Canc Inst* 2012; 24: 63-70.
- [33] Rathod GB and Parmar P. Fine needle aspiration cytology of swellings of head and neck region. *Indian J Med Sci* 2012; 66: 49-54.
- [34] Rahimi M, Farshchian N, Rezaee E, Shahebrahimi K and Madani H. To differentiate benign from malignant thyroid nodule comparison of sonography with FNAC findings. *Pak J Med Sci* 2013; 29: 77-80.

The clear cell variant of papillary thyroid carcinoma

- [35] Zhang S, Zheng XQ, Wei X, Zhao J, Zhang Y and Gao M. Evaluation of ultrasound application in diagnosis and clinical staging of thyroid cancers. *Indian J Cancer* 2014; 51: 193-199.