

Case Report

Primary pleomorphic liposarcoma of liver: a case report and review of the literature

Lingjiao Chen, Jiadi Luo, Qiuyuan Wen, Shuzhou Chu, Weiyan Wang, Songqing Fan

Department of Pathology, The Second Xiangya Hospital, Central South University, Changsha, Hunan, China

Received January 29, 2016; Accepted May 20, 2016; Epub July 1, 2016; Published July 15, 2016

Abstract: Pleomorphic liposarcoma is an uncommon form of liposarcoma that rarely occurs in liver, especially the primary pleomorphic liposarcoma of liver. In the current work, we presented a case of primary pleomorphic liposarcoma of liver in a 43-year-old male with the history of abdominal tumor. Microscopically, the tumor consisted of pleomorphic spindle shaped tumor cells and fascicles of spindled and smaller, round cells admixed with multinucleated giant cells. Immunohistochemical staining of Vimentin, S-100 and p53 were positive, also, the tumor had a higher mean Ki-67 proliferation index. Other markers including pan-CK, CK18, CAM5.2, CDX-2, Villin, EMA, CD34, SMA, CD117, CD68, lysozyme, AFP, HMB45, HBsAg and HBeAg were all negative staining. We also reviewed this tumor in different organs which have been published in the literature.

Keywords: Liposarcoma, pleomorphic liposarcoma, hepatic malignancy, primary pleomorphic liposarcoma of liver, liver

Introduction

Pleomorphic liposarcoma is a high-grade malignant tumor which originated from mesenchymal tissue. This kind of tumor can be occurred in multiple parts of the body, such as extremity, brain, mediastinum, mesentery, in which the extremity accounts for the largest proportion [1], but it is absolutely rare in the liver. So far, only one case primary pleomorphic liposarcoma of liver in human have been reported in the English literature which published in 2013 [2]. Patients with primary pleomorphic liposarcoma of liver usually presented with a painless mass detected when medical examination [3]. It cannot be confirmed until the pathological examination had been completed. We herein present the second case of primary pleomorphic liposarcoma of liver in a 43-year-old male.

Case presentation

A 43-year-old male presented with the history of upper abdominal pain more than 2 months. The patient depicted spontaneous upper abdominal pain without other discomfort, but he had exacerbation of symptoms following heavy physical activity. Without any treatment,

the patient felt the symptom aggravating before coming to our hospital. An abdominal computed tomography (CT) scan discovered a large, heterogeneously enhancing mass in the left lobe of liver, which broke through liver capsule and invaded into diaphragm and mediastinum (**Figure 1**). Clinical examination and routine laboratory screening (include the function of liver: glutamic-pyruvic transaminase (ALT) 20.3 u/l, glutamic-oxalacetic transaminase (AST) 25.8 u/l) were all in normal range.

A surgical resection of the left liver was performed, revealing a non-enveloped solitary mass measuring 16×15×11 cm, weighing about 1.9 kg. The cut surface of the mass was gray-white, medium texture and the poor-circumscribed (**Figure 2**). Microscopically, the tumor consisted of pleomorphic spindle shaped tumor cells and fascicles of spindled and smaller, round cells admixed with multinucleated giant cells. The tumor cells had prominent atypia and copious mitosis (>20/10 HPF). No obvious necrosis was observed in any of the sections (**Figure 3A-D**).

To help diagnose the disease, immunohistochemical staining was performed using an

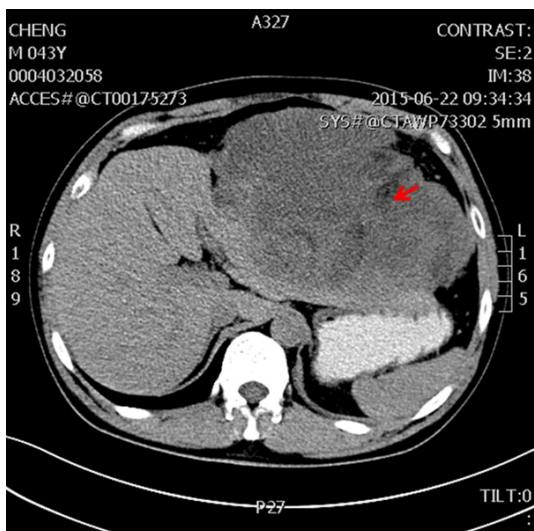


Figure 1. Abdominal computed tomography (CT) scan discovered a large, heterogeneously enhancing mass (red arrow) in the left lobe of liver, which broke through liver capsule and invaded into diaphragm and mediastinum.

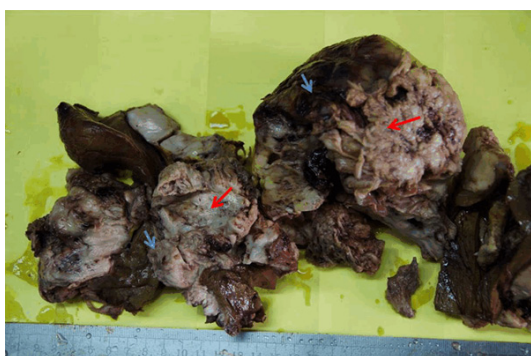

Figure 2. Gross appearance of primary pleomorphic liposarcoma of liver, the cut surface of tumor is gray-white (red arrow) and the poorly-circumscribed (green arrow).

automated immunostainer (Ventana Benchmark XT; Ventana Medical Systems, Inc, Tucson, AZ). These primary antibodies, such as Vimentin, CDX-2, Villin, epithelial membrane antigen (EMA), pan-cytokeratin (pan-CK), cytokeratin 18(CK18), CAM5.2, AFP, S-100, CD117, CD68, lysozyme, CD34, HBsAg, HbAg, SMA, Ki-67, and p53 were hired for differential diagnosis. The pleomorphic liposarcoma tumor cells were positive for Vimentin (**Figure 4A**) and S-100 (**Figure 4B**). In addition, the pleomorphic liposarcoma of liver had a higher mean Ki-67 proliferation index (85% positive staining tumor cells) (**Figure 4C**) and strong positive expres-

sion of P53 protein. While negative staining for pan-CK (**Figure 4D**), CK18, CAM5.2, CDX-2, Villin, EMA, CD34, SMA, CD117, CD68, lysozyme, AFP, HMB45, HBsAg and HbAg were identified in the tumor cells. Also, the tumor cells was positive for fat dyeing (Sudan III dyeing) (**Figure 5**).

Based on the clinical manifestation, imageological examination, microscopic findings and immunohistochemical staining and fat dyeing, we made the diagnosis of primary pleomorphic liposarcoma of liver. The patient died of abdominal cavity implantation metastasis (9 months after operation).

Discussion

Malignant tumor in the liver can be divided into primary and metastatic types, while histologically it is also classified epithelial origin, mesenchymal origin, mixed origin and others. Well-known, it is hepatocellular carcinoma that takes up the biggest part of hepatic malignant tumor. However, mesenchymal tissue-tumor in liver is relatively infrequent. Liposarcoma is a kind of malignant neoplasm originated from mesenchymal tissue. World Health Organization (WHO) divides primary liposarcoma into four subtypes: myxoid liposarcoma, well-differentiated liposarcoma, dedifferentiated liposarcoma and pleomorphic liposarcoma. All these subtypes should be identified through histopathology. Pleomorphic liposarcoma is the most rare type only accounting for 5 percent of all liposarcoma [4] and 20 percent of pleomorphic sarcomas [5]. According to what we have retrieved, few pleomorphic liposarcoma of liver have been reported in the English literature, in which there is only one case of primary pleomorphic liposarcoma of liver in human [2]. On the whole, pleomorphic liposarcoma usually arise from the extremities (lower extremity more than upper extremity) [3, 6-9], but rare in liver, breast, pericardium, mesentery, inferior vena cava, neck, orbit, mediastinal, intracranial dura mater, uterus and so on [2, 10-18]. Tumor size ranged from 1.5 to 31 cm, especially retroperitoneal/intra-abdominal tumors which were generally large [6, 8]. The cut surface of the masses is firm, nodular, gray-white to yellow, medium texture with the boundary clarity. Age of patients of pleomorphic liposarcoma ranged from 11 to 95 years with a slight male predominance [8, 19].

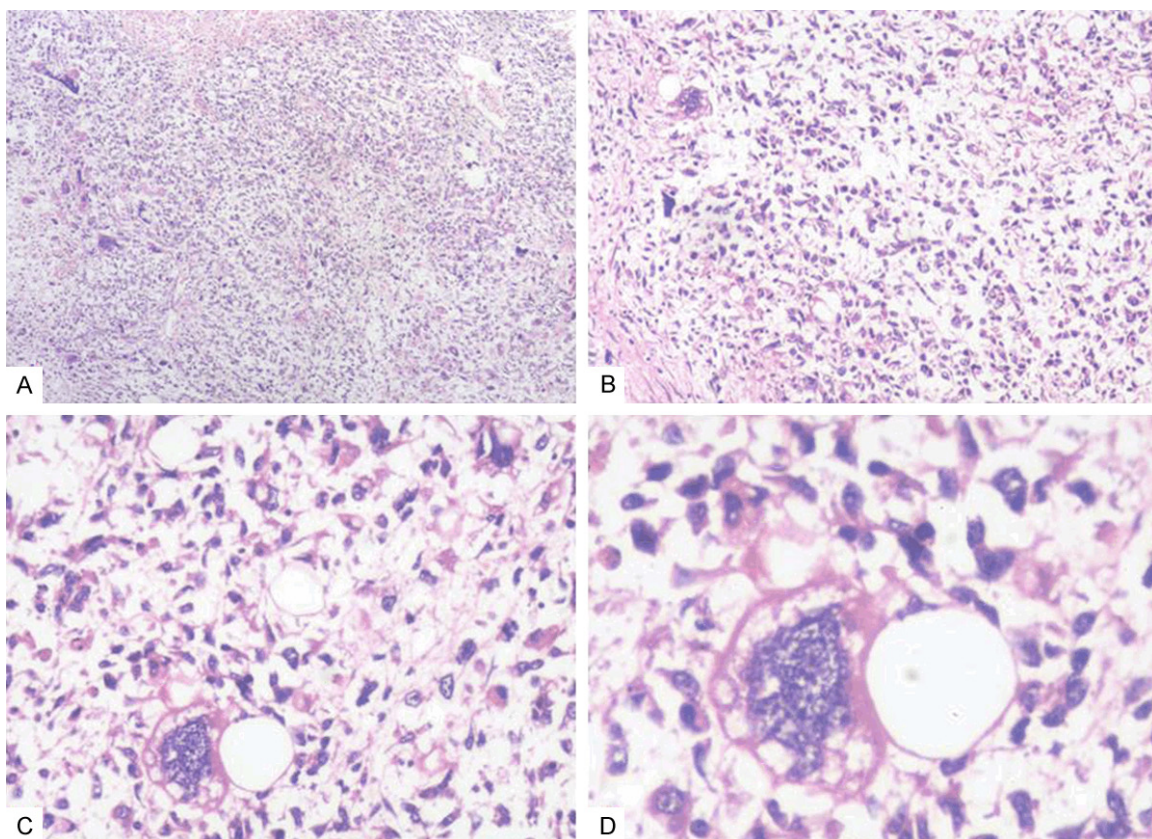


Figure 3. Microscopically, the tumor consisted of pleomorphic spindle shaped tumor cells and fascicles of spindled and smaller, round cells admixed with multinucleated giant cells. The tumor cells showed prominent atypia and copious mitosis ($>20/10$ HPF). No obvious necrosis was observed in any of the sections (H&E staining, A: 40 \times , B: 100 \times , C: 200 \times , D: 400 \times).

Most patients with pleomorphic liposarcoma have no obvious symptoms at presentation especially deeply locate [19]. There are not distinctive changes in clinical examination and routine laboratory screening, which makes it more difficult to diagnose. Radiological examination, such as ultrasonic inspection, computed tomography (CT), magnetic resonance imaging (MRI), can usually be helpful for the estimate of benign or malignant, when it shows huge space-occupying lesions. It is no doubt that clinical doctor will take liver cancer into consideration firstly. The only way to distinguish pleomorphic liposarcoma of liver from cancer is pathology examination. Typically, pleomorphic liposarcoma had highly rich various cells such as multivacuolated lipoblasts, multinucleated giant cells and pleomorphic spindle cell under microscopy by H&E staining [1, 3, 6, 8]. Just like the case we presented, fat dyeing (Sudan III dyeing) performed confirmed fat origin of the tumor. Supplementary IHC had been done which showed strong positivity for Vimentin and focal positive for S-100.

Pathologic distinction between hepatocellular carcinoma or gallbladder cancer and the primary pleomorphic liposarcoma of liver was made. H&E staining of the liver cancer display atypical hepatic cells and/or biliary epithelial cells, and they are character with specific immunohistochemical phenotypes for hepatic cell cancer (Hepatocyte, α -Fetoprotein, Glypican-3) and biliary epithelial cell cancer (Cytokeratin, Cytokeratin 20). Therefore, the pleomorphic liposarcoma cells can be differentiated from hepatocellular carcinoma confirmed by IHC (Vimentin and S-100) and fat dyeing. Therefore, IHC and special stains are essential except for routine H&E staining [2].

At present, surgical resection is the most commonly used treatment for pleomorphic liposarcoma [3, 6, 8]. Several factors, like tumor site, tumor size, primary or recurrent, localized or metastatic disease, nuclear fission active, affect patient's prognosis with pleomorphic liposarcoma. The reported 5-year overall survival rates of pleomorphic liposarcoma patients

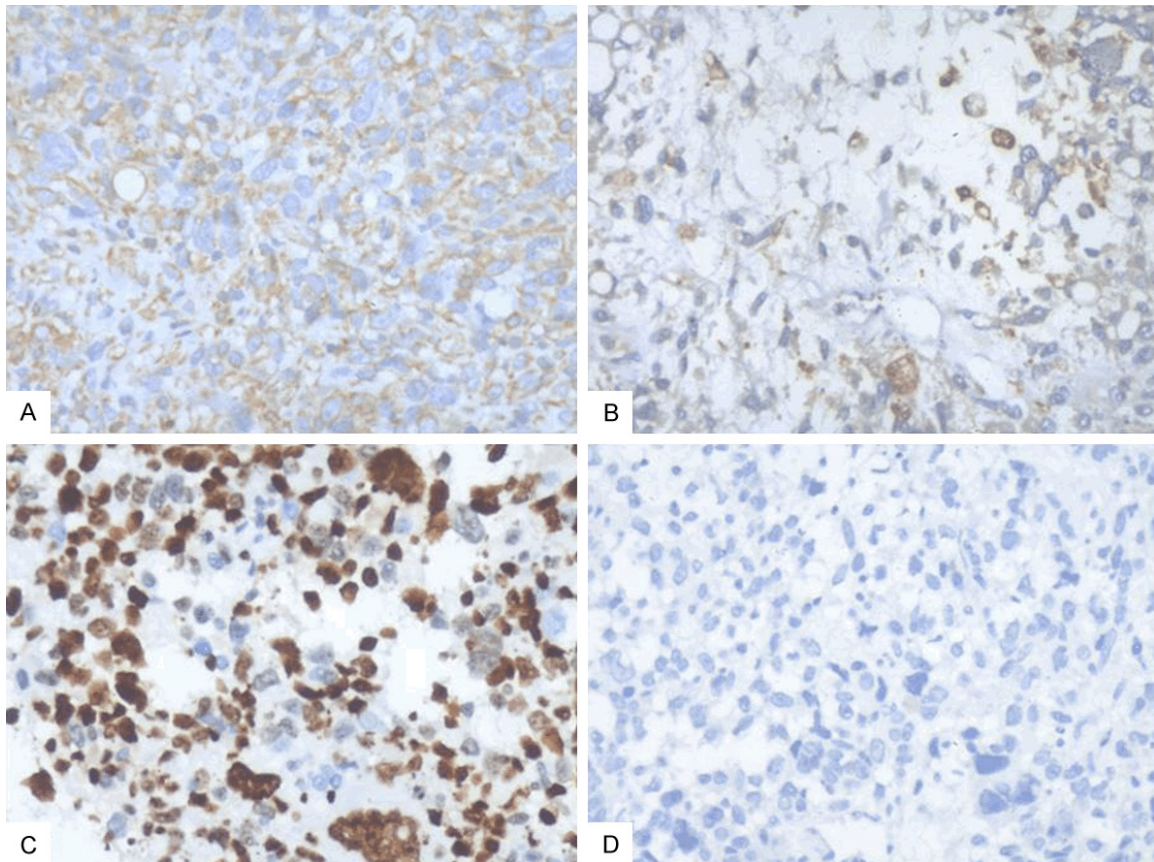


Figure 4. The immunohistochemical phenotypes of primary pleomorphic liposarcoma in human liver were showed. A: Strong positive expression of Vimentin in the cytoplasm of tumor cells (IHC, DAB staining, 200×). B: The scattered positive staining for S-100 was observed in the cytoplasm and nucleus of tumor cells (IHC, DAB staining, 200×). C: The tumor cells had a higher mean Ki-67 proliferation index (85% tumor cells staining for Ki-67 in the cell nucleus) (IHC, DAB staining, 200×). D: The pleomorphic liposarcoma of liver was negative for CK (IHC, DAB staining, 200×).

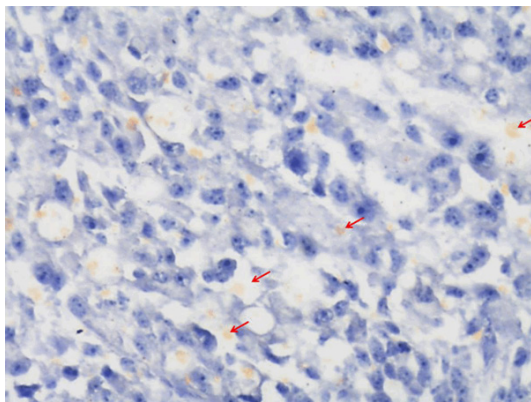


Figure 5. Dyed orange lipid drops (red arrow) with fat dyeing (Sudan III dyeing) scattered in the pleomorphic liposarcoma cell cytoplasm (200×).

ranged from 16% to 65% in the literatures [6, 7]. Immunohistochemical analysis of the pleomorphic liposarcoma reveals strong positive for Vimentin, about 33% to 91% cases of pleo-

morphic liposarcoma are positive for S-100, 13.3% to 45% for smooth muscle action (SMA). However, about 0-21% cases of pleomorphic liposarcoma are focally positive for cytokeratin (CK), 0-38% for epithelial membrane antigen (EMA) and 0-13% for Desmin. Ki-67 proliferation rate varied from 10% to 85% in the pleomorphic liposarcoma.

In summary, the primary pleomorphic liposarcoma of liver is an extremely rare, high-grade and aggressive tumor. It is clinically silent and is usually discovered incidentally on abdominal imaging. Combination histopathological examination, IHC and fat dyeing contribute significant effect on the accurate diagnosis.

Acknowledgements

The work was supported by grants from the National Natural Sciences Foundations of China (NO: 81272566; 81472773).

Disclosure of conflict of interest

None.

Address correspondence to: Dr. Songqing Fan, Department of Pathology, The Second Xiangya Hospital, Central South University, Changsha, Hunan, China. E-mail: songqingfan2000@yahoo.com

References

- [1] Oliveira AM, Nascimento AG. Pleomorphic liposarcoma. *Semin Diagn Pathol* 2001; 18: 274-85.
- [2] Naik PR, Kumar P, Kumar PV. Primary pleomorphic liposarcoma of liver: a case report and review of the literature. *Case Reports Hepatol* 2013; 2013: 398910.
- [3] Wang L, Ren W, Zhou X, Sheng W, Wang J. Pleomorphic liposarcoma: a clinicopathological, immunohistochemical and molecular cytogenetic study of 32 additional cases. *Pathol Int* 2013; 63: 523-531.
- [4] Azumi N, Curtis J, Kempson RL, Hendrickson MR. Atypical and malignant neoplasms showing lipomatous differentiation. A study of 111 cases. *Am J Surg Pathol* 1987; 11: 161-183.
- [5] Fletcher CD. Pleomorphic malignant fibrous histiocytoma: fact or fiction? A critical reappraisal based on 159 tumors diagnosed as pleomorphic sarcoma. *Am J Surg Pathol* 1992; 16: 213-228.
- [6] Downes KA, Goldblum JR, Montgomery EA, Fisher C. Pleomorphic liposarcoma: a clinicopathologic analysis of 19 cases. *Mod Pathol* 2001; 14: 179-184.
- [7] Ghadimi MP, Liu P, Peng T, Bolshakov S, Young ED, Torres KE, Colombo C, Hoffman A, Broccoli D, Hornick JL, Lazar AJ, Pisters P, Pollock RE, Lev D. Pleomorphic liposarcoma: clinical observations and molecular variables. *Cancer* 2011; 117: 5359-5369.
- [8] Hornick JL, Bosenberg MW, Mentzel T, McMenamin ME, Oliveira AM, Fletcher CD. Pleomorphic liposarcoma: clinicopathologic analysis of 57 cases. *Am J Surg Pathol* 2004; 28: 1257-1267.
- [9] Gebhard S, Coindre JM, Michels JJ, Terrier P, Bertrand G, Trassard M, Taylor S, Château MC, Marquès B, Picot V, Guillou L. Pleomorphic liposarcoma: clinicopathologic, immunohistochemical, and follow-up analysis of 63 cases: a study from the French Federation of Cancer Centers Sarcoma Group. *Am J Surg Pathol* 2002; 26: 601-616.
- [10] Mardi K, Gupta N. Primary pleomorphic liposarcoma of breast: a rare case report. *Indian J Pathol Microbiol* 201; 54: 124-126.
- [11] Wang JG, Wei ZM, Liu H, Li YJ. Primary pleomorphic liposarcoma of pericardium. *Interact Cardiovasc Thorac Surg* 2010; 11: 325-327.
- [12] Choi JY, Kim JE, Lee SM, Kang HJ, Sung JH, Koh BS, Park JS, Kim ID, Baik SY. [A case of pleomorphic liposarcoma originating from mesentery]. *Korean J Gastroenterol* 2015; 65: 182-185.
- [13] Senapati GM, Sheiman RG, Almashat S, Goldsmith JD. Pleomorphic liposarcoma of the inferior vena cava. *Radiographics* 2015; 35: 269-74.
- [14] Creytens D, van Gorp J, Ferdinande L, Van Roy N, Libbrecht L. Array-based comparative genomic hybridization analysis of a pleomorphic myxoid liposarcoma. *J Clin Pathol* 2014; 67: 834-835.
- [15] Doyle M, Odashiro AN, Pereira PR, Odashiro M, Kobayashi F, Shinzato I, Burnier MN Jr. Primary pleomorphic liposarcoma of the orbit: a case report. *Orbit* 2012; 31: 168-170.
- [16] Barbetakis N, Asteriou C, Kleontas A, Karvelas C. Primary pleomorphic liposarcoma: a rare mediastinal tumor. *Interact Cardiovasc Thorac Surg* 2010; 11: 327.
- [17] Mumert ML, Walsh MT, Jensen EM, Jensen RL. Pleomorphic liposarcoma originating from intracranial dura mater. *J Neurooncol* 2010; 97: 149-153.
- [18] Levine PH, Wei XJ, Gagner JP, Flax H, Mittal K, Blank SV. Pleomorphic liposarcoma of the uterus: case report and literature review. *Int J Gynecol Pathol* 2003; 22: 407-411.
- [19] Dodd LG, Sara Jiang X, Rao K, Bui MM. Pleomorphic liposarcoma: a cytologic study of five cases. *Diagn Cytopathol* 2015; 43: 138-143.