

Case Report

Cellular angiofibroma of the kidney: a case report and review of the literature

Man Yu¹, Ai-Jun Yu², Zhi-Yong Wang¹, Xing-Bin Shen³, Ze-Min Wang¹, Dian-Bin Song¹, Hui Xu¹

Departments of ¹Urology, ²Hepatobiliary Surgery, ³Pathology, Affiliated Hospital of Chengde Medical College, Chengde 067000, China

Received December 7, 2015; Accepted February 17, 2016; Epub August 1, 2016; Published August 15, 2016

Abstract: This study is the first to report a case of cellular angiofibroma in the kidney, and based on the relevant literatures, we discuss the pathological features, diagnosis, and differential diagnosis of this disease. The patient (female, 50 years old) was hospitalized with a 1-month dull pain at the right side of the waist. Ultrasound examination showed a tumor (11.7 cm) between the right kidney and the liver, while abdominal computed tomography scanning suggested a soft-tissue mass (11.0 cm) with uneven density and multiple calcifications at the right adrenal gland, indicating a tumor at the right adrenal area. The patient was treated with complete resection of the right kidney. The tumor, located at the upper pole of the right kidney, was enclosed by a smooth envelope and was partly grey-pink and partly yellow-brown. Microscopic observation revealed the following: fusiform-shaped tumor cells, oval or spindle-like nuclei, no nuclear division, small amounts of slightly eosinophilic cytoplasm, evenly distributed blood vessels with hyalinization and fibrosis within the lesion, and an interstitium that was mainly composed of collagen fibers. Immunohistochemistry showed that the cells were positive for vimentin and smooth muscle actin expression. According to the above results, the patient was diagnosed with cellular angiofibroma. Cellular angiofibroma is a benign mesenchymal tumor for which complete resection can be used to achieve a good prognosis. These tumours need to be distinguished from other benign tumours and aggressive tumours occurring in the same site.

Keywords: Cellular angiofibroma, kidney neoplasm, mesenchymal tissue, immunohistochemistry, ultrasound, computed tomography

Introduction

Cellular angiofibroma (CAF) is a rare benign mesenchymal tumor. Nucci et al. [1] first named this disease and reported four cases of CAF in 1997, and then cases were reported worldwide. CAF is commonly seen in female extragenital or male groin and scrotal areas, yet cases of CAF in internal organs are extremely rare: only one patient with CAF in the prostate has been reported to date [2]. This study is the first to report a case of CAF in the kidney, and based on the relevant literatures, we discuss the pathological features, diagnosis, and differential diagnosis of this disease.

Case presentation

Our 50-year-old female patient was hospitalized on March 5, 2013 due to dull pain on the right side of the abdomen. The pain sometimes

radiated to the lower abdomen, but no urinary frequency, urgency, or sepsis was observed and the patient had no history of hypertension, diabetes, surgery, or abdominal trauma. The patient was married and had a son and a daughter, both of whom were alive. A routine examination showed that the patient's heart rate was 78 beats/min and blood pressure was 120/90 mmHg, while an abdominal examination showed no abnormalities, the right kidney could be touched and moved with breathing, and pain was elicited by light percussion at the spinal column and ribs on the right side. Written informed consent was obtained from the patient for publication of this Case report and any accompanying images. A copy of the written consent is available for review by the Editor of this journal.

A laboratory examination showed no abnormal urine, normal liver and kidney function and that

Kidney cellular angiofibroma

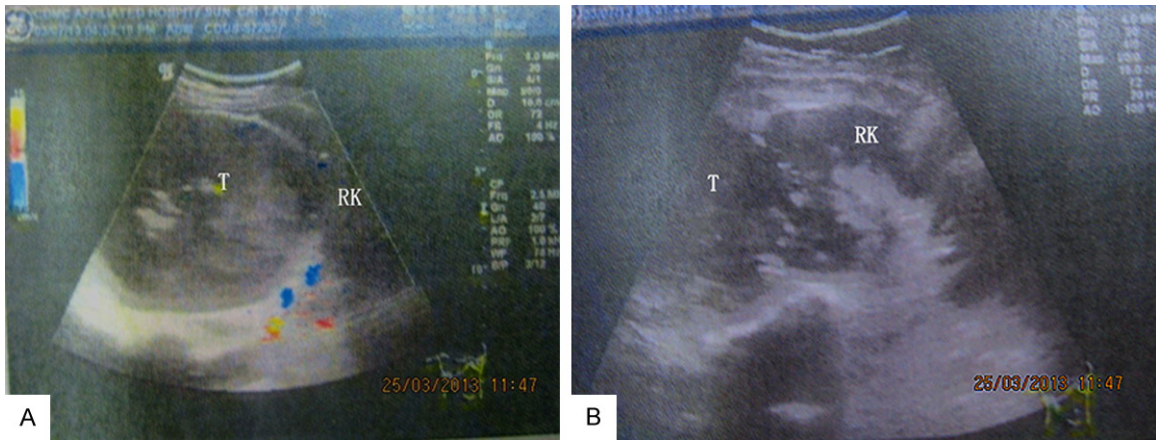


Figure 1. Ultrasonography examination of the right kidney (RK) and the tumor (T). A. Multiple punctate echogenic foci with a rear acoustic shadow are visible at the center of the T; color Doppler flow imaging shows rich color flow signals surrounding the T. B. The relationship between the T and the RK.

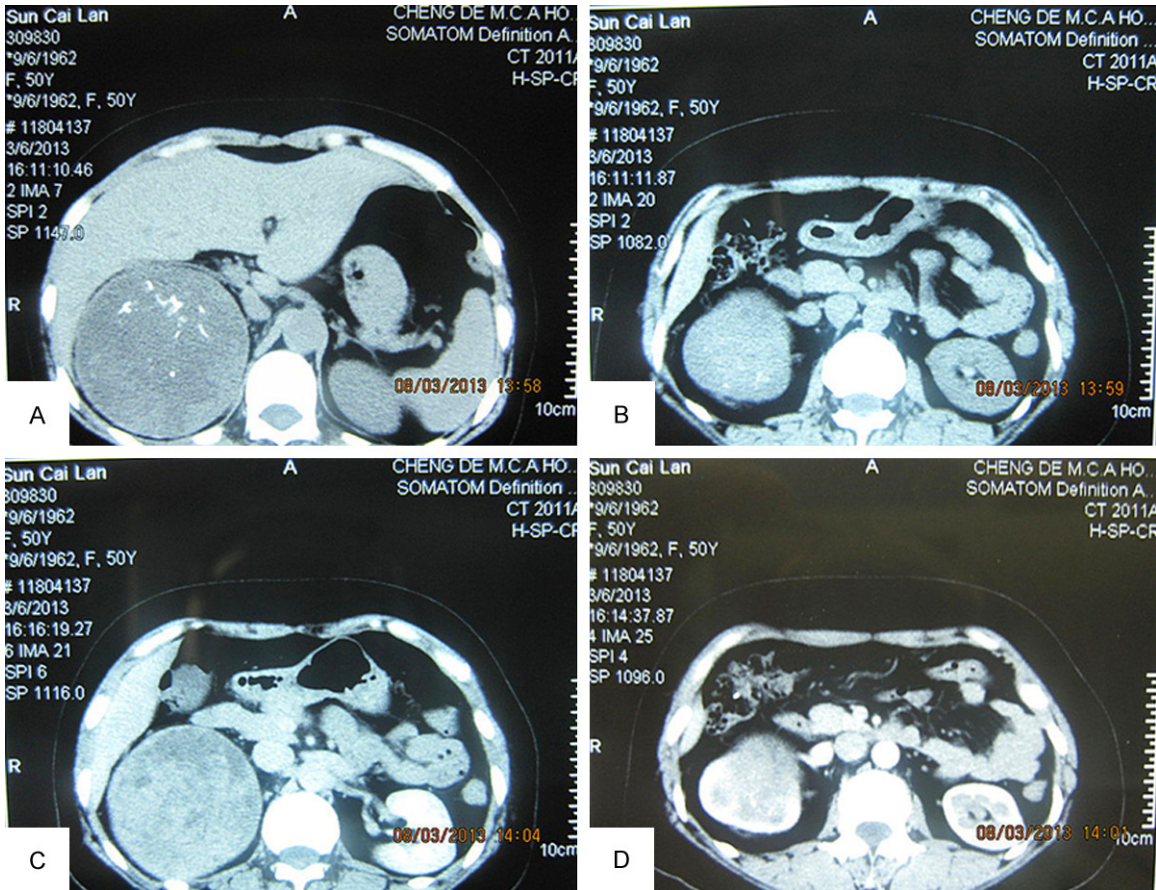


Figure 2. Abdominal computed tomography (CT) scan showing a large soft-tissue mass with uneven density and multiple calcifications in the right adrenal gland area. A and B. Unenhanced CT scan; C and D. Enhanced CT scan.

the concentration of blood leukocytes was 4.9×10^9 cells/L, hemoglobin was 127 g/L, fasting blood glucose was 5.0 mmol/L, blood adreno-

corticotrophic hormone was 22.5 pg/mL (normal reference, 7.2-63.3 pg/mL), plasma cortisol was 112.3 nmol/L (171-546 nmol/L), 24-hour

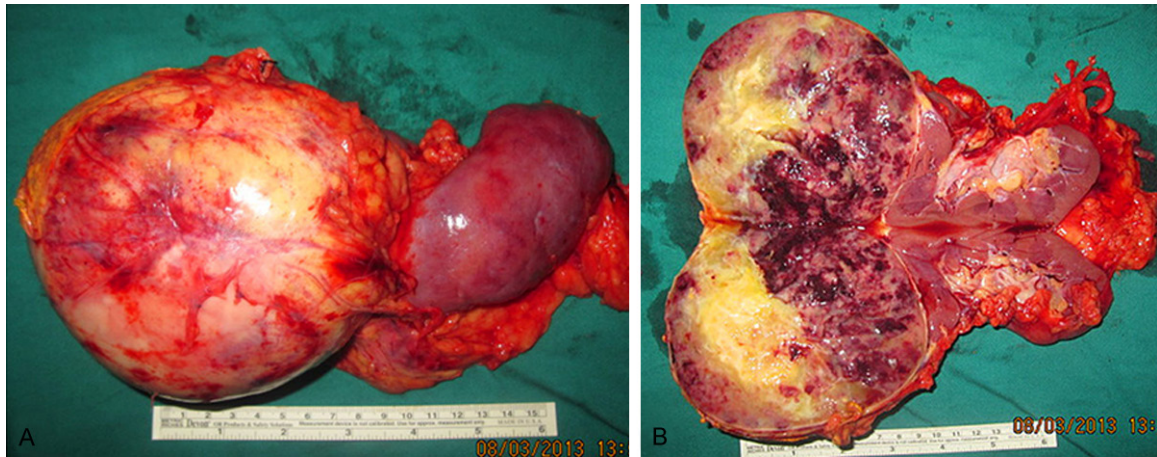


Figure 3. Resected specimen. A. The appearance of the tumor and kidney. B. The tumor was solid, partly grey-pink and partly yellow-brown.

urinary 17-hydroxy steroid was 9.6 $\mu\text{mol/d}$ (8.3-27.7 $\mu\text{mol/d}$) and 17-ketonic steroid was 44.5 $\mu\text{mol/d}$ (35-87 $\mu\text{mol/d}$), VMA was 14.6 $\mu\text{mol/d}$ (1-68.8 $\mu\text{mol/d}$), CA199 was 9.91 U/mL (0-27 U/mL), carcinoembryonic antigen was 0.60 ng/mL (0-5 ng/mL); alpha-fetoprotein was 0.77 ng/mL (0-13.6 ng/mL); and CA125 was 9.03 U/mL (0-35 U/mL).

A chest X-ray suggested normal heart and lung function, while abdominal ultrasonography showed a normal liver, gallbladder, and spleen as well as normal kidney sizes of 10.6 cm \times 6.0 cm \times 6.0 cm (left) and 11.0 cm \times 6.0 cm \times 6.0 cm (right) and demonstrated a hypoechoic mass between the right kidney and the liver with a clear boundary, regular form, and size of 11.6 cm \times 10.5 cm \times 10.7 cm. Multiple punctate echogenic foci were visible inside the mass with a rear acoustic shadow. Color Doppler flow imaging ultrasonography detected rich color flow signals at the tumor periphery (**Figure 1**).

Abdominal CT showed a large soft-tissue mass at the right adrenal gland with a maximum area of 11.0 cm \times 10.0 cm. The mass showed uneven density and multiple calcifications; the right kidney displayed stress-caused changes and heterogeneous enhancement of the mass was observed after enhanced CT scanning; the left kidney appeared normal (**Figure 2**). Considering the lesion at the right adrenal gland, a neoplasm of the right kidney could not be excluded, so the patient underwent complete resection of the right kidney on the third day after admission. Under general anesthesia, an oblique incision was made at the lower edge

of the right upper quadrant and the kidney was resected. Intraoperative observation showed that the tumor was located at the upper pole of the right kidney, was 13 cm \times 10 cm, and had a smooth surface with no significant adhesion with the surrounding tissues. There were no enlarged lymph nodes at the para-aortic areas or tissue surrounding the renal pedicle and no adrenal abnormalities. The tumor was carefully isolated and resected with the kidney. The surgery lasted for 120 min and the blood loss was 100 mL.

After the surgery, the specimen was cut and a solid tumor colored partly grey-pink and partly yellow-brown was observed (**Figure 3**). Microscopic examination showed that the tumor had a clear boundary, the cells were fusiform-shaped, the nuclei were oval or spindle-shaped, no nuclear division was seen, there were small amounts of slightly eosinophilic cytoplasm, and the cell boundaries were not clear. Inside the lesion, small or medium vessels with varying degrees of hyalinization and fibrosis were evenly distributed and the interstitium was composed mainly of collagen fibers and was accompanied by edema and inflammatory cell infiltration. Thus, the patient was diagnosed with CAF (**Figure 4**). Immunohistochemistry showed that the cells were positive for SMA and vimentin but negative for CD34, CD99, Melan A, creatine kinase (CK), CK7, CD10, HMB45, and CgA (**Figure 5**).

The surgery was successful and patient was discharged 9 days later. Follow-up was performed in 3, 12, and 24 months after surgery

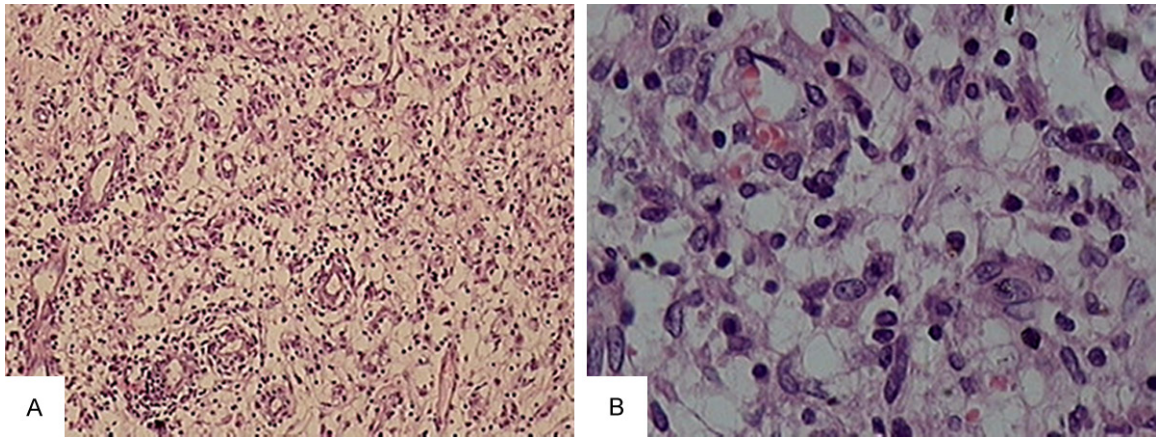


Figure 4. Microscopic examination. The cells were fusiform-shaped, the nuclei were oval or spindle-like, no nuclear division was observed, small amounts of slightly eosinophilic cell cytoplasm were seen, cell boundaries were not clear, small or medium blood vessels were evenly distributed inside the lesion, the vessels showed varying degrees of hyalinization and fibrosis, and the interstitium were mainly composed of thin collagenous fibers and accompanied by edema and inflammatory cell infiltration. Hematoxylin and eosin: $\times 100$ (A); $\times 200$ (B).

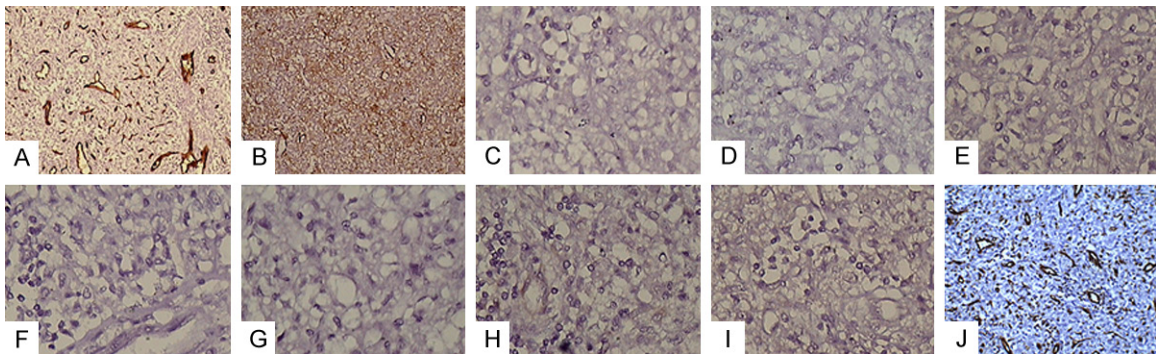


Figure 5. Immunohistochemistry findings. A. CD34 (-); B. Smooth muscle actin (+); C. CD99 (-); D. Melan A (-); E. CK (-); F. CK7 (-); G. CD10 (-); H. HMB45 (-); I. CgA (-); J. Vimentin (+).

(last follow-up on March 20, 2015), while B-ultrasound showed no recurrence in the ipsilateral renal fossa, while the contralateral kidney showed compensatory enlargement but no abnormalities. The patient showed normal serum creatinine and urea nitrogen levels, while a chest X-ray examination revealed no metastasis.

Discussion

Clinical manifestations

CAF is a very rare benign mesenchymal tumor mainly composed of spindle cells and blood vessels. In 1997, Nucci et al. first reported four cases of CAF, all within the extragenital area of middle-aged women. Following that, CAF cases were continuously reported and also found in

the groin or scrotal areas of males. In recent years, CAF has been reported in other superficial regions such as the eyelids, oral mucosa, anus, retroperitoneum, navel, vagina, hymen, elbows, knees, and chest wall subcutaneous tissues as well as in deep tissues such as the retroperitoneum and male pelvis, testis, paratestis, spermatic cord, and prostate [2-13].

A total of 227 results were obtained via a search of the PubMed database (1997 to December 2014) using the keyword cellular angiofibroma, but only 37 studies reported 135 cases of cellular angiofibroma. A search of the Chinese Biomedical Database (to December 2014) obtained 10 studies reporting 10 cases of CAF, but no study reported a case of CAF in the kidney. CAF is more commonly seen in females, as one study reported 25 cases of

CAF, of which 17 were in women and eight were in men; the disease had an early onset of 47 years (27-63 years) in women versus 63 years (32-83 years) in men [5]. However, in the report of Iwasa et al. [4], men and women were affected in equal proportions: of the 51 CAF cases, 25 were in men and 26 were in women, but women still had an earlier onset of a mean 46.0 years versus a mean of 61.3 years in men. The mean size of the CAF tumors in women was smaller than that in men, as the former was 3.4 cm (range, 0.6-12 cm) and the latter was 7.0 cm (3.0-25 cm). Most cases of CAF (70%) occur in female extragenital or male groin and scrotal areas; even if it occurs in other parts, it is likely to be in the pelvis. The clinical symptoms of CAF mainly include subcutaneous painless solid tumors that sometimes cause mild pain or discomfort, and the tumor mainly grow in superficial soft-tissues and be round, oval, strip-shaped or lobular-shaped, show clear boundaries, include or omit a capsule, be soft or tough, and grow very slowly. Patients with tumors in the pelvis or prostate may show urinary obstruction [2, 6], while tumors in the vagina may cause infertility [14].

Diagnosis

Tumors located subcutaneously or at classic sites are easily diagnosed, while those located within the deep tissues are more difficult to diagnose since space-occupying lesions detected by imaging examinations are sometimes caused by other symptoms; thus, the diagnosis of CAF primarily depends on pathological examination. The patient in the case reported here suffered from flank pain. B-ultrasonography showed a solid renal mass and gross observation suggested that the solid tumor was partly colored grey-pink and partly yellow-brown, but the final diagnosis was determined by pathology. Microscopic observation showed the tumor consisted of spindle cells and blood vessels, the cell nuclei were oval or spindle-shaped, there were small amounts of slightly eosinophilic cytoplasm, and the cell boundaries were not clear. Inside the tumor, small or medium blood vessels with varying degrees of hyalinization and fibrosis were evenly distributed, and the interstitium was mainly composed of thin collagen fibers and accompanied by edema and inflammatory cell infiltration. Immunohistochemistry showed that the cells were positive for smooth muscle actin and

vimentin but were negative for CD34, CD99, CK, and HMB45. However, in the Iwasa et al. study, 60% of the 51 cases were positive for CD34 staining [4].

A genetic analysis performed using the fluorescence in situ hybridization technique showed that the CAF tumor had the same RB1 (13q14) deletion with mammary myofibroblastoma and spindle cell lipoma, indicating that these tumors might have similar morphology and were all derived from interstitial fibroblasts. However, the features of CAF include enriched spindle cells, prominent hyalinized vessels, and a small amount of fat tissue, while the other two tumors lack thick-walled blood vessels [5, 15-17].

Differential diagnosis

Since CAF is frequently seen in the vulva, it should be distinguished from other soft-tissue tumors that often occur in this area and also show angiofibroma-like structures such as vascular myofibroblastic tumor, aggressive angio-myxoma, pleomorphic hyalinizing angiectatic tumor, and myxoid leiomyoma, all of which have enriched spindle cells and blood vessels, but the varying morphology, distribution, and arrangement should be used for identification. The tumor in this study occurred in the kidney, so it should be distinguished from the following kidney tumors.

Renal angiomylipoma, which is composed of blood vessels, smooth muscle cells, and adipose tissues in different proportions, is mainly characterized by aggregated and irregularly curved vessels, varying vessel lumen sizes, and uneven vessel wall thickness. Some vessel walls are accompanied by hyalinization, luminal narrowing, and irregular changes; smooth muscle cells are fusiform-shaped, displaying morphology of either interstitial or epithelial cells; show a bundled or woven-like arrangement surrounding the blood vessels or a patchy distribution; and most cells differentiated into mature smooth muscle cells. Immunohistochemistry examination findings suggest that the cells are positive for vimentin, actin, S-100, and HMB45 expression and that HMB45 is the best immunohistochemical marker for a diagnosis of renal angiomylipoma.

Hemangiopericytoma is defined as hemangioma that is derived from pericytes within the vessel. It can occur in any part of the body but

is most frequently seen in the lower extremities and retroperitoneum and rarely in the kidney. Huang et al. [18] searched the PubMed, EMBASE, and Chinese Biomedical Databases (updated to December 2013) and found 51 reported cases. The hemangiopericytoma specimens had thin, complete capsules with a clear boundary. The tumor was yellow-brown colored, fish meat-like in texture, tough, and smooth and showed endogenous growth. Microscopic observation showed that the tumor was composed of oval or spindle-like cells that grow in a multilayered concentric structure surrounding the tumor vessels with an eosinophilic cytoplasm. However, tumor cells vary significantly in size and shape from round to fusiform; tumor vessels are enriched and arranged in a swirl pattern; fusiform-shaped cells with massive eosinophilic cytoplasm are embedded in the myxoid stroma; and nuclear division is not obvious. Immunohistochemistry findings indicate that the cells are positive for vimentin, BCL2, and CD99 but are negative for actin, ethidium monoazide, CD34, S100, cytokeratins, and HMB45.

Inflammatory myofibroblastic tumor (IMT), also called an inflammatory pseudotumor, inflammatory fibrosarcoma, or benign myofibroblastic tumor, is a rare and unique mesenchymal soft-tissue tumor that is mainly composed of differentiated myofibroblastic spindle cells and accompanied by large amounts of plasma cells and lymphocytes. IMT is most commonly seen in the lungs and can be seen in the bladder if it develops within the genitourinary system, but cases of renal IMT are extremely rare. This makes its diagnosis difficult, and most cases are misdiagnosed as renal cancer. IMT is grey-white or yellow-brown and solid, and mucoid degeneration, bleeding, and necrosis can be seen.

Microscopic observation showed that cells are arranged in bundles, the cytoplasm is eosinophilic, the nuclei are oval or spindle-shaped, nuclear division is not significant, cells display local mucosal changes, large megakaryocytes and multinucleated giant cells are scattered and accompanied by neutrophil infiltration, lymphocytes, and plasma cells, some parts of the tumor are enriched with capillaries and small blood vessels, many show crack-like cavities, and fibrosis and hyalinization can be observed. Immunohistochemistry findings indicate that

the cells are positive for SAM and vimentin, are focally positive for S-100 and CD34, and are negative for Ki67, MelanA, and HMB45 [19, 20]. The tumor possesses potential or low malignancy, which increases the risk of tumor recurrence and metastasis; therefore, complete renal resection is the preferred treatment and most patients showed satisfactory prognosis.

Treatment

CAF is a benign tumor. Patients with CAF in the superficial subcutaneous tissues showed good prognosis after complete tumor resection, but local recurrence and neoplasia have been reported in tumors within extragenital areas [5, 21]. The patient in this report did not show recurrence or metastasis after 24 months of follow-up, and the follow-up continues. Kidney-sparing surgery might be the preferred treatment when tumors are diagnosed as benign by pathological examinations and located at the pole of the kidney.

Conclusions

CAF is a benign tumor that is commonly seen in the female extragenital or male groin and scrotal areas but is rarely seen in internal organs and even more rarely seen in the kidney. After complete renal resection, the patient showed good prognosis, but CAF should be distinguished from other benign or malignant tumors that can develop in the same parts or organs.

Disclosure of conflict of interest

None.

Address correspondence to: Dr. Man Yu, Department of Urology, Affiliated Hospital of Chengde Medical College, Chengde 067000, China. Tel: +86-13398692608; Fax: +86-21-64085875; E-mail: yumanok@126.com

References

- [1] Nucci MR, Granter SR and Fletcher CD. Cellular angiofibroma: a benign neoplasm distinct from angiomyofibroblastoma and spindle cell lipoma. *Am J Surg Pathol* 1997; 21: 636-644.
- [2] Wyn I, Debiec-Rychter M, Van Cleynenbreugel B and Sciot R. Cellular angiofibroma of the prostate: a rare tumor in an unusual location. *Case Rep Pathol* 2014; 2014: 871530.

Kidney cellular angiofibroma

- [3] Eversole LR. Cellular angiofibroma of oral mucosa: report of two cases. *Head Neck Pathol* 2009; 3: 136-139.
- [4] Iwasa Y and Fletcher CD. Cellular angiofibroma: clinicopathologic and immunohistochemical analysis of 51 cases. *Am J Surg Pathol* 2004; 28: 1426-1435.
- [5] Flucke U, van Krieken JH and Mentzel T. Cellular angiofibroma: analysis of 25 cases emphasizing its relationship to spindle cell lipoma and mammary-type myofibroblastoma. *Mod Pathol* 2011; 24: 82-89.
- [6] Emtage JB, Parker J, Marcet JE, Finan J, Lockhart JL and Hernandez DJ. A large cellular angiofibroma of the male pelvis presenting with obstructive voiding: A case report and review of the literature. *Can Urol Assoc J* 2013; 7: E373-375.
- [7] Val-Bernal JF, Rubio S, Garijo MF and Gonzalez-Vela MC. Extragenital subcutaneous cellular angiofibroma. Case report. *Apmis* 2007; 115: 254-258.
- [8] Omori Y, Saeki H, Ito K, Umezawa Y, Ishiji T, Ota A, Fukunaga M and Nakagawa H. Extragenital subcutaneous cellular angiofibroma of the elbow. *J Eur Acad Dermatol Venereol* 2014; 28: 828-830.
- [9] Priyadarshi V, Sehgal N, Gupta SK, Kumar V and Singh M. Cellular angiofibroma: two case reports of a rare vulvar tumor. *J Obstet Gynaecol India* 2014; 64: 65-67.
- [10] Micheletti AM, Silva AC, Nascimento AG, Da Silva CS, Murta EF and Adad SJ. Cellular angiofibroma of the vulva: case report with clinicopathological and immunohistochemistry study. *Sao Paulo Med J* 2005; 123: 250-252.
- [11] Kerkuta R, Kennedy CM, Benda JA and Galask RP. Vulvar cellular angiofibroma: a case report. *Am J Obstet Gynecol* 2005; 193: 1750-1752.
- [12] Val-Bernal JF, Azueta A, Parra A, Mediavilla E and Zubillaga S. Paratesticular cellular angiofibroma with atypical (bizarre) cells: case report and literature review. *Pathol Res Pract* 2013; 209: 388-392.
- [13] Chen E and Fletcher CD. Cellular angiofibroma with atypia or sarcomatous transformation: clinicopathologic analysis of 13 cases. *Am J Surg Pathol* 2010; 34: 707-714.
- [14] Bharti JN, Dey B, Raj VG and Arora P. Cellular angiofibroma of vagina presenting with secondary infertility. *J Reprod Infertil* 2014; 15: 165-167.
- [15] Arakaki K, Chinen K, Kamiya M, Tanabe Y, Tawata N, Ikehara F, Uehara K, Shimabukuro H and Kinjo T. Evidence for an association between increased oxidative stress and derangement of FOXO1 signaling in tumorigenesis of a cellular angiofibroma with monoallelic 13q14: a case report. *Int J Clin Exp Pathol* 2014; 7: 8972-8979.
- [16] Magro G, Righi A, Casorzo L, Antonietta T, Salvatorelli L, Kacerovska D, Kazakov D and Michal M. Mammary and vaginal myofibroblastomas are genetically related lesions: fluorescence in situ hybridization analysis shows deletion of 13q14 region. *Hum Pathol* 2012; 43: 1887-1893.
- [17] Maggiani F, Debiec-Rychter M, Vanbockrijck M and Sciort R. Cellular angiofibroma: another mesenchymal tumour with 13q14 involvement, suggesting a link with spindle cell lipoma and (extra)-mammary myofibroblastoma. *Histopathology* 2007; 51: 410-412.
- [18] Huang J, Liao Y and An Y. Renal hemangiopericytoma: A case report. *Chin J Urol* 2014; 35: 959-960.
- [19] Boo YJ, Kim J, Kim JH, Kim CS and Suh SO. Inflammatory myofibroblastic tumor of the kidney in a child: report of a case. *Surg Today* 2006; 36: 710-713.
- [20] Taheri D, Soleimani N, Fesharakizadeh M, Dolatkhah S, Kabiri M and Gholipour A. Inflammatory myofibroblastic tumor: report of a rare case in kidney. *Iran J Kidney Dis* 2014; 8: 333-335.
- [21] McCluggage WG, Perenyi M and Irwin ST. Recurrent cellular angiofibroma of the vulva. *J Clin Pathol* 2002; 55: 477-479.