

Case Report

Bilateral lymph node metastases from primary uterine carcinosarcoma: an immunohistochemical case study

Andrzej Semczuk¹, Dorota Lewkowicz², Maciej Józwiak³, Adam Mrozek⁴, Marek Gogacz¹, Anna Semczuk-Sikora⁵, Tomasz Rechberger¹

¹*Department of Gynecology, Lublin Medical University, Lublin, Poland;* ²*Department of Clinical Pathology, Lublin Medical University, Lublin, Poland;* ³*Department of Gynecology and Gynecologic Oncology, Medical University of Białystok, Białystok, Poland;* ⁴*Department of Obstetrics and Gynecology, Municipal Hospital, Rzeszów, Poland;* ⁵*Department of Obstetrics and Pathology of Pregnancy, Lublin Medical University, Lublin, Poland*

Received March 30, 2016; Accepted June 11, 2016; Epub August 1, 2016; Published August 15, 2016

Abstract: Uterine carcinosarcomas (UCs) are extremely rare but highly malignant neoplasms originating in female genital tract. The 5-year survival of advanced-stage UCs is not satisfactory yet, being below 10%. They metastasize to different organs, most frequently to the lungs (49%), peritoneum (44%), as well as to the pelvic and para-aortic lymph nodes (35%). Herein, we report a case of a 64-year-old woman with a primary UC metastasizing bilaterally to the pelvic lymph nodes. We applied a panel of immunohistochemical markers to assess the staining pattern of the primary tumor and corresponding metastases. In this assessment, the carcinoma component of the UC and lymph node metastases showed similar staining patterns, except for EP4 and p53, being positive in primary tumor and right side metastases. On the other hand, sarcoma component and lymph node metastases showed differences in some of the markers applied. MIB-1 proliferative activity was slightly higher in bilateral pelvic lymph node metastases compared to UC components. Our case report supports the concept of the epithelial component being the driving force for female genital tract UCs as our patient presented a similar staining pattern of carcinomatous component-lymph node metastases in selected markers.

Keywords: Uterine carcinosarcoma, immunohistochemistry, lymph node metastasis, p53

Introduction

Uterine carcinosarcomas (UCs) are extremely rare but highly malignant neoplasms originating in female genital tract [1-3]. They account for less than 5% of all uterine malignancies but their development is associated with >15% of cancer-related deaths [3, 4]. In early clinical stages of the disease (FIGO stages I-II) 5-year survival rates are between 30-46%, whereas the 5-year survival for advanced-stage (FIGO stages III-IV) UCs is unsatisfactory, at only 0-10% [1-4].

In general, UC metastases are related to lymph node positivity, depth of myometrial invasion, cervical tumor extension, lymphovascular space invasion, as well as low degree of differentiation in the carcinomatous component [3]. UCs metastasize to different organs, most frequently to the lungs (49% of cases), peritoneum

(44%), as well as to the pelvic and para-aortic lymph nodes (35%) [1-4]. UCs are biphasic neoplasms and their clinical behavior is strictly connected with the components of the tumor. Molecular as well as immunohistochemical data support the thesis that the carcinoma component is the driving force during the process of tumor dissemination [5-8]. Previously, Sreenan and Hart [5] reported that extrauterine UC metastases are composed of a carcinoma component (70%), while a sarcoma component alone was present in only few cases. Finally, Kanthan and Senger [1] assumed that “the metastatic lesions almost always contain elements of carcinoma with or without a coexisting sarcoma, and solitary sarcomatous metastasis is uncommon”.

We report herein a case of a patient with primary UC metastasizing bilaterally to the pelvic lymph nodes. We briefly discuss the role of UC

Lymph node metastases from uterine carcinosarcoma

Table 1. Immunohistochemical markers in different areas of a primary uterine carcinosarcoma with bilateral pelvic lymph node metastases

Marker	UC		Pelvic lymph node metastases	
	Carcinomatous component	Sarcomatous component	Right side	Left side
Cytokeratin	+	-	+	+
CK AE1/AE3	+	-	+	+
Vimentin	+	+	+	+
Desmin	-	+	-	-
Actin	-	+	-	-
SMA	-	Focal +	-	-
Myo D1	-	Focal +	-	-
Myf 4	-	Focal +	-	-
CD31*	-	-	-	-
CD34*	-	-	-	-
EP4	+	-	+	-
AR	-	-	-	-
PgR	+	-	+	+
ER α	-	-	-	-
CD10	-	-	-	-
CD68	-	-	-	-
Caldesmon	-	-	-	-
S-100	Weak +	-	-	-
Ki-67 (%)	80	60	90	97
p53	+	+	+	-

*Positivity was only reported in blood vessels; AR-androgen receptor, PgR-progesterone receptor, ER α -estrogen receptor α .

components, particularly in the case of lymph node metastases, applying a panel of immunohistochemical markers.

Case report

In March 2015, a 64-year-old Caucasian woman, gravida 2, para 2, was admitted to the IIND Department of Gynecology, Lublin Medical University, Lublin, Poland. She had suffered from abnormal vaginal bleeding for two weeks and a pipella[®] endometrial sampling was performed. The histopathological examination revealed a UC. She had her first menstruation at the age of 14 and subsequent menstrual cycles were normal. She experienced menopause at 55 years. There was no family history of female genital tract malignancies, but her sister suffered from renal cancer. She had not been exposed to exogenous hormones within the last 5 years. Cervical smear performed a year earlier was normal. No abdominal tenderness or rebound tenderness was identified on

physical examination; vital signs and level of consciousness were normal. Pelvic examination disclosed an enlarged uterus with normal ovaries, uterine cervix, and vagina. An ultrasound scan showed endometrial thickness of 27 mm, a uterine polyp of 25 mm, an enlarged uterus measuring 8.0×8.0×4.5 cm with two leiomyomas, and normal-sized ovaries. A complete blood count, urinalysis, serologic tests, electrocardiogram, and chest X-ray were all within normal range. Serum CA125 level was elevated (120 U/mL). A total abdominal hysterectomy with bilateral salpingo-oophorectomy, pelvic lymphadenectomy, omentum sampling and peritoneal washings was carried out during surgery. The tumor was located at the uterine isthmus, infiltrating the endocervix. The peritoneal washings revealed normal cells (lymphocytes, granulocytes, mesothelial cells, and erythrocytes). Histopathological examination of post-surgical material revealed a UC of the heterologous type (rhabdomyosarcoma and chondrosarcoma) with endometrioid endometrial adenocarcinoma, infiltrating less than half the myometrial wall depth but invading the endocervix. The sarcomatous

component was detected both in the endometrial polyp and the uterus, whereas a carcinomatous component was present in the uterus infiltrating the myometrium. Moreover, two uterine leiomyomas of 2.5 cm and 1.0 cm in diameter were confirmed. UC metastases were found to be present in pelvic lymph nodes on both sides and were composed of carcinoma cells. The tumor was concluded to be stage IIIc1 [9]. The postoperative course was uneventful and the patient was discharged on Day 7 postoperatively. She was referred to the Oncology Hospital, Lublin, Poland, where six courses of adjuvant chemotherapy with paclitaxel-carboplatin were administered. Additional imaging studies (ultrasound and positron emission tomography) showed no evidence of recurrence at 10 months postsurgery.

Immunohistochemical assessment of a panel of 20 primary monoclonal antibodies was applied with the REAL[™] EnVision[™]/HRP (DAKO,

Lymph node metastases from uterine carcinosarcoma

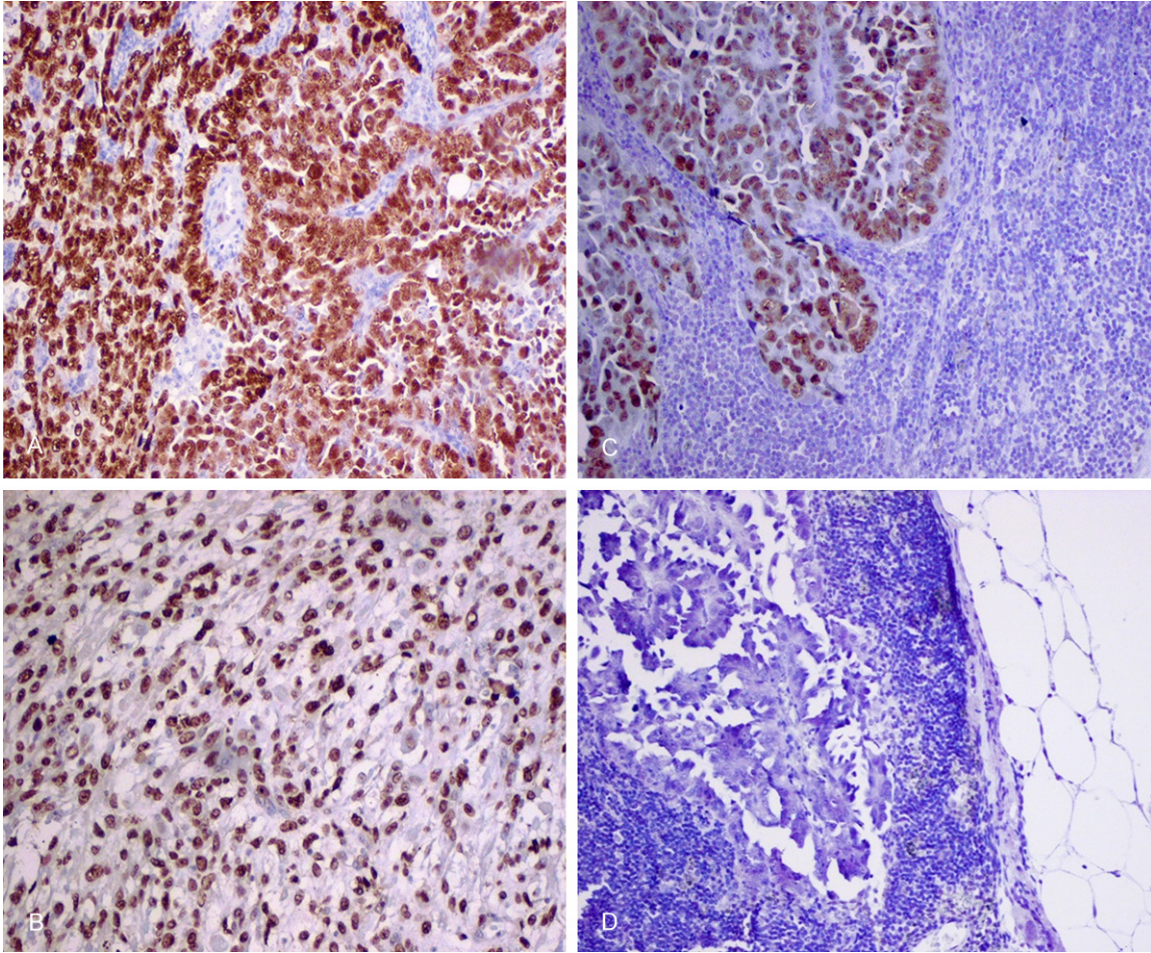


Figure 1. Immunohistochemical staining of p53 in the carcinomatous (A) and sarcomatous (B) components of primary UC, right (C) and left (D) side pelvic lymph node metastases. (Original magnification $\times 200$).

Glostrup, Denmark) method. Antibodies used for independent staining in both CS components and bilateral pelvic lymph node metastases are depicted at **Table 1**. Appropriate positive controls for each staining and negative controls (sections processed without primary antibodies) were applied in each experiment. All staining results were carefully evaluated by a highly-experienced pathologist (D.L.).

Overall, the carcinoma component of the UC and lymph node metastases showed similar staining patterns, except for EP4 and p53, being positive only in right side metastases (**Table 1**). p53 was expressed in both tumor components but, surprisingly, was negative in left side pelvic node metastases (**Figure 1**). On the other hand, sarcoma component and lymph node metastases showed differences in some of the markers applied. For example, sar-

coma component was negative for progesterone receptor expression while the right and left side lymph node metastases were positive. MIB-1 proliferative activity, assessed by PI (Proliferative Index), was slightly higher in bilateral pelvic lymph node metastases compared to UC components (**Table 1**).

Discussion

In our case study, we present a primary UC with bilateral metastases to pelvic lymph nodes and invasion of the endocervix, although tumor infiltration was less than half of the myometrial wall. Consequently, it was staged FIGO IIIC1. Based on a literature review, clinical stage was reported to be the most unfavorable prognostic factor in patients operated on with UCs [10-14]. Moreover, patient's age, depth of myometrial infiltration, and residual tumor were also inde-

pendent prognostic factors [10]. However, it is still unclear whether other prognosticators, for example initial tumor size, lymphovascular space involvement, endometrioid adenocarcinoma as the carcinomatous component, or the lack of a heterologous component in the sarcomatous area, are poor prognostic factors [15]. Callister and co-workers [11] reported that cervical involvement, apart from postmenopausal status, uterine length >10 cm, and peritoneal dissemination, were all unfavorable prognostic factors in multivariate analyses. Data regarding cervical involvement is of utmost importance because even early-stage UC may give extra-uterine spread, remarkably decreasing patient's overall survival [1, 14].

Immunohistochemistry is a valuable diagnostic tool providing important information on markers in tissue sections [16, 17]. Moreover, it can be applied for differentiating a narrow morphologic diagnosis [16]. In primary carcinosarcomas of the female genital tract, the nature and the histogenesis of malignant tumor areas may also be assessed by different immunohistochemical markers [8, 18-22]. Immunostaining for an array of antigens in carcinomatous and sarcomatous areas of primary UC has previously been described by our laboratory [22].

In this study, we reported differences in reactivity of selected markers: Ki-67, p53, EP4, and progesterone receptor, between a primary tumor and paired metastases (**Table 1**). Interestingly, the expression pattern of Ki-67 immunoreactivity was higher in pelvic lymph node metastases compared to both UC components. Data concerning the evaluation of immunohistochemical markers, especially Ki-67, in primary UCs and paired metastases are scarce [8, 22, 23]. In our previous study, only one of 3 tumor-metastasis pairs displayed a significant difference in Ki-67 immunoreactivity, being higher in carcinomatous tissue and ovarian metastasis compared to mesenchymal tumor area [22]. A similar Ki-67 expression pattern in primary tumors and corresponding metastases was published by Swisher et al. [23]. Surprisingly, in a case of UC recurrence, MIB-1 expression was lower (2+) compared to primary tumor (4+) and corresponding metastasis (4+) [23].

Data published by Klein and co-investigators [24] suggested a high heterogeneity of early disseminated cells in minimal residual cancer. Although the heterogeneity of primary tumor

cells has been known for a long time [25, 26], "clinically evident metastasis is apparently preceded by a genetic diversification present in early-disseminated tumour cells, from which certain, more aggressive, and 'fitter' genotypes are selected" [24]. For these reasons, apparently different tumor genotypes may be responsible for the variations of immunohistochemical patterns between paired primary and metastatic tumors. Furthermore, the immunohistochemical staining differences between paired primary tumor and metastases may also be associated with more aggressive biological behavior of the carcinomatous component than the sarcomatous. Our case report supports the concept of the epithelial component being the driving force for female genital tract carcinosarcomas as our patient presented a similar staining pattern of carcinomatous component-lymph node metastases in selected markers.

Acknowledgements

We would like to thank Mrs Mariola Bigas and Mrs Maria Nowak for their immunostaining analysis and Mr Robert Klepacz for his expertise in high-quality photographs. Our study was supported by a grant from the Lublin Medical University, Lublin, Poland (Dz. St. 326/16 to A.S.).

Disclosure of conflict of interest

None.

Address correspondence to: Dr. Andrzej Semczuk, IIND Department of Gynecology, Lublin Medical University, 8 Jaczewski Street, Lublin 20-954, Poland. Tel: +48 81 7244268; Fax: +48 81 7244849; E-mail: andrzej.semczuk@am.lublin.pl

References

- [1] Kanthan R and Senger JL. Uterine carcinosarcoma (Malignant Mixed Mullerian Tumours): A review with special emphasis on the controversies in management. *Obstet Gynecol Int* 2011; 2011: 470795.
- [2] Singh R. Review literature on uterine carcinosarcoma. *J Cancer Res Ther* 2014; 10: 461-468.
- [3] Cantrell LA, Blank SV and Duska LR. Uterine carcinosarcoma: A review of the literature. *Gynecol Oncol* 2015; 137: 581-588.
- [4] El-Nashar SA and Mariani A. Uterine carcinosarcoma. *Clin Obstet Gynecol* 2011; 54: 292-304.

Lymph node metastases from uterine carcinosarcoma

- [5] Sreenan JJ and Hart WR. Carcinosarcomas of the female genital tract. A pathologic study of 29 metastatic tumors: further evidence for the dominant role of the epithelial component and the conversion theory of histogenesis. *Am J Surg Pathol* 1995; 19: 666-674.
- [6] Costa MJ and Guinee D Jr. CD34 immunohistochemistry in female genital tract carcinosarcoma (malignant mixed mullerian tumors) supports a dominant role of the carcinomatous component. *Appl Immunohistochem Mol Morphol* 2000; 8: 293-299.
- [7] McCluggage WG. Uterine carcinosarcomas (malignant mixed Mullerian tumors) are metaplastic carcinomas. *Int J Gynecol Cancer* 2002; 12: 687-690.
- [8] de Jong RA, Nijman HW, Wijbrandi TF, Reyners AKL, Boezen HM and Hollema H. Molecular markers and clinical behavior of uterine carcinosarcomas: focus on the epithelial tumor component. *Mod Pathol* 2011; 24: 1368-1379.
- [9] Pecorelli S. Revised FIGO staging for carcinoma of the vulva, cervix, and endometrium. *Int J Gynaecol Obstet* 2009; 105: 103-104.
- [10] Inthasom P, Carter J, Valmadre S, Beale P, Russell P and Dulrymple C. Analysis of clinicopathologic factors in malignant mixed Mullerian tumors of the uterine corpus. *Int J Gynecol Cancer* 2002; 12: 348-353.
- [11] Callister M, Ranondetta LM, Jhingran A, Burke TW and Eifel PJ. Malignant mixed Mullerian tumors of the uterus: analysis of patterns of failure, prognostic factors, and treatment outcome. *Int J Radiat Oncol Biol Phys* 2004; 58: 786-796.
- [12] Amand F, Cardon I, Fuso L, Berteloot P, de Jonge E, Jacomen G, Van Robaeys J, Neven P, Moerman P and Vergote I. Endometrial carcinosarcomas have a different prognosis and pattern of spread compared to high-risk epithelial endometrial cancer. *Gynecol Oncol* 2005; 98: 274-280.
- [13] D'Angelo E and Prat J. Pathology of mixed Mullerian tumours. *Best Pract Res Clin Obstet Gynaecol* 2011; 25: 705-718.
- [14] Arend R, Doneza JA and Wright JD. Uterine carcinosarcoma. *Curr Opin Oncol* 2011; 23: 531-536.
- [15] Iwasa Y, Haga H, Konishi I, Kobayashi Y, Higuchi K, Katsuyama E, Minamiguchi S and Yamabe H. Prognostic factors in uterine carcinosarcoma: a clinicopathologic study of 25 patients. *Cancer* 1998; 82: 512-519.
- [16] Hayat MA. Microscopy, immunohistochemistry, and antigen retrieval methods. For light and electron microscopy. Kluwer Academic/Plenum Publishers, New York, Boston, Dordrecht, London, Moscow, 2002.
- [17] Mittal K, Soslow R and McCluggage WG. Application of immunohistochemistry in gynecologic pathology. *Arch Pathol Lab Med* 2008; 132: 402-423.
- [18] Guarino M, Giordano F, Pallotti F, Polizzotti G, Tricomi P and Cristofori E. Malignant mixed mullerian tumor of the uterus. Features favoring its origin from a common cell clone and an epithelial-to-mesenchymal transformation mechanism of histogenesis. *Tumori* 1998; 84: 391-397.
- [19] Watanabe M, Shimizu K, Kato H, Imai H, Nakano H, Sugawa M and Shiraishi T. Carcinosarcoma of the uterus: immunohistochemical and genetic analysis of clonality of one case. *Gynecol Oncol* 2001; 82: 563-567.
- [20] Semczuk A, Skomra D, Chyżyńska M, Szewczuk W, Olcha P and Korobowicz E. Immunohistochemical analysis of carcinomatous and sarcomatous components in the uterine carcinosarcoma: A case report. *Pathol Res Pract* 2008; 204: 203-207.
- [21] Semczuk A, Colas E, Walczyna B, Jóźwik M, Pyra A, Semczuk-Sikora A and Rechberger T. Coexistence of homologous-type cervical carcinosarcoma with endometrioid-type G1 endometrial cancer: a case report with an immunohistochemical study. *Int J Clin Exp Pathol* 2014; 7: 7191-7195.
- [22] Bałon B, Kaznowska E, Ignatov A, Steć A, Semczuk-Sikora A, Schneider-Stock R, Jóźwik M, Sulkowski S, Cybulski M, Szumiło J and Semczuk A. p53 is not related to Ki-67 immunostaining in the epithelial and mesenchymal components of female genital tract carcinosarcomas. *Oncol Rep* 2013; 30: 1661-1668.
- [23] Swisher EM, Gown AM, Skelly M, Ek M, Tamimi HK, Cain JM, Greer BE, Muntz HG and Goff BA. The expression of epidermal growth factor receptor, HER-2/*neu*, p53, and Ki-67 antigen in uterine malignant mixed mesodermal tumors and adenosarcoma. *Gynecol Oncol* 1996; 60: 81-88.
- [24] Klein CA, Blankenstein TJF, Schmidt-Kittler O, Petronio M, Polzer B, Stoecklein NH and Riethmuller G. Genetic heterogeneity of single disseminated tumour cells in minimal residual cancer. *Lancet* 2002; 360: 683-689.
- [25] Fujii H, Marsh C, Cairns P, Sidransky D and Gabrielson E. Genetic divergence in the clonal evolution of breast cancer. *Cancer Res* 1996; 56: 1493-1497.
- [26] Macintosh CA, Stower M, Reid N and Maitland NJ. Precise microdissection of human prostate cancers reveals genotypic heterogeneity. *Cancer Res* 1998; 58: 23-28.