

Original Article

Simultaneous bilateral retroperitoneal laparoscopic nephron sparing surgery: a case report and evaluation of the technique

Qingfei Cao, Ming Tong

Department of Urinary Surgery, The First Affiliated Hospital of Liaoning Medical College, Jinzhou 121001, China

Received December 19, 2015; Accepted July 25, 2016; Epub August 1, 2016; Published August 15, 2016

Abstract: Bilateral renal cell carcinoma (RCC) is an extremely rare renal tumor, which even more infrequently presents with two different types of pathology. We present a case of bilateral RCC in a 56-year-old male patient treated with simultaneous retroperitoneal laparoscopic nephron-sparing surgery (RLNSS). The postoperative histopathologic examination identified the left tumor as a clear cell carcinoma and the right as a chromophobe cell carcinoma. The patient received no adjuvant therapy and was alive at the 15-month follow-up examination. As far as we are aware, it is the first case of bilateral RCC of different pathologic types in the two tumors that was treated with simultaneous RLNSS. This technique can be extended due to the benefits of the short postoperative recovery period and wide acceptance among patients.

Keywords: Renal cell carcinoma, retroperitoneal laparoscopic nephron-sparing surgery, simultaneous bilateral

Introduction

Bilateral renal cell carcinoma (RCC) is an extremely rare renal tumor, accounting for 3-4% of sporadic RCC [1]. Bilateral and multifocal RCC are usually of a single histological type and infrequently of different types [2, 3].

Currently, nephron-sparing surgery (NSS) has become the standard for treating bilateral RCC, even for tumors greater than 4 cm [4-6]. Laparoscopic NSS has developed as a minimally invasive procedure and novel technique for the treatment of RCC. However, few papers have been published regarding simultaneous bilateral RCC with laparoscopic nephron-sparing surgery, especially few reporting the retroperitoneal laparoscopic technique.

To our knowledge, this is the first case to date of bilateral RCC treated with simultaneous retroperitoneal laparoscopic nephron-sparing surgery (RLNSS). Here we indicate the feasibility of this management and discuss the advantages and disadvantages of this technique.

Case report

A 56-year-old male patient presented with a 3-month history of continuous bilateral lower

back pain, and he was otherwise without remarkable past medical history. On admission, his physical examination was completely normal and his renal function was within normal limits. Preoperative computed tomography (CT) scans of the abdomen with contrast enhancement identified a 2.0 cm tumor in the upper pole of the left kidney and a 4.0 cm tumor on the central ventral surface of the right kidney (**Figure 1**). The two masses were suspicious for malignancy, though the possibility of benign tumors or renal cysts were also considered.

The technique of RLNSS was performed in the right lateral decubitus position, starting from left side. The surgical technique for treating renal tumors has been described previously [7]. After creating the left retroperitoneal cavity from the tip of the twelfth rib, a 12-mm port was introduced. Subsequently, a 10-mm trocar was introduced below the eleventh rib edge for a camera, and an additional a 5-mm assistant port was placed on the top of the iliac crest. The paranephric fat was dissected off Gerota's fascia, which was subsequently incised away from the kidney to extensively mobilize the kidney, easily achieving access to the mass from all sides. The renal artery was dissected free cautiously and then clamped with a laparoscopic

Simultaneous bilateral RLNSS

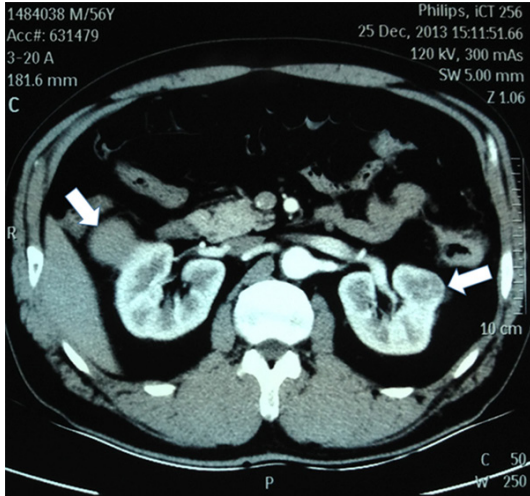


Figure 1. Preoperative CT scans of the abdomen with contrast enhancement. Bilateral renal masses localized to the kidney surface are shown.

bulldog clamp. After the renal artery was temporarily occluded, the tumor was removed with a 1-mm margin of normal kidney tissue using the cold scissors. Subsequently, the defect of the kidney parenchyma was closed with 2-0 Monocryl continuous sutures. The bulldog clamp was subsequently removed, and the warm ischemia time for the left kidney was 18 minutes. After the mass was retrieved with an endocatch bag, a suction drain was placed in the retroperitoneal cavity from the camera port. All trocars were removed, and the port site skin edges were closed using 4-0 Monocryl.

Without interrupting the anesthesia, the patient was moved to the left lateral decubitus position after a 180 degree rotation. The second RLNPS was then performed on the right side kidney following the above technique. The warm ischemia time for the right kidney was 25 minutes.

The total operation time was 235 minutes, and the console time was only 180 minutes. The intraoperative blood loss was approximately 100 cc, and the postoperative renal function was within normal limits. The patient had an uneventful postoperative recovery. The urethral catheter and both retroperitoneal suction drains were removed on postoperative day 3, after which the patient was discharged. The postoperative pathological examination identified bilateral RCC with negative margins. The left-side tumor was diagnosed as clear cell carcinoma (**Figure 2A**) and the right as chromophobe cell carcinoma (**Figure 2B**).

The patient was alive at the 15-month follow-up examination, and the CT scans of the abdomen with contrast enhancement did not indicate any tumor recurrence or metastasis (**Figure 3**).

Discussion

The retroperitoneal laparoscopic approach for renal masses is becoming increasingly common due to similar perioperative results and survival rates compared with the traditional open technique [8]. Very few papers have been published regarding simultaneous bilateral RCC with retroperitoneal laparoscopic nephron-sparing surgery (RLNSS) because of the low incidence of bilateral masses. The advantages of simultaneous operations are shorter hospitalization, faster recovery and lower costs compared with two separate procedures. At the same time, Blute reported that simultaneous bilateral surgery compared with staged procedures results in a similar risk of recurrence, metastasis and postoperative complications [9]. Consequently, we consider that the RLNSS technique is worthy of consideration for bilateral renal masses in some cases.

The retroperitoneal laparoscopic technique, which is performed to provide more direct contact with the kidney and renal pedicle, helps to avoid bowel mobilization [10]. With this approach, renal masses must be sharply resected in a nearly bloodless field prior to removing the bulldog clamp, and adequate margins of normal renal tissue (at least 0.1 cm) must be reserved.

The total operation time was less than 4 hours, including anesthesiology procedures, patient positioning and trocar placement. The warm ischemia times were only 18 minutes (left kidney) and 25 minutes (right kidney). Therefore, this technique can decrease the risk of postoperative renal insufficiency. The simultaneous RLNSS procedure was truly cost effective. In this case, two partial nephrectomies were performed with the same surgical instruments, and the costs of the surgeries were greatly decreased.

This paper has several limitations, including a low number of cases and limited follow-up. For these reasons, the simultaneous RLNSS procedure remains a controversial potential treatment for bilateral RCC.

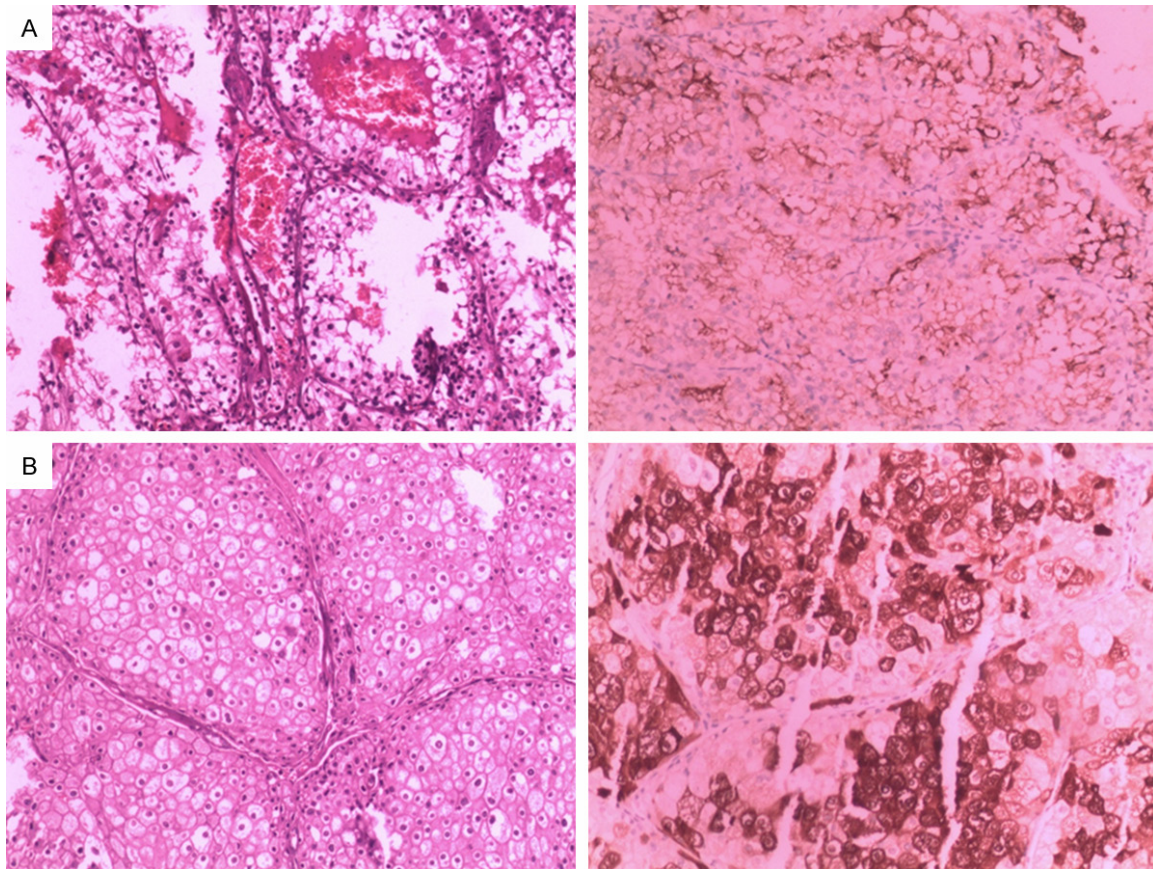


Figure 2. Histology of the renal masses. A. The HE (left) and Immunohistochemical (right) staining of CD10 all indicate that the left kidney tumor is the typical pathologic appearance of clear cell carcinoma. B. The HE (left) and Immunohistochemical (right) staining of CD10 all indicate that the right kidney tumor is the typical pathologic appearance of chromophobe cell carcinoma.

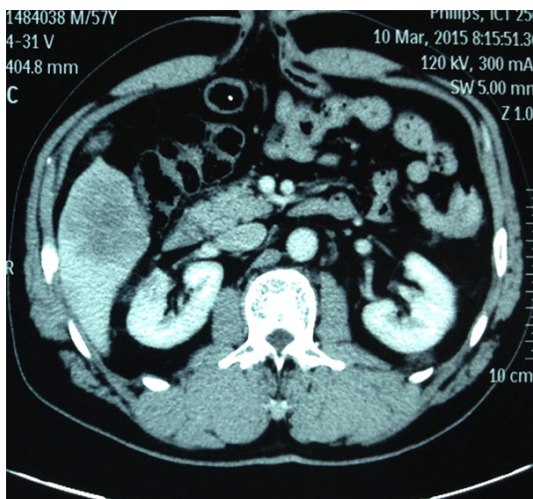


Figure 3. Postoperative CT scans of the abdomen with contrast enhancement after 15 months. The CT of the abdomen does not indicate any tumor recurrence or metastasis.

In summary, our experience was encouraging and indicated the feasibility and safety of the simultaneous RLNSS procedure. Furthermore, this technique was cost- and time-effective with a quick recovery for the patient. Although the simultaneous RLNSS procedure is not the standard treatment for bilateral RCC, we recommend that it should be considered as a potential standard treatment for bilateral RCC due to its excellent perioperative and postoperative outcomes.

Disclosure of conflict of interest

None.

Address correspondence to: Dr. Ming Tong, Department of Urinary Surgery, The First Affiliated Hospital of Liaoning Medical College, No. 2 Sec.5, Renmin Road, Guta District, Jinzhou 121001, Liaoning Province, China. E-mail: caoqingfei15914@163.com

Simultaneous bilateral RLNSS

References

- [1] Woodson B, Fernandez R, Stewart C, Mandava S, Wang L and Lee BR. Bilateral synchronous sporadic renal masses: intermediate functional and oncological outcomes at a single institution. *Int Urol Nephrol* 2013; 45: 619-625.
- [2] Richstone L, Scherr DS, Reuter VR, Snyder ME, Rabbani F, Kattan MW and Russo P. Multifocal renal cortical tumors: frequency, associated clinicopathological features and impact on survival. *J Urol* 2004; 171: 615-620.
- [3] Ustuner M, Yaprak B, Teke K, Ciftci S, Kart M, Yildiz K and Culha M. Coexisting papillary and clear renal cell carcinoma in the same kidney. *Case Rep Urol* 2014; 2014: 575181.
- [4] Roos FC, Brenner W, Muller M, Schubert C, Jager WJ, Thuroff JW and Hampel C. Oncologic long-term outcome of elective nephron-sparing surgery versus radical nephrectomy in patients with renal cell carcinoma stage pT1b or greater in a matched-pair cohort. *Urology* 2011; 77: 803-808.
- [5] Becker F, Siemer S, Humke U, Hack M, Ziegler M and Stockle M. Elective nephron sparing surgery should become standard treatment for small unilateral renal cell carcinoma: Long-term survival data of 216 patients. *Eur Urol* 2006; 49: 308-313.
- [6] Gill IS, Kavoussi LR, Lane BR, Blute ML, Babineau D, Colombo JR Jr, Frank I, Permpongkosol S, Weight CJ, Kaouk JH, Kattan MW and Novick AC. Comparison of 1,800 laparoscopic and open partial nephrectomies for single renal tumors. *J Urol* 2007; 178: 41-46.
- [7] Xu B, Zhang Q and Jin J. Hypertension secondary to reninoma treated with laparoscopic nephron-sparing surgery in a child. *Urol* 2012; 80: 210-213.
- [8] Xu B, Zhao Q, Jin J, He ZS, Zhou LQ and Zhang Q. Laparoscopic versus open surgery for renal masses with infrahepatic tumor thrombus: the largest series of retroperitoneal experience from China. *J Endourol* 2014; 28: 201-207.
- [9] Blute ML, Itano NB, Cheville JC, Weaver AL, Lohse CM and Zincke H. The effect of bilaterality, pathological features and surgical outcome in nonhereditary renal cell carcinoma. *J Urol* 2003; 169: 1276-1281.
- [10] Wright JL and Porter JR. Laparoscopic partial nephrectomy: comparison of transperitoneal and retroperitoneal approaches. *J Urol* 2005; 174: 841-845.